

# Heterotopy of thyroid tissue – A modified therapeutical approach

---

Jaromír Astl,<sup>1</sup> Jan Betka<sup>1</sup> & Petr Vlcek<sup>2</sup>

1. Department of Otolaryngology and Head and Neck Surgery, Medical Faculty, Charles University, Prague, Faculty Hospital Motol and Chair of otorinolaryngology, Institute of Postgraduate Studies, Prague, Czech Republic.
2. Department of Nuclear Medicine, Medical Faculty of Charles University of Prague, Faculty Hospital Motol, Prague, Czech Republic.

*Correspondence to:* Jaromír Astl, M.D., PhD.  
Department of Otolaryngology and Head and Neck Surgery, Faculty  
Hospital Motol, V Úvalu 84, 150 00 Prague 5, Czech Republic.  
TEL +41 02-24434311  
FAX +41 02-14434319

*Submitted:* May 20, 2001  
*Accepted:* July 21, 2001

---

Neuroendocrinology Letters 2001; 22:263–269 pii: NEL220401C03 Copyright © Neuroendocrinology Letters 2001

## Abstract

**OBJECTIVES:** The authors describe the classification of heterotopic thyroid tissue. A survey of more than 600 literature cases is provided. Different therapy approaches for these anomalies are discussed. Data from seven subsequent cases have been added to the existing literature data. The authors present an alternative approach to the therapy of heterotopic thyroid tissue. **MATERIALS AND METHODS:** The records of seven patients treated for a heterotopy of the thyroid tissue at the Department of ENT and Head and Neck Surgery of First Medical school of the Charles University of Prague since 1.1.1991 to 1.1.2001 have been analyzed.

**RESULTS:** *The first group: No surgery.* This approach was used for children. In these patients the heterotopic thyroid tissue is the only thyroid tissue they have, but it's function is not damaged and there are no mechanical symptoms (no airway obstruction and dysphagia). TSH substitution-suppression therapy is necessary for this group. Co-operation and follow up by the endocrinology, otolaryngology and pediatric departments is necessary. At a later age these patients can be treated as in the second group.

*The second group: Surgery.* All patients in this group had heterotopic thyroid tissue. The total removal of thyroid tissue has been preferred. Carcinomatous change or the development of mechanical syndrome, dysphagia or airway obstruction is possible. Total removal is the best surgical approach. Various surgical methods are described in the literature (CO<sub>2</sub> laser, intra-oral, mandibulotomy, middle hyotomy etc.). These patients are treated as after total thyroidectomy and substitution therapy with synthetic thyroid hormones is necessary. The authors describe and add seven cases to the literature data. The authors describe radical removal of aberrant and accessory tissue.

## Introduction

Heterotopies of thyroid tissue are rare. Wertz [1] writes: “No institution, nor any physician has had the opportunity to manage the care of more than two or three of these unusual anomalies, however, a review of the experience to date may give some insight into improved care of future cases.” Wertz’s paper summarised 400 reported cases.

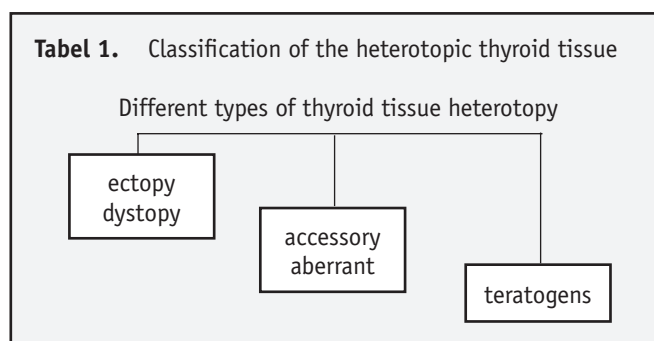
The foetal primordia of the thyroid gland develop as a downward-oriented growth from the floor of the primitive pharynx in the 3rd week of foetal life. Initially, they grow anteriorly to the midline and then extend downward as a long tube: the thyreoglossal duct. In the region of hyoid bone they divide into two parts – the bases of lobes of thyroid gland lobes. The descent reaches its final position in front of the trachea and thyroid cartilage. These steps are usually completed by the 10th foetal week.

The heterotopic thyroid tissues are mostly quantitatively deficient, but they may be the only functioning thyroid tissues available. Functioning at marginal levels, they should be subjective to excessive thyroid stimulating hormone (TSH) stimulation, with resulting hyperplasia, i.e. a compensatory enlargement. This is the source of the first symptoms. Their presence is age dependent.

Accurate diagnosis is the precondition of a good therapy, together with the knowledge of the types of heterotopic thyroid tissue. Detailed endocrinological and otolaryngological examination is also necessary. Only then is it possible to determine the therapy course. The carcinomatous change of this heterotopic tissue was reported [2, 3, 4, 5, 6, 7, 8, 9]. Surgical removal of heterotopic thyroid tissue was described in literature [10, 11, 12, 13, 14, 15, 16, 17, 18], and certain other approaches were reported as well [19]. A different approach to therapy in children was discussed.

## Classification of abnormal developments

The classification of maldescending thyroid tissues varies and is described nonsystematically. We prefer the following classification (Tabel 1).



Any abnormalities of normal descent of the thyroid tissue may result in the heterotopy of thyroid tissue in the midline.

The most frequent abnormal development of the thyroid is the formation of a persistent duct (thyreoglossal duct) or cyst with residual cells (accessory thyroid cells or tissue).

**Group I.** Any arrest of the descent is present as lingual, sub-lingual or subhyoid heterotopy (ECTOPY) of thyroid tissue.

Simultaneous descent with the foetal basis of heart results in intrathoracic or primary retrosternal goitre (DYSTOPY).

**Group II.** Firstly, it needs to be determined whether there is a metastasis of differentiated carcinomas, or accessory or aberrant thyroid tissue.

The descent outside the midline results in the lateral ABERRANT thyroid tissue. The combination of the thyroid tissue developing in the midline with the thyroid tissue coexisting in the physiological region is possible (ACCESSORY thyroid tissue).

The combination of the thyroid tissue developing in lateral region with the thyroid tissue coexisting in the physiological region is possible in the form of aberrant accessory thyroid tissue.

**Group III.** We added the aplastic cases to the developmental anomalies [20, 21, 22].

“Struma ovarialis” or abdominal thyroid tissue was described in the literature [23, 24]. We added these cases into the group of teratogenic development.

## Investigation schemes of heterotopic thyroid tissue

The symptoms of this heterotopic tissue are different. The functional pathology appears in higher age. The first symptoms mostly appear as cosmetic problems, or airways obstruction, swallowing problems and speech problems. These symptoms depend on localisation of the tissue.

### Otolaryngological investigation

Otolaryngological investigation shows where the resistance is localised (midline, subhyoid, lingual, lateral neck region etc.), the character of this resistance (cysts, solid tissue), and the type of functional damage. Indirect laryngoscopy is necessary. Audiological investigation of these cases may indicate that these anomalies may be associated with hearing loss.

Differential diagnosis of other tumorous diseases is necessary (cysts, carcinoma, myoma, fibroma, lymphosarcoma, lymphangioma, angioma, amyloidosis, angioma, hyperplasia of lymphonodous tissue, gumma, lymphoma).

### Endocrinological investigation

Endocrinological investigation determines the levels of thyroid hormones and of the functional state of thyroid tissue. The endocrinologist has a fundamental influence on therapeutic schemes. The possible surgical removal of these tissues is indicated by the endocrinologist and by the surgeon, and this mutual cooperation is necessary.

### Ultrasonography

Ultrasonography is necessary for differential diagnosis of accessory, aberrant or ectopy (dystopy) thyroid tissue. Ultrasonography also helps to distinguish other tumorous diseases and tissues. We use the guide FNAB whenever it is possible, since it (G-FNAB) may provide better information than a simple FNAB.

### FNAB – fine needle aspiration biopsy

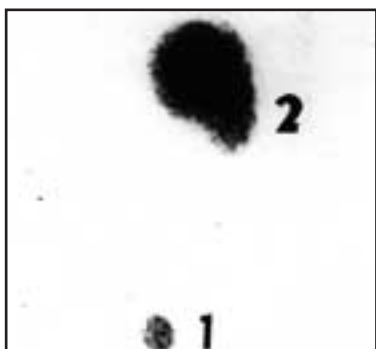
FNAB is necessary, since cytology provides a differential diagnosis between malignant, benign and suspected tumours, and between cysts a solid tissue. FNAB is also a necessary tool of the differential diagnosis between thyroid tissue and other tumorous tissue.

### Scintigraphy

Scintigraphy is the differential diagnostic investigation tool for heterotopic tissue. If the differential diagnosis of heterotopic tissue is not possible, the accessory or aberrant thyroid tissue might be non-accumulating. Scintigraphy with radioiodine isotopes ( $I^{123}$ ,  $I^{131}$ ) is preferable as it's selectivity is higher than that of other radioisotopes (Fig. 1).

### Computer tomography (CT), magnetic resonance imaging (MRI)

CT scans and MRI investigation are not necessary, but in most cases they are still added to the investigation schemes. These methods inform about the localisation of the tissue, it's structure and it's relation-



**Fig. 1.** Scintigraphy of the neck (radioiodine)  
No.1 – the residual tissue after thyroidectomy.  
No.2 – the accessory thyroid tissue near to hyoid bone.

ship with respect to other organs and structures in the region of presence. (Fig. 2).

### X-ray imaging

This method is rarely used. The angiography highlights the arterial supply. X-ray of base of tongue is used extremely rarely to verify the location in the neck and the nature of airways obstruction. (Fig. 3).

The investigation results are analysed and the type of heterotopy is determined.

### Management of heterotopy of thyroid tissue

We prefer the following approaches to heterotopy of thyroid tissues.

#### *The first group: No surgery.*

This group is represented by children. In these patients the heterotopic thyroid tissue is the only thyroid tissue, but it's functions are not damaged and there are no mechanical symptoms (no airway obstruction and/or dysphagia). The substitution-suppression therapy is the method of choice for this group. The cooperation of the endocrinologist, the otolaryngologist and of the paediatric department is necessary.

After the childhood period is over these patients can be treated in the same way as the second group.

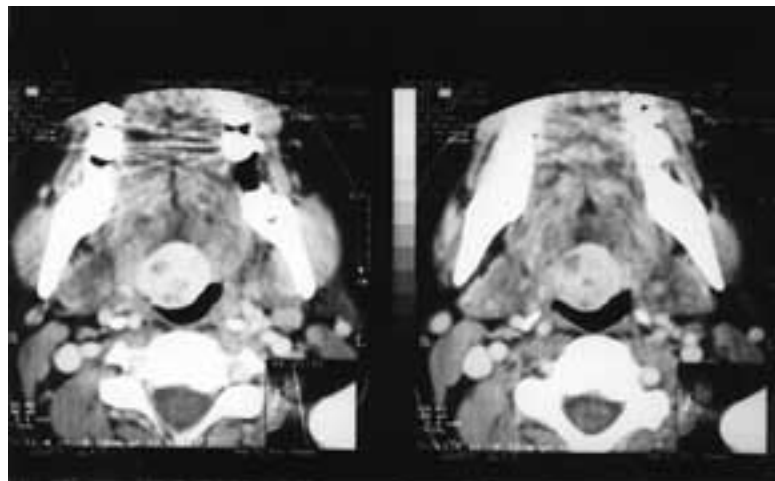
#### *The second group: Surgery.*

All patients in this group show heterotopy of thyroid tissue. The total removal of thyroid tissue is preferred. There can be carcinomatous changes or development of mechanical syndromes, dysphagia or airway obstruction.

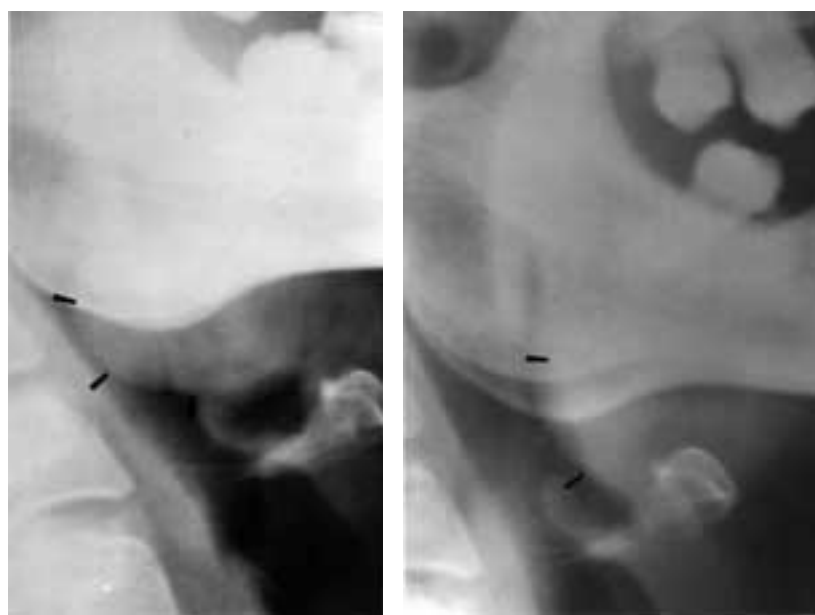
Total removal is then the best type of surgery. These patients are the same as those after the total thyroidectomy and the regime or thyroid hormone substitution therapy is used. This approach is better, since the dangers of complication from subtotal removal or transplantations of this tissue are higher.

### **Materials and methods**

The records of seven patients treated for a heterotopy of the thyroid tissue at the Department of ENT and Head and Neck Surgery of First Medical school of the Charles University of Prague since 1.1.1991 to 1.1.2001 have been analysed. We searched for history of thyroid diseases, age and diagnoses and treat factors. Pretreatment evaluation consisted of the clinical investigation, ultrasonography, computed scans and fine needle aspiration biopsy and included the, ray, imaging when is necessary. The follow-up included the clinical and ultrasound investigation every 12 month later.



**Fig. 2.**  
CT scan of heterotopy thyroid tissue on the radix of the tongue.\*



**Fig. 3.**  
The A slide X- ray of the base of tongue before surgery used CO<sub>2</sub> laser beam.  
The B slide X- ray of the base of tongue after surgery used CO<sub>2</sub> laser beam one month later.\*

\* We are grateful for the assistance provided by imaging – Dr. Keclíc and Dr. Horejší, Dept of Radiology 1st Medical School of Charles University, Prague.

### Case reports

Seven cases of heterotopy of thyroid tissue are presented here (Tab. 2).

#### *Case 1 – Female, 56-year-old*

Admitted to the ENT department for suffocation. Urgent tracheostomy was performed. The airway obstruction in hypopharynx was caused by a tissue mass in the base of the tongue.

Scintiscan of the neck showed isotope (iodine I<sup>131</sup>) uptake in the tissue mass of the tongue, not in the neck. The tissue mass in the base of the tongue was removed surgically from intraoral approach. Histology showed normal thyroid cells.

Three years later, scintiscan showed significant iodine uptake in the neck and a small iodine uptake in the base of the tongue.

#### *Case 2 – Female, 48-year-old*

Referred to the ENT department with the history of a subtotal thyroidectomy. The left lobe of the thyroid was not found in the surgery. A tumorous mass at the hyoid bone was discovered 9 years later.

Sonography showed a solid tumorous tissue and the fine needle puncture showed thyroid cells. Isotope (iodine I<sup>131</sup>) uptake, using scintiscan, was evident in the tumorous mass and a small uptake in the residual lobe of normal thyroid was found as well. The tumorous mass was removed by surgery with subtotal resection of the hyoid bone. Histology showed normal solid tissue. Moderate thyroid hypofunction, which manifested itself after surgery, was compensated by hormonal medication.

#### *Case 3 – Female, 46-year-old*

She came to the ENT department for a tissue mass on the base of her tongue causing dysphonia and dysphagia. The sonography was performed, and no thyroid tissue was present in the physiological region. CT scan showed the tissue mass by basis of tongue.

The subsequent scintiscan (iodine I<sup>131</sup>) showed uptake on the floor of mouth. CO<sub>2</sub> laser resection was performed, this is easier on the patient. Histol-

**Table 2.** Cases of heterotopy of thyroid tissue on the Department of otorinolaryngology and Head and Neck surgery 1. Medical School of Charles University of Prague.

Patient No.	Sex	Age	Locality of the thyroid tissue	Therapy
1.	Female	56	Lingual	Subtotal resection
2.	Female	48	Subhyoid	Total removal
3.	Female	46	Lingual	Laser CO <sub>2</sub> total resection
4.	Female	46	Lateral left site region III	Neck dissection Total thyroidectomy
5.	Female	41	Lingual	Laser CO <sub>2</sub> total resection
6.	Female	15	Hyoid	Total removal
7.	Female	7	Subhyoid	Hormonal therapy

ogy showed a normal thyroid tissue with stimulation of the functioning cells.

One year after surgery, the otolaryngology investigation (indirect laryngoscopy) showed no tumorous mass in the base of the tongue, there was only small uptake on the scintiscan.

#### Case 4 – Female, 46-year-old

Patient No. 7 was referred to ENT department with a tissue mass in the lateral neck region along carotid bifurcation. This patient has had a manifestation of this resistance five months previously. The FNAB was performed. Normal thyroid cells were identified, plus some changed cells. This FNAB showed a suspicious papillary carcinoma. Sonography showed a solid tissue on the left side in the lateral neck region 2x2.5x1 cm large, thyroid tissue in normal location.

Scintiscan was not indicated, subsequently the sonography and FNAB showed the goitre thyroid and suspicious metastases in lateral neck region on the left site.

The thyroid gland was found to be in the normal location. The tissue mass on the left side was totally removed by surgery with a radical selective neck dissection and a total thyroidectomy.

Histology form resistance in lateral neck region on the left side showed a normal thyroid tissue with peripheral tissue atrophy of the functioning cells. In the neck dissection two lymphnodes without any tumorous changes was detected. Histology of the thyroid gland showed a goitre without tumorous changes with a group of oncocyctic cells. No malignant tumour was identified in the thyroid gland and lymph nodes.

Hormonal substitution therapy and a regular follow-up by an endocrinologist and otolaryngologist was recommended. The sonography six months after surgery showed the absence of the thyroid gland on the neck.

#### Case 5 – Female, 41-year-old

A tissue mass on the base of her tongue was causing dysphonia and dysphagia, when this patient

come to the ENT department. Thyroid cells were found in peroral biopsy.

Scintiscan of the neck and oropharynx showed an iodine 131 uptake in the base of the tongue and none in the neck. The mass on the base of the tongue was obvious from the X-rays as well. CO<sub>2</sub> laser resection was performed, for the same reasons as in patient No.3. The histology showed a normal thyroid tissue with a stimulation of the functioning cells.

One year after surgery, X-rays showed no tumorous mass in the base of the tongue, there was only small uptake on the scintiscan.

#### Case 6 – Female, 15-year-old

Referred to ENT department with a tissue mass before the hyoid bone in the midline. This patient has been having progressive swallowing problems. Sonography showed a solid tissue mass at the hyoid bone 6x3x2 cm large, but no thyroid tissue in normal location. The FNAB was performed. Normal thyroid cells were identified.

Scintiscan was not indicated, the sonography and FNAB showed the ectopy of thyroid tissue. No thyroid gland in normal location was found during the medical examination. The total tissue mass in the midline on the hyoid bone was removed by surgery. The histology showed a normal thyroid tissue with a stimulation of the functioning cells.

Hormonal substitution therapy and a regular follow-up by an endocrinologist and otolaryngologist was recommended. The sonography one year after surgery showed the absence of thyroid gland on the neck.

#### Case No.7 – Female, 7-year-old

This patient was referred to the ENT department with a tissue mass in the midline at the hyoid bone as a thyroglossal duct cyst. No thyroid gland in normal location was found by the physicians' examination.

Sonography showed a solid tissue mass at the hyoid bone 1.5 cm large, but no thyroid tissue in the normal location. Scintiscan showed an iodine I<sup>123</sup> uptake into the mass at the hyoid bone.

Hormonal therapy and a regular follow-up by an endocrinologist and otolaryngologist was recommended.

## Discussion

Up to now, time literature described more than 600 cases of heterotopic thyroid tissues. We found reports about ectopic thyroid tissue [25, 26, 27, 28, 29, 30, 31, 32, 33, 34, 35, 36], about dystopic thyroid tissue [37, 38, 39, 40, 41, 41, 42, 43], about aberrant and accessory aberrant thyroid tissue [44, 45, 46]. These anomalies might be associated with other syndromes (Tricho-rino-phalangeal syndrome, Penderd's syndrome etc.) [47, 48]. The teratogenic thyroid tissue was described too [23, 24].

The first of these states (conditions) was described by Mackenzie in 1880 [16].

The developmental defect, maldescent was described later [18]. The aetiology is ambiguous and isn't described in any detail [5, 18].

The heterotopic thyroid tissue is frequently quantitatively deficient. Functioning at marginal levels, it should be subjective to excessive thyroid stimulating hormone (TSH) stimulation, with resulting hyperplasia and compensatory enlargement. The TSH stimulation is one of the high risk factors possibly resulting in carcinomatous change [33].

The first symptoms of presence of the heterotopic thyroid tissue vary. They are mostly airway obstruction, swallowing problems, speech problems, cosmetic problems [10, 28, 30, 32, 40, 42].

The bleeding from this tissue is described too [12, 16]. The functional damage – presence of hypothyreosis – is not in the foreground of the symptoms, but it is present in most patients, too [10, 15, 22, 27, 33].

The evidence of carcinomatous change in lingual thyroid was described by Fisch and Moore [5] in approximately 4–6 % of cases. The papillary carcinoma arising from lingual thyroid is described by numerous authors [2, 3, 4, 6, 7, 8, 9].

A variety of management methods of the heterotopy of thyroid tissue have been reported [1, 15, 18, 31]. More authors defend the total or near total (subtotal) removal of heterotopy thyroid tissue [5, 11, 12, 14, 18, 38, 44]. The total resection using the CO<sub>2</sub> laser is also reported [10]. The total destruction with I<sup>131</sup> (radioiodine isotope) is described by Waschulewski et al. [19]. Some authors described the autotransplantation of this heterotopic tissue [34, 46].

Other authors described conservative approaches to thyroid tissue heterotopy. These approaches were summarised by Wertz [1] and divided into three groups:

**A. No therapy.** When the patient is euthyroid and has no functional symptoms or other pathologies.

**B. Use of Suppressive Thyroid Hormone.** In patients with hypothyroidism outside the first group.

**C. Surgery.** Total or near total removal is described by Wertz [1] as more hazardous but it has been accomplished on several occasions. Wertz described the autogenous transplantation, too.

The following preferred approach was used in our department in the management of thyroid tissue heterotopy. We summarized Wertz's type A and B as one and used this for children's cases.

*The first group: No surgery.*

This group includes children and cases that exclude surgery and where endocrinological therapy is required. The follow-up is necessary.

When these patients grow out of childhood, they are treated as the second group.

*The second group: Surgery.*

This group includes all patients with heterotopy of thyroid tissue. The total removal of thyroid tissue is the method of choice. There can be carcinomatous change or development of mechanic syndrome, dysphagia or airway obstruction. The total removal is then recommended as the best type of surgery. Patients' condition following this operation is equal to those patients after total thyroidectomy and the substitution therapy with synthetic thyroid hormones is given.

The danger of complication from subtotal removal or transplantations of this tissue is higher (uncontrolled enlargement, hypothyroidism, high value of TSH hormones, carcinomatous change, development of mechanical syndromes etc.).

The alternative to total removal is the radioiodine destruction of this tissue. This approach was described in literature [19]. Since the radioiodine destruction might be complicated by low accumulating tissue and because of radiation, we preferred the surgical approach whenever the surgery was possible.

The conservative approach (the first group) is recommended for children, since their organism is in a growing phase. It is supplemented by the substitution therapy with thyroid hormones and a follow-up. Conservative therapy is necessary and indicated for children if they are without mechanical symptoms. In case of tissue enlargement or progresses in mechanical symptoms or bleeding, the removal of thyroid tissue is the only possibility. The removal of this tissue is performed in adolescent age when the child stops growing.

Total removal of the heterotopic thyroid can be accomplished with relative ease. A patient after total or nearly total removal of lingual thyroid is followed up as after any total thyroidectomy. The surgical

danger is comparable with total thyroidectomy and we know that this approach is not hazardous.

## Conclusions

Any otolaryngologist and endocrinologist can come across the heterotopic thyroid tissue. These tissues were present mostly in female patients. The carcinomatous change was described, together with bleeding and airway obstruction. The substitution with synthetic thyroidal hormones was always necessary. Therapy represented the total removal of this tissue when possible. In children the conservative (non surgical) approach was preferred, in contrast to adults.

## REFERENCES

- Wertz ML. Management of undescended lingual and subhyoid thyroid glands. *Laryngoscope* 1974; **84**:507–521.
- Balasubramaniam GS, Stillwell RG, Kennedy JT. Papillary carcinoma arising in ectopic thyroid tissue within a bronchial cyst. *Pathology* 1992; **24**:214–246.
- Betkowski A, Gotkowska K, Rzepka M. Rak pecherzykowy ektopowej tarzycy jezykowej. *Otolaryngol Pol*, 1993; **47**:368–373.
- Bukchanevski RP, Casler JD, Oliver J, Conley J. Squamous cell carcinoma and lingual thyroid. *Ear Nose Throat J* 1991; **70**:505–507.
- Fish J, Moore RM. Ectopic thyroid tissue and ectopic thyroid carcinoma. *Annals of Surgery* 1963; **157**:212–218.
- Machado NO, Rao BHA. Papillary carcinoma arising from lingual thyroid. *Indian J Otolaryngol Head Neck Surg* 1991; **1**:36–37.
- Pacheco Ojeda L, Micheau C, Stafford N, Marandas P, Luboinski B, Martinez AL. Papillary carcinoma in thyroglossal duct remnants. *Eur Arch Otorinolaryngol* 1991; **248**:268–270.
- Yanagishawa K, Eisen RN, Sasaki CT. Squamous cell carcinoma arising in a thyroglossal duct cyst. *Arch Otolaryngol Head and Neck Surg* 1992; **118**:538–541.
- Zink A, Raue F, Hofmann R, Ziegler R. Papillary carcinoma in an ectopic thyroid. *Horm Res* 1991; **35**:86–88.
- Astl J, Betka J, Slavíček A, Jablonický P, Límanová Z. Heterotopic thyroid tissue. *Head and Neck Diseases* 1993; **2**:72–75.
- Gallo WJ, Ellis E. Management of a large lingual thyroid in the orthognathic surgery patient. *Oral Surgery Oral Medicine, Oral Pathology* 1991; **59**:344–348.
- Gierek T, Zbrowska-Bielska D, Majzel K. Chirurgiczne leczenie jedyniej tkanki tarczycowej na jezyku z powodu masywnych krwawien. *Otolaryngol Pol* 1995; **XLIX** 2:103–107.
- Helidonis E, Dokianakis G, Papazoglou G, Pantazopoulos P, Thomopoulou H. Ectopic thyroid gland in the submandibular region. *J Laryngol Otol* 1980; **94**:219–224.
- Ijaduola GTA. Lingual and normally located thyroid glands in Nigerian children. *J Laryng Otol* 1982; **96**:177–180.
- Kozol RA, Geelhoeden GW, Flynn SD, Kinder B. Management of ectopic thyroid nodules. *Surgery* 1993; **114**:1103–1106.
- Mackenzie M. *Krankheiten der Halses und der Nase*. Berlin: Berlin Verlag von August Hirschwald; **1880**:840.
- Precechtel A. XVIII. výroční zpráva Cs. ORLS za rok 1938/39, 1940. *Cas Lék Ces* 1939, **78/48**:1280–1282.
- Ward GE, Centrell JR, Allan WB. The Surgical Treatment of Lingual Thyroid *Ann of Surgery* 1954; **139**:536–539.
- Waschulewski H, Dörfel EW. Die Bedeutung des radioaktiven Jods J 131 für Diagnose und Therapie der Zungenschilddrüsen. *Roschr Röntgenstr* 1959; **90**:727–734.
- Bough DI, Greco T, Romanczuk B. Imaging case study of the month thyroid hemiagenesis. *Ann Otol Rhinol Laryngol* 1994; **103**:328–330.
- Hsu CY, Wang SJ. Thyroid hemiagenesis accompanying an ectopic sublingual thyroid. *Clin Nucl Med* 1994; **19**:546.
- Shankar SM, Menon PS, Karmarkar MG, Goinnath PG. Dysgenesis of thyroid is the common type of childhood hypothyroidism in environmentally iodine deficient areas of north India. *Acta Paediatr* 1994; **83**:1047–1051.
- Cicek Y, Tasci H, Gokdokan C, Ones S, Gokcel S. Intra-abdominal ectopic thyroid. *Br J Surg* 1993, **80**:316.
- Rossen K, de Nully P, Skov BG. Heterotop thyroideaevaev lokaliseret intrapelvint. *Ugeskr Leagr* 1992; **154**:1114–1115.
- D'Archivio L, Parere P, D'Ascanio G. La tiroide linguale. *Minerva Stomatol* 1992; **41**:139–143.
- Banna M, Lasjaunias P. The arteries of the lingual thyroid, angiographic findings and anatomic variations. *AJNR-Am J Neuroradiol* 1990; **11**:730–732.
- Borgoni F, Liberatori E, Giamagli M, Galastri G, Piccini L, Parca G, Patrizi L, Tafi L, Biagi P. Lingual thyroid and hypothyroidism. Report of a case of a middle aged woman. *Panminerva Med* 1994; **36**:95–96.
- Cancarini F, Mezzeti M, Frattaroli FM, Berardi A, Bonomolo F, Reggio D. Lingual thyroid. A case report. *Italian J of surgical Sciences* 1990; **17**:265–268.
- Guneri A, Ceryan K, Iqci E, Kovanlikaya A. Lingual Thyroid: the diagnostic value of magnetic resonance imaging. *J Laryngol Otol* 1991; **1045**:493–495.
- Chan FL, Low LC, Yeung HW, Saing H. Case report: Lingual thyroid a cause of neonatal stridor. *Br J Radiol* 1993; **66**:462–464.
- Jeffrey MM, Fahey D. Lingual thyroid. Case report and review of literature. *Arch Otolaryngol* 1975; **101**:574–576.
- Maddern BR. Lingual thyroid in a young infant presenting as airway obstruction, report of a case. *J Pediatr Otorinolaryngol* 1990; **19**:79–80.
- Nemec J, Zamrazil V, Vána S. In: *Therapy of thyroid diseases (In Czech)*. Praha: Avicenum; 1991. p. 160.
- Skolnik EM, Yee KF, Golden TA. Transposition of the lingual thyroid. *Laryngoscope* 1976; **86**:785–791.
- Warnakulsuriya KA, Herath KB. Investigating a lingual thyroid. *Int J Oral Maxillofac Surg* 1992; **21**:227–229.
- Weider DJ, Parker W. Lingual thyroid. Review, case reports and therapeutic guidelines. *Ann Otol Rhinol Laryngol* 1988; **86**:841–847.
- Ansani L, Percoco G, Zandari F, Perazoni P, Gamba G, Antonioli G. Intracardiac thyroid heterotopia. *Am Heart J* 1993; **125**:1797–1801.
- Arriaga A, Myers E. Ectopic thyroid in the retrooesophageal superior mediastinum. *Otolaryngol Head and Neck Surg* 1988, **99**:338–341.
- Bando T, Genka K, Ishikawa K, Kuniyoshi M, Kuda T. Ectopic intrapulmonary thyroid. *Chest* 1993; **103**:1278–1279.
- Ferlito A, Giarelli L, Silvestri F. Intratracheal thyreoid. *J Laryng* 1988; **102**:95–96.
- Nielsen VM, Lovgreen NA, Elbrond. Intrathoracic goitre. Surgical treatment in an ENT department. *J Laryngol Otol* 1983; **97**:1039–1045.
- Osammor JY, Bulman CH, Blewitt RW. Intralaryngeal thyroid. *J Laryngol Otol* 1990; **104**:9:733–736.
- Richmond T, Whittaker J, Hassan R. Intracardiac ectopic thyroid: A case report and review of published cases. *Thorax* 1990; **45**:293–298.
- Aguirre A, de la Piedera M, Ruiz R, Portilla J. Ectopic thyroid tissue in the submandibular region. *Oral Surg Oral Med Oral Pathol* 1991; **71**:73–76.
- Rubenfield S, Joseph U, Schwartz M, Weber S, Ihingran S. Ectopic thyroid in the right carotid triangle. *Arch Otolaryngol Head and Neck Surg* 1988; **114**:913–917.
- Szemja Z, Sobieszczyk A, Sobieszczyk S. Transplantacja tarczycy jezykowej do przestzeni przedykowej. *Otolaryngol Pol* 1982; **36**:247–252.
- Dumic M, Ille J, Mikecin M, Cvitkovic M, Hitrec V, Potocki K. Trihoro-falangealni sindrom. *Lijec vesjn* 1993; **115**:163–165.
- Verlest J, Chanoine JP, Delange F. Radionuclide imaging in primary permanent congenital hypothyroidism. *Clin Nucl Med* 1991; **16**:652–655.