

Neuronavigation used for the transsphenoidal resection of a pituitary adenoma accompanied by a concha sphenoid sinus

Libo SUN¹, Yufei GAO¹, Chao FU¹, Fang LI², Conghai ZHAO¹

¹ Department of Neurosurgery, China-Japan Union Hospital, Jilin University, Changchun, Jilin Province, China

² Department of Neurosurgery, China-Japan Friendship Hospital, Beijing, China

Correspondence to: Conghai Zhao, MD.
Department of Neurosurgery, China-Japan Union Hospital, Jilin University,
Changchun 130033, Jilin Province, China.
TEL: +86 13104318588; FAX: +86 0431 84995625; E-MAIL: conghai@jlu.edu.cn

Submitted: 2012-11-24 *Accepted:* 2012-12-12 *Published online:* 2012-12-28

Key words: **Concha sphenoid sinus; pituitary adenoma; surgical approach; transsphenoidal surgery**

Neuroendocrinol Lett 2012; **33**(8):765–768 PMID: 23391974 NEL331112C01 © 2012 Neuroendocrinology Letters • www.nel.edu

Abstract

A concha non-pneumatized sphenoid is considered to be a contraindication for the transsphenoidal resection of a pituitary adenoma. Specifically, this anatomical variation makes it difficult to approach the sella turcica. However, in this report, an intra-operative navigational system was used as a guide to access the sella through the sphenoid sinus. This procedure was found to be both reasonable and safe.

INTRODUCTION

Transsphenoidal surgery (TSS) is currently a standard treatment approach for pituitary adenomas (Buchfelder & Fahlbusch 2002; Couldwell 2004; Jane *et al.* 2002). Moreover, it is a very effective neurosurgical procedure that has been associated with an excellent outcome and a low complication rate (Powell 2012). However, the region involved in this type of surgery is deep and narrow, with internal carotid arteries, optic nerves, and the hypothalamus in close proximity (Zhao *et al.* 2006). Therefore, direct access to the lesion is key to the success of this surgery. For the two cases of pituitary adenoma reported here, an intra-operative neuronavigational system was used to access each sella associated with a concha sphenoid sinus during the transsphenoidal surgeries performed. In both cases a successful outcome was achieved.

CASE REPORT

Case one

A 26-year-old female presented with amenorrhea, galactorrhea, and infertility for six months. Levels of serum prolactin were also found to be significantly elevated (>4 200 mIU/liter). Using dynamic contrast magnetic resonance imaging (MRI), a microadenoma was visualized (Figure 1A). A computed topography (CT) scan also revealed that the patient had a concha sphenoid sinus (Figure 1B). Initially, prolactin levels were treated with dopamine agonists (e.g., bromocriptine, 2.5 mg, tid, peroral administration) for three months. However, this approach was ineffective, and no symptomatic improvement was observed. Therefore, the patient underwent a neuronavigation-assisted transnasal transsphenoidal surgery (TSS) (Figure 1C). The poorly pneumatized sphenoid sinus area

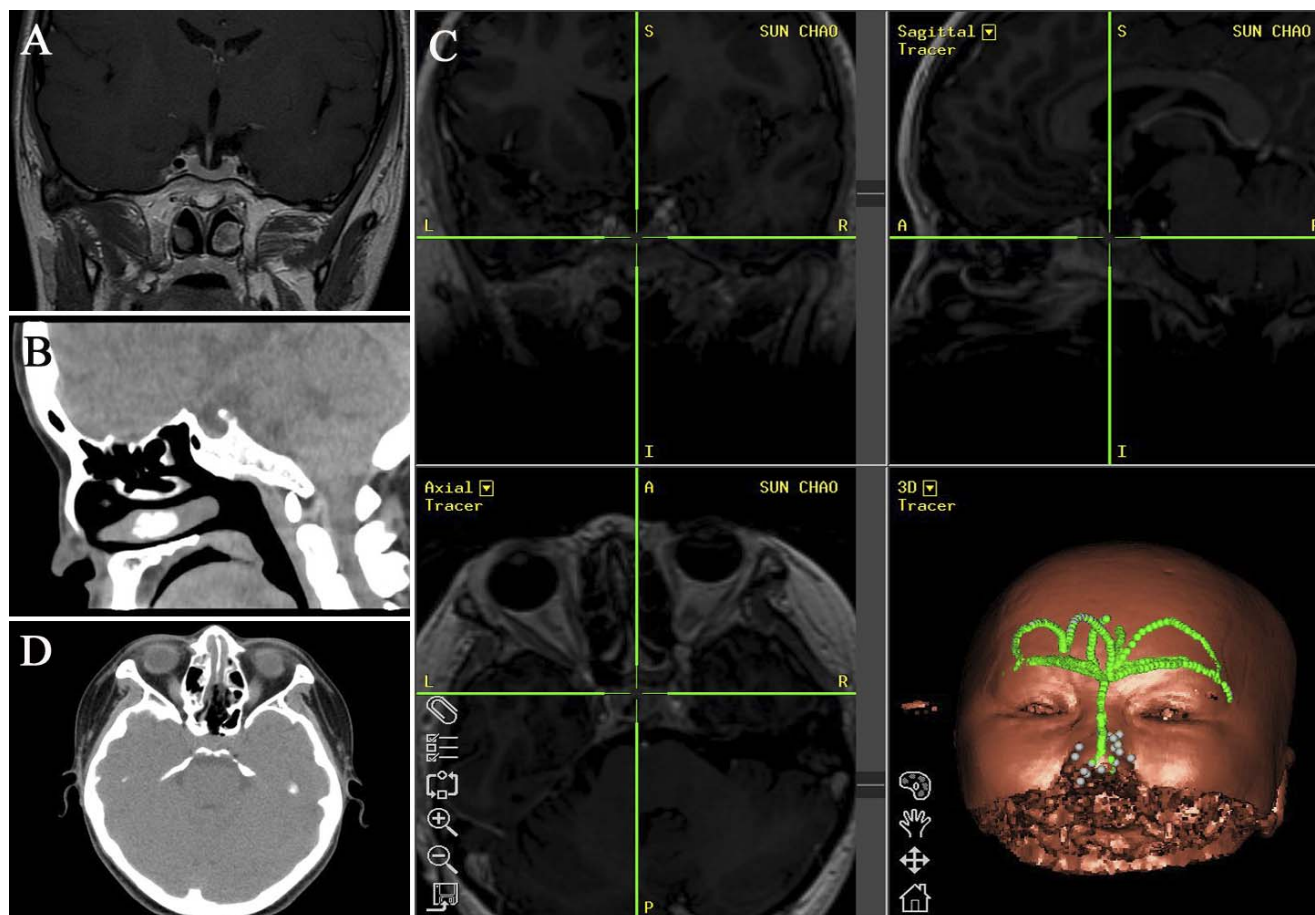


Fig. 1. (A) A dynamic coronal T1-weighted pre-operative image of a microprolactinoma present in the left side of the sella. This tumor did not exhibit enhancement following administration of contrast reagent. (B) Coronal CT scan of a concha sphenoid sinus. (C) Intraoperative navigation images that provided precise localization for drilling through the osseous portions of the skull base. (D) Post-operative axonal CT scan showing the bone window that was drilled in the sella bottom.

was safely cleared by using a high speed drill to provide a 1 cm access to the sella (Figure 1D). After a transfixion pin was inserted into the sellar floor, the dura was incised crosswise. The tumor was then shaved off circumferentially using a curet, then was sliced or split using a suction cannula to achieve complete resection. Three days after surgery, the patient's serum prolactin level was 2900 mIU/L, and there was no evidence of cerebrospinal fluid (CSF) fistula, anterior pituitary insufficiency, or nasal septum perforation. Therefore, the patient was released without any complications. Six months later, MRI showed the tumor was completely removed, and serum prolactin levels were 510 mIU/L. In addition, the patient did not experience any symptoms of amenorrhea or galactorrhea.

Case two

A 46-year-old male presented with an abrupt onset of oculomotor nerve (CN III) palsy. A physical examination found his body temperature to be 36.5 °C, and his left eye deviated outward with an enlarged pupil and droopy eyelid. The following day, digital subtraction

angiography (DSA) did not detect an aneurysm (Figure 2A). However, MRI revealed a sellar mass with peripheral enhancement, and this mass was found to be pressing on the left cavernous sinus. In addition, a concha sphenoid sinus was observed (Figure 2 B,C), and was confirmed with a CT scan (Figure 2D). Leukocyte levels were found to be normal, as well as the range of serum hormone levels detected. The patient underwent neuro-navigation-assisted transnasal TSS (Figure 2E), and the poorly pneumatized sphenoid sinus was safely drilled. As a result, the lesion was able to be completely cleared. Immunohistochemistry assays of the removed lesion detected an absence of adrenocorticotropic hormone (ACTH), follicle stimulating hormone (FSH), luteinizing hormone (LH), prolactin (PRL), thyroid stimulating hormone (TSH), and growth hormone (GH) expression. Moreover, a histopathological examination confirmed the presence of a non-functional pituitary adenoma (Figure 2F). Three weeks after surgery, no evidence of CN III was detected. Furthermore, MRI conducted an additional three months later found no evidence of a pituitary adenoma (Figure 3A,B).

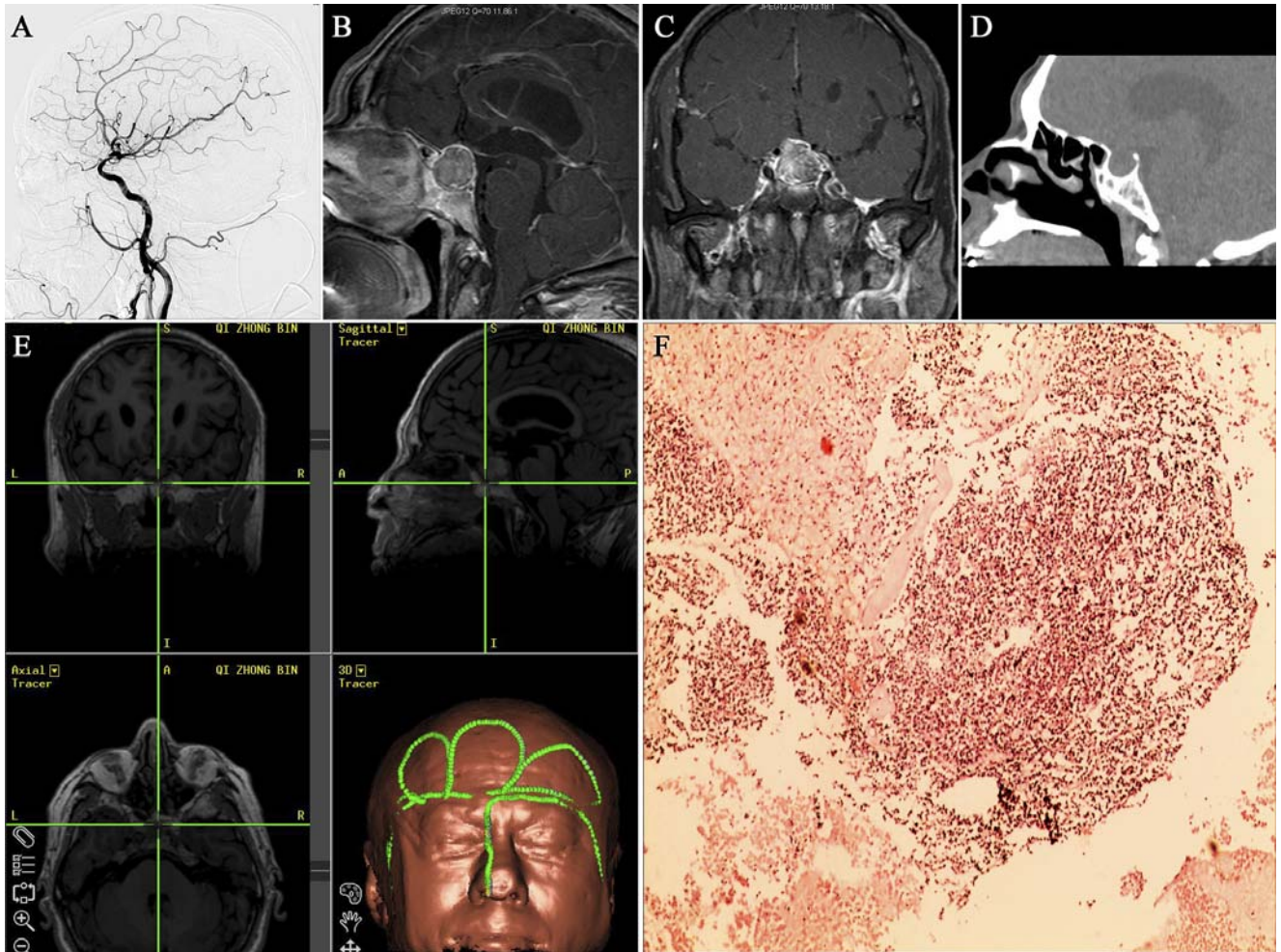


Fig. 2. (A) Digital subtraction angiogram (DSA) that revealed the absence of an aneurysm. (B) A pre-operative dynamic sagittal T1-weighted image that shows the sellar mass measured with peripheral enhancement and the presence of a concha sphenoid sinus. (C) A pre-operative dynamic coronal T1-weighted image that shows the left cavernous sinus is partially compressed. (D) Coronal CT scan confirming the presence of a concha sphenoid sinus. (E) Intraoperative navigation images that provided precise localization for drilling through the osseous portions of the skull base. (F) Histopathological examination with hematoxylin and eosin staining confirmed the presence of a non-functional pituitary adenoma.

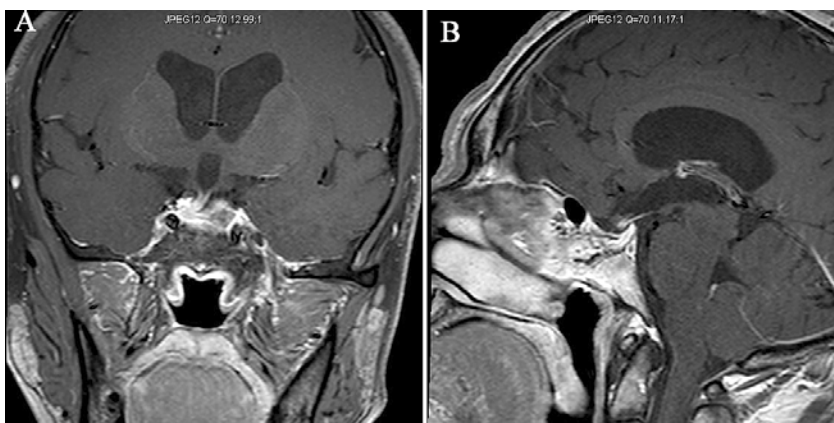


Fig. 3. Dynamic coronal (A) and sagittal (B) T1-weighted images obtained three months after surgery that show an absence of tumor.

DISCUSSION

Currently, TSS is a standard treatment for pituitary adenomas. However, there are several routes for accessing the sella. These include trans-ethmoid, trans-nasal,

and trans-septal, either microscopic or endoscopic, approaches, and these ultimately pass through the sphenoid sinus to reach the sella (Hamid *et al.* 2008). The sphenoid sinus is the main sinus cavity that occupies the body of the sphenoid bone. Anatomically, this

cavity can range from absent to extensively pneumatized (Wang *et al.* 2010), and this can impact surgical access. In >95% of cases, the concha of the sphenoidal sinus is pneumatized (Banna & Olutola 1983; Szolar *et al.* 1994). However, in the absence of a sphenoid air sinus, the pathway through the sphenoid bone is more complicated, thereby making it difficult to verify both the midline and the actual depth of the approach during surgery. A successful surgery requires the ability to navigate to the tumor, to visualize the anatomy, and to determine the adequacy of resection. At the same time, however, damage to surrounding structures must be minimized. It has previously been shown that an intra-operative neuronavigation system can reduce some of the post-operative complications associated with this type of surgery, especially the incidence of CSF leakage and the size of residual tumors (Zhao *et al.* 2006; Kajiwara *et al.* 2003; Thomale *et al.* 2005; Furtado *et al.* 2012). In addition, this navigation system can also accommodate MRI to generate a three-dimensional (3D) reconstruction prior to an operation. In the present cases, MRI was used during the transsphenoidal surgeries performed. For example, the midline of the lesion was able to be accurately and consistently identified during the drilling of the sphenoid bone using a neuronavigation system. In addition, access to the lesion could be visualized intermittently. Based on the coronal and axial measurements obtained for the tumors, the transverse diameter of the opening window scope on the sella floor was drilled. With appropriate drilling, exposure and excision of the tumor was facilitated.

For the first case described involving microprolactinoma, surgery was considered a secondary option to administration of dopamine agonists (DAs). DAs have previously been shown to be effective, and correspondingly, have become widely accepted as a primary therapy for PRL adenomas. For example, bromocriptine has been used for years for the normalization of PRL in 80–90% of microadenomas, and up to 70% of macroadenoma cases have achieved restoration of gonadal function and tumor reduction with administration of bromocriptine (Colao *et al.* 2009). However, up to 12% of these patients did not tolerate the drug in therapeutic doses due to side effects, and 5–10% of patients experienced only minimal, if any response, following bromocriptine therapy (Boyd 1995). In the present case, bromocriptine therapy was not effective in suppressing PRL secretion. Drug resistance has been considered as a surgical indication, with partial tumor resection associated with better hormonal control and a lower dose of DAs (Primeau *et al.* 2012). For other treatments, radiotherapy may require up to 20 years for the maximal effect to be achieved, and even then, prolactin levels may not return to a normal range. Radiation therapy is also associated with hypopituitarism as a side effect. In addition, cranial nerve damage or secondary tumor formation is possible, although rare. Therefore, surgical resection represents the most successful treat-

ment approach to date. Correspondingly, for the second patient who presented with oculomotor nerve (CN III) palsy and a slightly pressed cavernous sinus, surgical resection was performed. Therefore, in both of the cases presented, TSS was the optimal treatment despite the presence of a concha non-pneumatized sphenoid, which is typically considered to be a contraindication for the transsphenoidal resection of a pituitary adenoma.

In the present case report, a neuronavigation system was used to provide precise localization of each tumor, and provided better access to each lesion by facilitating drilling through the osseous portions of the skull base. The lesions present were also able to be identified accurately and dynamically, with the pathway and direction of access shown intermittently. These cases demonstrate that neuronavigation-assisted transsphenoidal resection of a pituitary adenoma from a patient with a poorly pneumatized sphenoid sinus is possible, and represents a reasonably safe procedure.

REFERENCES

- Banna M, Olutola PS (1983). Patterns of pneumatization and septation of the sphenoidal sinus. *J Can Assoc Radiol.* **34**: 291–293.
- Boyd A (1995). Bromocriptine and psychosis: a literature review. *Psychiatric Quarterly.* **66**: 87–95.
- Buchfelder M, Fahlbusch R (2002). The 'classic' transsphenoidal approach for resection of pituitary tumors. *Operating Technique in Neurosurgery.* **4**: 210–217.
- Colao A, Pivonello R, Di Somma C, Savastano S, Grasso LF, Lombardi G (2009). Medical therapy of pituitary adenomas: effects on tumor shrinkage. *Rev Endocr Metab Disord.* **10**: 111–123.
- Couldwell WT (2004). Transsphenoidal and transcranial surgery for pituitary adenomas. *J Neurooncol.* **69**: 237–256.
- Furtado SV, Thakar S, Hegde AS (2012). The use of image guidance in avoiding vascular injury during trans-sphenoidal access and decompression of recurrent pituitary adenomas. *J Cranio-maxillofac Surg.* **40**: 680–684.
- Hamid O, El Fiky L, Hassan O, Kotb A, El Fiky S (2008). Anatomic variations of the sphenoid sinus and their impact on trans-sphenoidal pituitary surgery. *Skull Base.* **18**: 9–15.
- Jane JA Jr, Thapar K, Kaptain GJ, Maartens N, Laws ER Jr (2002). Pituitary surgery: transsphenoidal approach. *Neurosurgery.* **51**: 435–442.
- Kajiwara K, Nishizaki T, Ohmoto Y, Nomura S, Suzuki M (2003). Image-guided transsphenoidal surgery for pituitary lesions using Mehrkoordinaten Manipulator (MKM) navigation system. *Minimally Invasive Neurosurgery.* **46**: 78–81.
- Powell M (2012). Microscope transsphenoidal surgery. *Acta Neurochir (Wien).* **154**: 913–917.
- Primeau V, Raftopoulos C, Maiter D (2012). Outcomes of trans-sphenoidal surgery in prolactinomas: improvement of hormonal control in dopamine agonist-resistant patients. *Eur J Endocrinol.* **166**: 779–786.
- Szolar D, Preidler K, Ranner G, Braun H, Kugler C, Wolf G, et al (1994). The sphenoid sinus during childhood: establishment of normal developmental standards by MRI. *Surg Radiol Anat.* **16**: 193–198.
- Thomale UW, Stover JF, Unterberg AW (2005). The use of neuronavigation in transnasal transsphenoidal pituitary surgery. *Zentralbl Neurochir.* **66**: 126–132.
- Wang J, Bidari S, Inoue K, Yang H, Rhoton A Jr (2010). Extensions of the sphenoid sinus: a new classification. *Neurosurgery.* **66**: 797–816.
- Zhao Y, Yu S, Wang R, Zhao J (2006). Clinical application of a neuronavigation system in transsphenoidal surgery of pituitary macroadenoma. *Neurosurg Rev.* **29**: 306–312.