

Iron and aluminum in Alzheimer's disease

Francesco Di Lorenzo, Bernardino Di Lorenzo

"Ambulatorio Privato di Scienze Mediche", Valenzano, Bari, Italy

Correspondence to: Francesco Di Lorenzo, MD.
Via Pigna n.4, 70010 Valenzano, Bari, Italy.
TEL: +39-3296163725; E-MAIL: f.dilorenzo@email.it

Submitted: 2013-04-12 Accepted: 2013-10-27 Published online: 2013-11-25

Key words: **metals; neurodegenerative disorders; chelation therapy**

Neuroendocrinol Lett 2013; 34(6):504–507 PMID: 24378455 NEL340613C01 ©2013 Neuroendocrinology Letters • www.nel.edu

Abstract

In this case presentation, a woman with high serum levels of aluminum was treated with chelation therapy with deferoxamine and ascorbic acid. This patient was initially bedridden and the clinical situation was complicated by epileptic seizures. After the chelation therapy, the clinical condition was ameliorated and the therapy continued without the correlation to aluminum serum levels. The role of metals in neurodegenerative disorders and the correlation between iron metabolism and amyloid beta peptide are described. This case suggests chelation therapy could represent a promising therapeutic option for this dramatic disease.

Abbreviations:

Aβ	- amyloid beta peptide
AD	- Alzheimer's disease
ADL	- activity of daily living
APP	- amyloid precursor protein
BPSD	- behavioral and psychological signs and symptoms in dementia
DFO	- deferoxamine
DMT1	- divalent cation transporter
HC	- Huntington's disease
HJV	- hemojuvelin
IADL	- instrumental activities of daily living
IRE	- iron regulatory elements
IRP 1-2	- iron regulatory proteins
MMSE	- mini mental state examination
mRNA	- messenger RNA
NFT	- neurofibrillary tangles
PD	- Parkinson's disease
RNS	- reactive nitrogen species
ROS	- reactive oxygen species
Tc	- computed tomography

was also bedridden. The following are the essential elements of chelation therapy and the radiological and serological tests performed before and during the treatment. Additionally, we provide an extremely synthesized description of the scientific basis for the role of metals in neurodegenerative disorders.

CLINICAL CASE

In March 2008 L.A. was a 71-year-old female, weighing 65kg. Her father had died from gut cancer and the mother probably suffered from Alzheimer's disease. Beta-thalassemic herself, she had no other disease. The first symptoms appeared in May 2001. Diagnosis and therapy, which was formulated by the "Unità di Valutazione Alzheimer" (Diagnostic and therapeutic centre for dementias) – Department of Neurology – "Di Venere hospital" – in Bari – Italy reported the following: "Possible Dementia of Alzheimer". Consequently the neuropsychological evaluation of May 2001 evidenced an MMSE value <20 and activity of daily living and the instrumental activity of daily living were 3 and 2. The consecutive neuroTc reported: "No evidence of densitometric altera-

INTRODUCTION

The following is the case of a patient with Alzheimer's disease with behavioral and psychological signs and symptoms of dementia. The case was complicated by epileptic seizures and she

tion of brain parenchyma. Atrophy of frontal lobes. Ventricular system in axis, no dilatations" (Figure 1). The electroencephalograms of July 2001 reported "Pc/s rytm reactive, badly modulates; diffuse slowing down especially in the temporal lobes". No particular alterations in serological tests were found. The therapy was: donepezil 5 mg cps once a day.

In January 2002 the patient was found to be in stable condition but she developed behavioral symptoms with depression and irritability. Consequently, the therapy consisted of donepezil 10 mg cps once a day and one 50 mg tablet sertraline once a day.

In July 2002 the patient was diagnosed with sleep disorders. One 10 mg table zolpidem once a day was added.

In January 2003 she was found with agitation, irritability, delusions and hallucinations. Consequently risperidone 0,5 mg was added to the therapy; in January 2004 the dosage was elevated to 1 mg; then, after the development of parkinsonism, this drug was substituted by quetiapine 25 mg tablet administered twice daily from February 2008. In May of the same year the patient was bedridden and the situation was complicated by partial epileptic seizures.

In May 2008, due to the seriousness of the situation and the decline of general conditions, the patient was laid off by the neurologist that followed her with the anti-epileptic therapy based on a carbamazepine 400 mg tablet twice a day and Phenobarbital 100 mg cps once a day.

So, we decided to examine the patient for heavy metal serological levels. In June 2008, we found normal values for zinc, copper, iron and lead but high levels of aluminum (38 mcg/l; n.v. <10 mcg/l). After the com-

parison from "Centro antiveleni" (Venoms centre) of Milan, we applied the chelation therapy: deferoxamine 500 mg im twice a day with ascorbic acid 150 mg im once a day for six days per month.

In August 2008 her aluminum serum level was 24 mcg/l. The general condition was ameliorated. Epileptic seizures were not occurring.

In September 2008 and October 2008 the values were 12 and 5 mcg/l respectively. There was an enormous clinical improvement: the patient resumed to walk, and there were no epileptic seizures. So, we decided to reduce Phenobarbital for its cognitive effects, and we substituted levetiracetam 1500 mg oral solution twice a day. In November 2008, we abrogated carbamazepine, and in December quetiapine.

Due to this clear improvement, we decided, on the basis of literature's data, to continue with chelation therapy, specifically, deferoxamine 500 mg im twice a day with ascorbic acid 150 mg im once a day, three times a week.

After six months the patient was found in good condition: no epileptic seizures were noted, irritability and agitation were abolished and she walked unaided. So we reduced levetiracetam to 1000 mg twice a day and then after six months to 750 mg twice daily. The sleep disorders were abolished (she slept for 8 hours a night) and she repeated, if asked, some words, although she wasn't able to completely resume her speaking. She was stable for five years before she died in March 2013.

RESULTS

Therapy and clinical course

The patient, due to the seriousness of her condition, was treated with chelation therapy. First, for three months she received deferoxamine and ascorbic acid twice a day, every day for six days per month. Then, after positive clinical results, she received therapy twice a day for three times a week in which ascorbic acid was administered once a day. This therapy had the ability to abolish epileptic seizures and to reduce antiepileptic drugs (in particular Phenobarbital, which has a cognitive effect, was eliminated), helping to regain her ability to walk unaided and to prolong survival. No side effects were found and serological values of iron, aluminum, ferritin were found in the range of normality (haemocromocitometric too, considering she was a betathalasemic patient) (Table1).

Deferoxamine (DFO) is a chelation agent against iron and aluminum (Brown *et al.* 1982; Nebeker *et al.* 1984). This drug was the first aluminum chelator to be introduced in clinical practice and it was administrated with good efficacy either intramuscularly or intraperitoneally (Ciancioni *et al.* 1984; Molitoris *et al.* 1987).

Savory *et al.* (1998) have demonstrated that DFO can reverse the tau aggregates following two days of treatment in aluminum-induced neurofibrillary degenerations in rabbits.

Tab. 1. Correlation between serum levels of aluminum, ferritin and haemoglobin during the therapy. In this period no side effects were found and the values of ferritin and haemoglobin were normal in a patient with beta-thalassemia.

Date	Al (mcg/L)	Ferritin (mg/dl)	Hb (g/dl)
June 2008	38	80	10.2
July 2008 – start therapy	38	75	10.1
August 2008	24	45	10.2
Sptember 2008	12	50	10.3
October 2008	5	55	10.4
April 2009	6	57	10.2
September 2009	5.2	57	10.5
July 2010	5	68	10.1
January 2011	5	75	10.6
September 2011	4.5	74	10.4
May 2012	5.2	77	10.3
October 2012	4.8	79	10.5

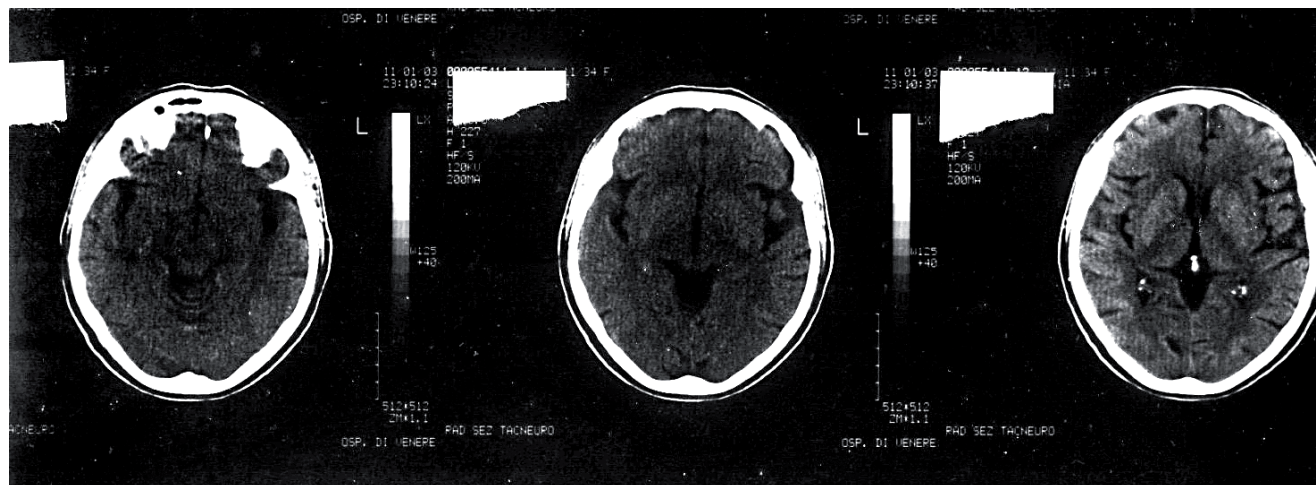


Fig. 1. Neuro Tc of May 2001. No evidence of densitometric alteration of brain parenchyma. Atrophy of frontal lobes. Ventricular system in axis, no dilatations.

The effectiveness of intramuscular DFO in AD patients was supposed by other authors (Crapper *et al.* 1991). The associations with ascorbic acid is intended to guarantee the reduction of Fe^{3+} to Fe^{2+} and Al^{3+} to Al^{2+} and to improve the binding of these metal ions to DFO (Herbert 1999).

DISCUSSION

The case described proposes again the role of metals in the pathogenesis of AD. This remark is deeply embedded in the scientific background that considers AD as a multifactorial disease.

Iron is strongly involved in amyloidogenesis. Hua *et al.* (2008). have demonstrated that this process is regulated by furin. In particular toxic insoluble aggregates of amyloid-beta-peptide (AB) are present in the brains of AD patients in extracellular senile plaques and in neurofibrillary tangles (NFT) created by the hyperphosphorylation and subsequent aggregation of the microtubule-associated protein, tau. This event causes the loss of cortical neurons (Duan *et al.* 2012).

AB is derived by the proteolytic cleavage of the amyloid precursor protein (APP) by the action of three secretases (α -, β -, γ -). There are two kinds of process involving α -secretase, which is the non-amyloidogenic pathway, and beta secretase, in which the toxic peptide AB is produced (Honjo *et al.* 2012). The processing of alpha and beta secretases is modulated by the protein furin (Seidah *et al.* 1994) which is involved in modulation of iron homeostasis through the production of soluble hemojuvelin (HJV) (Silvestri *et al.* 2008), an antagonist of bone morphogenetic protein (BMP) mediated activation of hepcidin. Hepcidin is important for iron metabolism (Babbitt *et al.* 2006). Furin transcription is regulated by cellular iron levels (Silvestri *et al.* 2008). High levels of this metal decrease furin transcription and impairs the soluble HJV, activating the amyloidogenic pathway. In contrast low levels of iron

causes the opposite process, which activates the non amyloidogenic pathway.

The correlation between iron and AD is demonstrated if we consider the control of iron metabolism at the level of mRNAs. There are two iron regulatory proteins, IRP1 and IRP2. In the condition of iron deficiency IRPs bind to stem loops known as iron regulatory elements (IREs) in mRNA. When the IREs are in the 5'-untranslated regions (UTR) of mRNA, as in the case of ferritin, ferroportin and amyloid precursor protein (APP) (Cho *et al.* 2010), binding to IRPs prevents initiation of translation; for DMT1 and transferrin receptor, IREs are in 3'-UTR, binding of the IRPs to IREs protects them against degradation. This results in iron uptake and blockage of iron storage and expression of APP. In the opposite conditions, we have the translations of ferritin, APP and ferroportin with low levels of transferrin and DMT1. In this way iron metabolism and APP expression regulation are strongly connected. As a result, they generate a vicious circle, because the iron excess causes a high production of reactive oxygen species. This ROS could shift to IRP1 to its IRE binding form and increase cellular iron intake via a transferrin receptor.

Aluminum is already involved in neurodegenerative disorders. Bharathi *et al.* (2008). have demonstrated that exposure to high levels of aluminum leads to NFT and that Al concentration is elevated in degenerating neurons of AD. The Al neurotoxicity is studied in a lot of works. In fact Al stimulates the production of an oligomeric toxic form of amyloid (Drago *et al.* 2008). By the way Al metabolism is correlated with iron homeostasis: Al stimulates the transcription of H-chain of ferritin with ferroxidase activity and generates iron dependent oxidative stress, maintaining the chronic flogosis (Campbell *et al.* 2000).

The correlation between iron and aluminum toxicity is demonstrated by the neuroprotective effects of DFO, the chelating agent used in this case report

(Mandel *et al.* 2007) The ROS production is not only Fe-dependent. In fact Al blocks respiratory chain complexes in hippocampus, striatum and cortical cortex in rats (Kumar *et al.* 2008) and it also down regulates the III complex transcription (Bosetti *et al.* 2001). Many enzymes are blocked by Al: choline-acetyl-transferase, pyruvic dehydrogenase (Szutowicz 2001) and glutamic-dehydrogenase (Yang X 2007; Yang SJ 2003) with the production of glutamate, notably neurotoxic and acetyl-CoA compartmentalization too.

The metal based ROS production in specific brain's regions, based on Fe, Al and Cu levels, can generate the peroxidation of polyunsaturated fatty acids in membrane phospholipids, with the consequent production of reactive aldehydes. In this way it causes damage to proteins with carbonyl functions. The damaged proteins overwhelming the ubiquitin-proteasome system with the generation of intracellular inclusion bodies, which are found in a lot of neurodegenerative diseases (AD, PD, HC etc.) (Lienert & Kozlowski 2012)

CONCLUSIONS

Although a multifactorial pathology like AD can't be addressed by focusing on a single feature, the dysregulation of metals metabolism, not necessarily correlated with serum markers, can represent a promising therapeutic option. In particular, it could be necessary to study the role of other metals, such as copper, and the possibility of a plurichelation of them.

ACKNOWLEDGMENTS

This case report is in the memory of Berardino Di Lorenzo, Physician and Master of Medicine.

REFERENCES

- Babitt JL, Huang FW, Wrighting DM, Xia Y, Sidis Y, Samad TA, Campagna JA, Chung RT, Schneyer AL, Woolf CJ, Andrews NC, Lin HY (2006). Bone morphogenetic protein signaling by hemojuvelin regulates hepcidin expression. *Nat Genet.* **38**(5): 531–539.
- Bharathi, Vasudevaraju P, Govindaraju M, Palanisamy AP, Sambamurti K, Rao KSJ (2008). Molecular toxicity of aluminum in relation to neurodegeneration. *Indian J Med Res.* **128**: 545–556.
- Bosetti F, Solaini G, Tendi EA, Chikhale EG, Chandrasekaran K, Rapoport SI (2001). Mitochondrial cytochrome c oxidase subunit III is selectively down-regulated by aluminum exposure in PC12S cells. *Neuroreport.* **12**(4): 721–4.
- Brown DJ, Ham KN, Dawborn JK, Xipell JM (1982). Treatment of dialysis osteomalacia with desferrioxamine. *Lancet* **2**: 343–345.
- Ciancioni C. *et al.* (1984). Plasma aluminum and iron kinetics in hemodialyzed patients after iv infusion of desferrioxamine. *Trans Am Soc Artif Intern Organs* **30**: 479–482.
- Crapper McLachlan DR *et al.* (1991). Intramuscular desferrioxamine in patients with Alzheimer's disease. *Lancet* **337**(8753): 1304–1308.
- Duan Y, Dong S, Gu F, Hu Y, Zhao Z (2012). Advances in the pathogenesis of Alzheimer's disease: focusing on tau-mediated neurodegeneration. *Transl Neurodegener.* **1**(1): 24. doi: 10.1186/2047-9158-1-24.
- Campbell A, Bondy SC (2000). Aluminum induced oxidative events and its relation to inflammation: a role for the metal in Alzheimer's disease. *Cell Mol Biol (Noisy-le-grand).* **46**(4): 721–730.
- Cho HH, Cahil CM, Vanderburg CR, Scherzer CR, Wang B, Huang X, Rogers JT (2010). Selective translational control of the Alzheimer amyloid precursor protein transcript by iron regulatory protein-1. *J Biol Chem* **285**: 312317–312332.
- Drago D, Cavaliere A, Mascetra N, Ciavardelli D, di Ilio C, Zatta P, Sensi SL (2008). Aluminum modulates effects of beta amyloid(1-42) on neuronal calcium homeostasis and mitochondria functioning and is altered in a triple transgenic mouse model of Alzheimer's disease. *Rejuvenation Res.* **11**(5): 861–871.
- Herbert V (1999). Haemochromatosis and Vitamin C. *Ann Intern Med.* **131**(6): 475–476.
- Honjo K, Black SE, Verhoeff NP (2012). Alzheimer's disease, cerebrovascular disease, and the β -amyloid cascade. *Can J Neurol Sci.* **39**(6): 712–728.
- Hua Y, Keep RF, Hoff JT, Xi G (2008). Deferoxamine therapy for intracerebral hemorrhage. *Acta Neurochir Suppl* **105**: 3–6.
- Kumar V, Bal A, Gill KD (2008). Impairment of mitochondrial energy metabolism in different regions of rat brain following chronic exposure to aluminium. *Brain Res.* **1232**: 94–103
- Lienert W, Kozlowski H (2012). Metal ions in Neurological Systems. Springer, 2–12.
- Mandel S, Amit T, Bar-Am O, Youdim MB (2007). Iron dysregulation in Alzheimer's disease: multimodal brain permeable iron chelating drugs, possessing neuroprotective-neurorescue and amyloid precursor protein-processing regulatory activities as therapeutic agents. *Prog Neurobiol.* **82**(6): 348–360.
- Molitoris BA *et al.* (1987) Efficacy of intramuscular and intraperitoneal deferoxamine for aluminum chelation. *Kidney Int* **31**: 986–991.
- Nebeker HG, Milliner DS, Ott SA, Sherrard DJ (1984). Aluminum-related osteomalacia – clinical response to desferrioxamine. *Kidney Int.* **25**: 173–180.
- Savory J, Huang Y, Wills MR, Herman MM (1998). Reversal by desferrioxamine of tau protein aggregates following two days of treatment in aluminum-induced neurofibrillary degeneration in rabbit: implications for clinical trials in Alzheimer's disease. *Neurotox* **(2)**: 209–214.
- Seidah NG, Chrétien M, Day R (1994) *Biochimie* **76**: 197.
- Silvestri L, Pagani A, Camaschella C (2008) *Blood* **111**: 924.
- Szutowicz A (2001). Aluminum, NO, and nerve growth factor neurotoxicity in cholinergic neurons. *J Neurosci Res.* **66**(5): 1009–1018.
- Yang SJ, Huh JW, Lee JE, Choi SY, Kim TU, Cho SW (2003). Inactivation of human glutamate dehydrogenase by aluminum. *Cell Mol Life Sci.* **60**(11): 2538–2546.
- Yang X, Zhang Q, Li L, Shen R (2007). Structural features of aluminium(III) complexes with bioligands in glutamate dehydrogenase reaction system—a review. *J Inorg Biochem.* **101**(9): 1242–1250.