

Neuropsychological results after gamma knife radiosurgery for mesial temporal lobe epilepsy

Zdeněk VOJTĚCH^{1,2}, Lenka KRÁMSKÁ³, Hana MALÍKOVÁ^{4,5},
Michaela STARÁ¹, Roman LIŠČÁK⁶

- 1 Department of Neurology, Center for Epilepsy, Na Homolce Hospital, Prague, Czech Republic
- 2 Department of Neurology, 3rd Medical Faculty, Charles University in Prague, Prague, Czech Republic
- 3 Department of Clinical Psychology, Center for Epilepsy, Na Homolce Hospital, Prague, Czech Republic
- 4 Department of Radiology, Center for Epilepsy, Na Homolce Hospital, Prague, Czech Republic
- 5 Institute of Anatomy, 2nd Medical Faculty, Charles University in Prague, Prague, Czech Republic
- 6 Department of Stereotactic and Radiation Neurosurgery, Center for Epilepsy, Na Homolce Hospital, Prague, Czech Republic

Correspondence to: Zdeněk Vojtěch, MD., PhD.
Department of Neurology, Na Homolce Hospital
Roentgenova 2, 15030 Prague, Czech Republic.
TEL: +420 2 5727 2556; FAX: +420 2 5727 3314; E-MAIL: zdenek.vojtech@homolka.cz

Submitted: 2015-08-19 *Accepted:* 2015-11-03 *Published online:* 2016-01-23

Key words: **epilepsy surgery; intelligence; memory; neuropsychology; radiosurgery; temporal lobe epilepsy**

Neuroendocrinol Lett 2015; **36**(8):771–778 PMID: 26921578 NEL360815A08 © 2015 Neuroendocrinology Letters • www.nel.edu

Abstract

OBJECTIVES: The aim of this study is to summarize our experience with neuropsychological changes after radiosurgical treatment for mesial temporal lobe epilepsy and subsequent surgery due to insufficient seizure control.

METHODS: Between November 1995 and May 1999, 14 patients underwent radiosurgical entorhinoamygdalohippocampectomy with a marginal dose of 18, 20 or 25 Gy to the 50% isodose. 9 of these patients subsequently underwent surgery. We compared Memory Quotients and Intelligence Quotients before and after the interventions.

RESULTS: We found a slight, but nonsignificant decline in intelligence and memory quotients one year after GKRS. Two years after radiosurgery there were no significant changes in any of the quotients. After surgery, we found significant increase in Global and Visual MQ, ($p < 0.05$). There were no statistically significant changes in verbal memory and intelligence performance after surgery.

CONCLUSION: Epilepsy surgery after unsuccessful radiosurgery could lead to improvements in cognitive functions in patients with mesial temporal lobe epilepsy.

Abbreviations:

AMTR	- anteromesial temporal lobe resection
CPS	- complex partial seizures
EEG	- electroencephalography
FS	- full scale
GKRS	- radiosurgery using Leksell Gamma Knife
IQ	- Intelligence Quotients
MQ	- Memory Quotients
MRI	- magnetic resonance imaging
MTLE	- mesial temporal lobe epilepsy
SAH	- selective amygdalohippocampectomy
WAIS-R	- Wechsler Adult Intelligence Scale-Revised
WMS-R	- Wechsler Memory Scale- Revised

INTRODUCTION

More than 30% of epilepsy patients continue to experience seizures while on multiple antiepileptic drugs. Mesial temporal lobe epilepsy (MTLE) in particular is often pharmacoresistant. Epilepsy surgery is a successful treatment option for these patients and its efficacy has been confirmed by two randomized clinical trials (Engel *et al.* 2012; Wiebe *et al.* 2001). It results in long-term seizure freedom in about 70% (62–83%) of cases (Mathon *et al.* 2015). Mortality following temporal resection approaches zero. However, the rate of neurological and surgical complications is not negligible (Georgiadis *et al.* 2013). Nonetheless, permanent sequelae are typically below 2%.

The goal of epilepsy surgery is seizure control as well as preventing decline in social, vocational, and cognitive performance and minimizing the risk of accident or sudden unexplained death in epilepsy. However, cognitive outcomes may be affected by surgery. As temporal lobes play an important role in declarative memory function, including episodic and semantic memory, surgical resection is linked to memory difficulties. This morbidity is dependent on several factors. The primary predictor of postsurgical memory loss following temporal resection is the presurgical functional and structural status of the mesial temporal lobe to be resected (assessed by structural or functional magnetic resonance imaging – MRI, FDG-PET and intact presurgical verbal memory ability on neuropsychological or Wada testing.) (York *et al.* 2003; Helmstaedter *et al.* 2011). At group level, anterograde verbal memory decline is the most consistently reported impairment, typically after left-sided resections (Hamberger & Drake 2006). It occurs in between 22% and 63% of these patients (Sherman *et al.* 2011). Performance memory impairments are reported less consistently after resections in the speech nondominant temporal lobe and occur in approximately 6%–32% of patients (Dulay *et al.* 2009b). The type of operation may also play some role in seizure and cognitive outcome. More extended resections may be superior with regard to seizure control (Schramm 2008). In his review Schramm found five studies which reported better seizure outcome with more extensive anteromesial temporal lobe resection (AMTR), but seven studies which did not. A comparison of selective amygdalohippocampectomy (SAH) and AMTR yields even more confusing results. Six out of eight studies did not demonstrate a worse seizure outcome for SAH. However, more functional tissue may be resected during more generous resections, thereby causing a worse cognitive outcome. There is considerable evidence for somewhat better neuropsychological results with SAH, although this was not found consistently. It follows that, from the neuropsychological point of view, smaller and tailored resections with minimal effect on the functional integrity of tissues or fibre tracts may be preferable (Helmstaedter 2013). The

development of alternative treatment strategies capable of minimizing the cognitive and surgical risks inherent in conventional epilepsy surgery is justifiable.

The principle of stereotactic radiosurgery using Leksell Gamma Knife (GKRS) is to administer a single high dose of radiation in a precisely targeted fashion to destroy or functionally inactivate the cells within a defined structure without affecting nearby normal brain tissue. This method was conceptualized by Leksell for functional neurosurgery (Leksell 1951). Currently it is a treatment option for several vascular and neoplastic diseases (Yang & Barbaro 2007). Its minimal invasiveness and efficacy in the treatment of symptomatic epilepsy caused by difficult-to-access lesions (e.g. intracerebral tumors, arteriovenous malformations, cavernous hemangiomas and hypothalamic hamartomas) also make it an attractive treatment modality for MTLE. The first GKRS for MTLE was performed by Régis *et al.* in 1993 (Régis *et al.* 1995). It had originally been hypothesized that GKRS as a neuromodulatory treatment could be effective in subnecrotic doses (Régis 2013). Later clinical experience showed that seizure reduction could only be achieved by the destruction of the target structures (Chang *et al.* 2010).

Several advantages and disadvantages of GKRS compared with standard microsurgery have been reported (Régis & Roberts 1999). Its main advantages are the completely bloodless nature of the procedure, with a shorter hospital stay and recovery period. Another advantage is the possibility of performing subsequent open resection in cases of treatment failure. However, any significant antiseizure effect is delayed (e.g. 8–26 months after GKRS) (Bartolomei *et al.* 2008). Other disadvantages of GKRS include early (collateral edema, intracranial hypertension) or delayed (late radiation necrosis, cyst formation) post-irradiation side effects due to the large target volume (Hoggard *et al.* 2008, Kawamura *et al.* 2012). These risks bring into question any comparison of invasiveness between microsurgery and GKRS. The absence of histological confirmation of the diagnosis may also be considered to be a disadvantage. The obvious advantages of open surgery include the opportunity to conduct electrocorticography and functional mapping, direct visualization of target structures, and immediate efficacy. The risks involved in open surgery have been mentioned above.

Regarding the irradiation dose, a marginal dose of 24 ± 1 Gy appears more effective than using lower doses (15–24 Gy) (Régis *et al.* 2004; Kawai *et al.* 2001). Studies concerning antiseizure efficacy and the rate of complications have yielded extremely diverse results. We previously reported that in our patient group seizure outcome was worse than reported by other authors, early complications with the occurrence of intracranial hypertension lead to the need for corticosteroid treatment (Vojtěch *et al.* 2009) and late morphological changes require life-long follow-up by MRI (Kawamura *et al.* 2012; Vojtěch 2015).

GKRS has the potential benefit of treating target structures selectively without injury to the surrounding cortical regions and white matter tracts. It also has been suggested that it may produce less cognitive decline than standard surgery in patients with MTLE (Mathon *et al.* 2015). If this were true it would be a strong reason to promote this treatment modality. The aim of this study is to assess cognitive performance during the long-term follow-up of patients treated by GKRS for MTLE and after reoperation due to insufficient seizure control. The article would only be of historical interest if clinical trials of the use of GKRS for this indication had not been encouraged and planned (Kondziolka 2012).

MATERIAL AND METHODS

Patient group

Between November 1995 and May 1999, we diagnosed 14 patients with MTLE caused by hippocampal sclerosis and treated them using GKRS (Table 1). We described our group's characteristics, the presurgical evaluation protocol, and seizure outcome in our previous article (Vojtěch *et al.* 2009). To briefly recapitulate, there were eight female and six male patients, in whom epilepsy began at a mean age of 10.9 years (2.5–38 years) and whose mean age at the time of treatment was 33.4 years. By the time GKRS was performed, the patients had had epilepsy for an average of 23.2 years (9–46). Early risk factors were present in 12 patients. These were mostly febrile seizures; one patient (Patient 1) had a history of

purulent meningitis and the other patient (Patient 6) had experienced repeated afebrile generalized seizures since an early age. All the patients had complex partial seizures (CPS), and auras appeared either independently or at the beginning of the seizure in six of them. CPS occasionally led to secondary generalization in four patients.

Each patient underwent a routine presurgical examination [neurologic and neuropsychological testing, repeated interictal electroencephalography (EEG), scalp video-EEG study with ictal recording, MRI and intracarotid Amytal test]. The MRI study included a T1-weighted three-dimensional acquisition, a tilted coronary T2-weighted acquisition with a long second echo, and fluid-attenuated inversion-recovery sequences.

In addition to a standard scalp 10–20 electrode system, sphenoidal electrodes were used for the interictal video-EEG evaluation in two patients (Patients 1, 2). Foramen ovale electrodes for ictal recording were inserted in seven patients (Patients 2, 4–9). In one patient (Patient 9) non-invasive data were inconclusive and an invasive study was performed with a combination of strip and depth electrodes. A similar electrode combination was also used in Patient 1, as temporal lobe atrophy found on MRI did not exclude neocortical temporal lobe epilepsy.

Unilateral MTLE was diagnosed in all patients.

After completion of the preoperative evaluation, therapeutic options (AMTR or GKRS) were suggested

Tab. 1. Group's characteristics and seizure outcome.

Case	SR (m/y)	Volume (mm ³)	Dose (Gy)	Treated side (R/L)	ES/40	Surgery	ES/BO	ES/LV	FU	FU/BO	FU/AO
1	XI/95	8,900	20	R	IIA	None	N/A	IIIA	236	N/A	N/A
2	VI/96	7,700	25	L	IIIA	XII/13	IIIA	IA	229	210	19
3	XII/96	7,300	20	R	IVB	II/03	IVB	IA	223	74	149
4	II/97	6,700	25	R	IVB	V/01,	IVB	IA	221	51	170
5	II/97	7,400	25	L	IIIA	None	N/A	IIB	221	N/A	N/A
6	II/97	7,600	25	L	IIIA	X/13	IVB	IA	221	200	21
7	IX/97	7,600	25	L	IIIA	VI/06	IVB	ID	214	105	109
8	XI/97	6,600	25	R	IVC	III/01	IIIA	IA	212	40	172
9	IV/98	5,200	18	L	IVB	VI/07	IVB	IIC	207	110	97
10	XI/98	5,900	18	R	IVB	None	N/A	IVB	200	N/A	N/A
11	XI/98	5,700	18	L	IVB	None	N/A	IVB	200	N/A	N/A
12	XII/98	6,000	18	L	IIIA	XI/05	IVC	IA	199	81	118
13	V/99	6,100	18	L	IIIA	VI/04	IVA	IIC	194	61	133
14	V/99	6,000	18	L	IIIA	None	N/A	IB	194	N/A	N/A

Abbreviations: ES/40, Engel Class at 40 months after GKRS; ES/BO, Engel Class before operation; ES/LV, Engel Class at last visit; FU, total length of follow-up in months; FU/AO, length of follow-up after operation in months; FU/BO, length of follow-up before operation in months; N/A, not applicable; SR (m/y), month/year of GKRS; surgery, month/year of open surgery;

Note: Patient 4 died in XII/12 from influenza.

to the patients, who then chose one of them. All subjects received full and detailed information and gave their informed consent. The GKRS technique in the treatment of MTLE was approved by the local Ethics Committee.

Radiosurgical parameters

The patients underwent GKRS targeted to the medial temporal lobe (to the amygdala, sparing the superior and mesial part, to the head and anterior half of the body of hippocampus, and to the anterior part of the parahippocampal gyrus) (Table 1). Five patients were treated on the right and 9 patients on the left side. The radiosurgical parameters for six of our patients (Patients 2, 4–8) were the same as those described by Régis *et al.* (Régis *et al.* 1995, Régis *et al.* 2004). Prominent radiation-induced responses led us to reduce the dose and volume in Patients 3 and 9–14. The mean irradiated volume for the whole group was 6.764 mm³. In patients treated with 18–20 Gy, it was 6.388 mm³ on average (ranging from 5.200 to 8.900), whereas in those irradiated with 25 Gy, the average volume was 7.267 mm³ (6.600–7.700).

Neuropsychological testing

This study was approved by the hospital Ethics Committee. We reviewed cognitive performance in both operated and unoperated patients. We compared Memory Quotients (MQ) (Wechsler Memory Scale-Revised-WMS/WMS-R) and Intelligence Quotients (IQ) (Wechsler Adult Intelligence Scale-Revised-WAIS-R) before and after interventions (Wechsler 1945, 1981, 1987). Patients were tested in two sessions, each lasting 60–90 minutes. On the first day a neuropsychological interview was performed and the complete WAIS-R was presented (Wechsler 1987). On the second day memory functions were assessed using WMS/WMS-R.

Statistics

The results were analyzed using *Statistica v10*. Data are summarized using mean and SD. The changes between pre-/post-GKRS and pre-/postoperative neuropsychological results were evaluated using paired T-tests. Reported *p*-values were not corrected for multiple comparisons.

RESULTS

Seizure outcome

Mean follow-up in the whole group was 212.2 months (median 213, range 194–236). At the time our first patients underwent AMTR (40 months) 1 patient was Engel IIA, seven were IIIA, five were IVB and one Engel IVC.

We offered all our patients the option of open surgery and five of them refused. In the remaining nine patients, an AMTR was performed on the side treated by radiosurgery because of insufficient seizure control. No surgery was indicated for any of the patients for either early or late complications.

Of the five unoperated patients, one was Engel Class IB, one IIB, one IIIA, and two IVB at their last visit. They were followed-up for mean 210.2 months (median 200, range 194–236).

Of nine operated patients, two were Engel IIIA, one was IVA, 5 were IVB and one Engel IVC before the operation. They were followed-up for mean 103.6 months (median 81, range 40–210) before the operation and for mean 109.8 months (median 118, range 19–133) after the operation. At their last visit, they had become Engel Class IA in five cases, one patient was ID and two IIC. In one patient (Patient 2) the follow-up was not sufficiently long (19 months) to justify classification (he would be Engel IB). There was one death unrelated to epilepsy as a seizure-free patient (Patient 4) died from influenza 127 months after AMTR.

Neuropsychological outcomes

Pre-/post GKRS and pre-/post AMTR neuropsychological results and the mean change in the groups of treated patients for memory (WMS/WMS-R) and intelligence (WAIS-R) are summarized in Table 2. Neuropsychological data were not available for all patients, so the numbers of patients in certain groups differ from numbers of patient actually treated. These numbers are given in Table 2.

Figure 1 and Figure 2 only display differences in full scale FS-IQ and global MQ in those patients for whom neuropsychological data were available pre/post GKRS and pre/postAMTR, respectively.

We found a slight statistically nonsignificant decline in intelligence and memory quotients one year after GKRS. Attention/concentration worsened by more than –17 points (*p*=0.03). Two years after GKRS there were no significant changes in any of the quotients (Figure 1).

Overall cognitive performance improved in 8 operated patients. After surgery, we found a significant increase in Global and Visual MQ, mean change was 9.3 and 15.3 points (*p*<0.05), respectively (Figure 2). This figure shows clear memory improvement after the operation. There were no statistically significant changes in verbal memory and intelligence performance after AMTR.

DISCUSSION

Memory preservation and even improvement after MTLE surgery is not an unrealistic goal. Postoperatively, gains in verbal episodic memory were described after right temporal lobe surgery, and visual episodic memory improvement after left temporal lobe surgery (Baxendale *et al.* 2008). Verbal memory may even improve in about 9% of patients after left-sided AMTR.

There are several ways to preserve (and potentially improve) cognitive functions after MTLE surgery.

Destroy the mesiotemporal structures incompletely, preferentially targeting routes of seizure spread. These approaches have been suggested in descriptions of

Tab. 2. WMS/WMS-R and WAIS-R Scores in the group of patients.

	before GKRS (SD)	diff 0-1 y	p-value	diff 0-2 y	p-value	before AMTR mean (SD)	Diff 0-1 y after AMTR	p-value
Memory WMS/WMS-R	n=13	n=12		n=9		n=8	n=8	
Global MQ	83 (15)	4.5	0.39	4.2	0.46	82 (12.6)	-9.3	0.02
Verbal MQ	86 (12,5)	7	0.47	5	0.64	82 (8.8)	-4,1	0.07
Visual MQ	85 (10,8)	10	0.37	-1.5	0.9	91 (13.4)	-15.3	0.01
Attention/Concentration	86 (10,1)	17	0.03	18.5	0.11	71 (13.6)	2.1	0.64
Delayed Recall	83 (12.4)	7.8	0.42	-2.3	0.75	82 (11.3)	-6.3	0.14
Intelligence WAIS-R	n=13	n=12		n=9		n=10	n=8	
Full-Scale IQ	86 (7.5)	1.2	0.42	1.3	0.51	89 (10.5)	0.5	0.76
Verbal IQ	87 (8.8)	2	0.12	-0.2	0.89	89 (11.1)	1.8	0.28
Performance IQ	87 (10.5)	0	1	3.4	0.31	91 (12.3)	-1.5	0.51

Note: Statistically significant values are marked with bold print. Positive values represent a lower score after the interventions.

Abbreviations: diff, difference; y, year

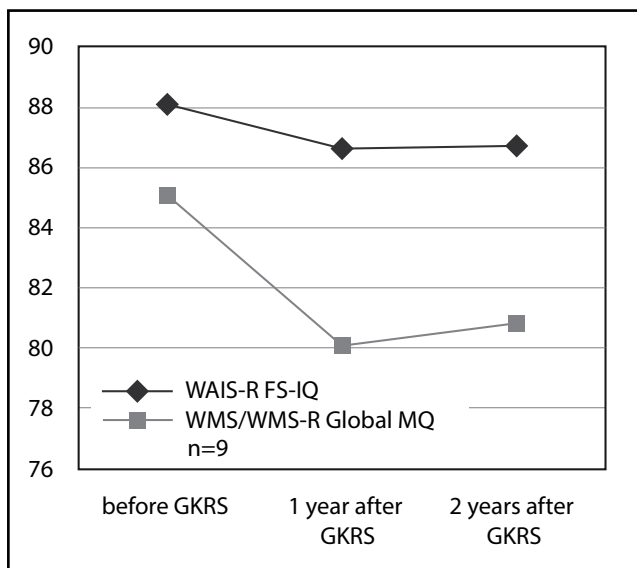


Fig. 1: Development of FS-IQ and global MQ after GKRS in nine patients for whom data were available both before and after GKRS.

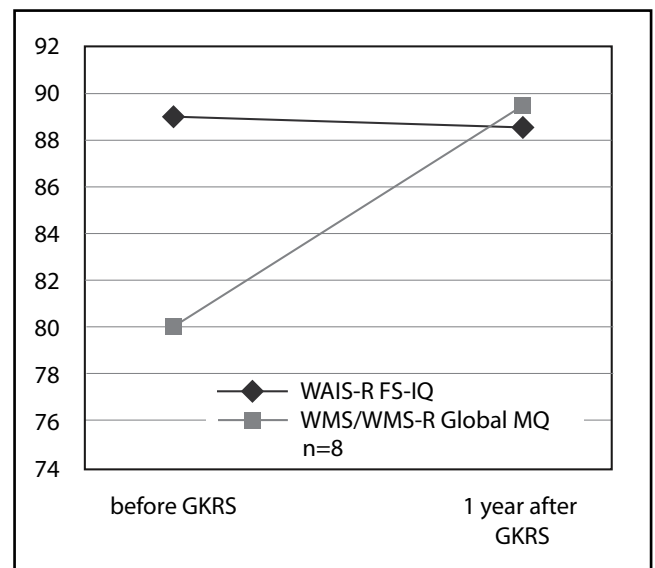


Fig. 2: The same changes prior to and after AMTR in patients for whom data were available both before and after the operation (n=8).

multiple hippocampal transection (Patil & Andrews 2013) and stereotactic amygdalohippocampectomy methods (Vojtěch *et al.* 2015). As better verbal memory is reported after surgeries with larger residual hippocampal volumes (Skirrow *et al.* 2015) the next argument for possible memory preservation after GKRS is the incomplete destruction of the target structures (especially on the left) and smaller resection volumes, e.g. sparing the posterior hippocampus. GKRS is not a neuromodulatory treatment and may only work in necrotic doses. Nonetheless, the destruction of mesial temporal structures is incomplete and viable neurons have been found in specimens obtained after subsequent resection (Vojtěch *et al.* 2015). However, it is debatable to what extent the remaining neurons could support memory.

Completely destroy target structures and preserve other regions important for cognitive functions (e.g. the temporal neocortex, connections to the frontal lobe). This is the mechanism behind such procedures as SAH, stereotactic amygdalohippocampectomy and laser ablation (Willie *et al.* 2014). This approach respects the fact that postoperative memory decline can occur even in patients with dominant temporal lobe epilepsy in whom hippocampus was spared (Wagner *et al.* 2013). Early post-GKRS complications with signs of intracranial hypertension and temporal neocortical structure involvement do not suggest that GKRS is any more sparing of the extramesiotemporal structures than open surgery (Vojtěch 2015) and point to extramesiotemporal lesions after GKRS.

Render the patient seizure-free. Poor postoperative seizure control has been suggested as a risk factor for material specific memory decline in both dominant and non-dominant AMTR (Dulay *et al.* 2009a; Sanyal *et al.* 2005). Other authors report that this decline is independent of seizure outcome (Andersson-Roswall *et al.* 2010). However, our patients were not seizure-free after the procedure.

As there was a nonsignificant worsening of memory functions in our group of patients after the procedure, we do not think any of these mechanisms work in GKRS. As this worsening was transient and we could not identify it two years after the procedure, it was most likely caused by persisting radiation-induced changes early after GKRS.

Neuropsychological outcome data following GKRS for MTLE are scarce. In a prospective multicenter study (Barbaro *et al.* 2009), the prevalence of verbal memory impairment was 15% (4/26 patients). Of the 12 patients treated in the language dominant temporal lobe, 3 (25%) experienced a significant decline in one measure of verbal memory, and 2 (16%) significantly improved in one measure. After recalculating their results in a subsequent study of the same patient group the authors found no overall decreases in verbal memory for the patients treated in the dominant temporal lobe (Quigg *et al.* 2011). However, they only reported the Delayed Recall Score of the Logical Memory subtest from the WMS-R (Wechsler 1987). The authors admit that patients treated with high dose GKRS in the dominant temporal lobe showed deterioration of some (non-contextual) aspects of verbal memory. In a low-dose subgroup they found no verbal memory impairment. As only 58.8% (10/17) of patients in the lower-dose group were seizure-free, these results mean that preservation of memory function in this group was counterbalanced by seizure outcome inferior to open surgery. Patients who underwent GKRS of the nondominant temporal lobe did not demonstrate any apparent decline in cognition after GKRS. The authors conclude that GKRS may not be inferior to open surgery from a neuropsychological point of view.

A small case series found no group changes at six months follow-up, although some individuals showed a decline in at least one cognitive domain (Srikijvilaikul, *et al.* 2004). McDonald *et al.* focused on cognitive outcomes on three patients. After dominant GKRS, they found no consistent changes in cognition (McDonald, *et al.* 2004). Each patient, however, showed deterioration of at least one measure of verbal memory (long delayed verbal memory). No patient declined when IQ, visual memory, or language were measured. Radiation-induced edema was present at the time all three patients were tested, which may have affected verbal memory performance. These data suggest that GKRS produces neuropsychological changes similar to those produced by left AMTR up to 2 years post-GKRS treatment. A potential confounder of these studies was that the

GKRS dose of 20 Gy used may be too small for effective seizure treatment (Barbaro *et al.* 2009; Barbaro & Quigg 2008) and the neuropsychological follow-up period may have been too short for the development of a definitive radiosurgical lesion (Barbaro *et al.* 2009, Regis, *et al.* 2004).

Poor results have also been reported after linear accelerator based stereotactic radiotherapy for MTLE (Liang *et al.* 2010). In a small group of 7 patients no patient was seizure-free (2 deteriorated) and 2 cases showed a drop in IQ, memory decline and permanent neurologic complications. The obvious shortcoming of this report is the difference in the treatment technique.

After unsuccessful temporal lobe resection, subsequent reoperation could lead to seizure freedom in approximately 70% of selected patients (Grote *et al.* 2015), especially in cases with incomplete resection of the epileptogenic zone (Zachenhofer *et al.* 2011). Neuropsychological losses after first surgery more often improve than decline after the reoperation. Likewise, if GKRS has failed, reoperation may be a reasonable option.

In our group of patients originally treated with GKRS, subsequent AMTR performed for poor seizure outcome lead to an Engel I or II outcome in all patients. After the operation we found slight but significant improvement in Global and Visual MQ. There were no statistically significant changes in verbal memory and intelligence performance after surgery. As most of our patients were treated on language-dominant side, we (quite understandably) found an improvement in functions of unoperated temporal lobe. It could be hypothesized that these results are a consequence of better seizure control after the operation. Yet, we interpret these results conservatively as an absence of cognitive worsening after AMTR following GKRS. They may result from a practice effect due to repeated administration of the same tests. Furthermore, as AMTR represents more complete lesion of target structures than GKRS, our results do not support the view that incomplete lesion of mesiotemporal structures by GKRS could cause better neuropsychological results after the procedure.

We are aware of the many weaknesses of this work. It is a single-center experience with a small group of patients and it does not include a control group. However, in this study the operated patients themselves act as selfcontrols. Historically, GKRS was used in a limited number of institutions. Therefore, long-term follow-up results are limited and thus valuable. Because of the small number of treated patients we did not stratify our patients according to the laterality of epileptic foci, dose of radiation and treated volume. The number of patients in these groups would be too small to enable us to reach any conclusion. Patient selection is certainly a bias as more patients were treated on their left (language dominant) side. It may mirror our former conviction that GKRS is a less invasive alternative to open surgery

which we may subconsciously transfer to our patients, thereby affecting their decision as to the choice of treatment modality.

CONCLUSIONS

GKRS with 25, 20, or 18-Gy marginal dose levels did not lead to cognitive changes (except in the Attention/concentration domain) but neither did it lead to sufficient seizure control. Subsequent epilepsy surgery could stop seizures and also lead to better memory performance. As MTLE is a surgically treatable condition with a high success rate, the risk of adverse events and inferior rate of seizure control of GKRS suggest that GKRS is not an alternative to conventional surgery. This fact is corroborated by our finding that neuropsychological results after GKRS may be inferior to open surgery. Our aim is to warn the epileptological community against the use of an experimental method for the diagnosis in which other treatment options are safe and effective.

ACKNOWLEDGEMENT

The work was supported by Ministry of Health, Czech Republic – conceptual development of research organization (Nemocnice Na Homolce – NNH, 00023884; IG 154301). We are indebted to Mrs. Carey Vosecká, MA, LLB for help with language editing.

REFERENCES

- Andersson-Roswall L, Engman E, Samuelsson H, Malmgren K (2010). Cognitive outcome 10 years after temporal lobe epilepsy surgery: a prospective controlled study. *Neurology*. **74**: 1977–1985.
- Barbaro NM, Quigg M (2009). Epilepsy – radiosurgery for epilepsy. *Rev Neurol Dis*. **6**: 39.
- Barbaro NM, Quigg M, Broshek DK, Ward MM, Lamborn KR, Laxer KD *et al.* (2009) A multicenter, prospective pilot study of gamma knife radiosurgery for mesial temporal lobe epilepsy: seizure response, adverse events, and verbal memory. *Ann Neurol*. **65**: 167–175.
- Bartolomei F, Hayashi M, Tamura M, Ray M, Fischer C, Chauvel P, *et al.* (2008). Longterm efficacy of gamma knife radiosurgery in mesial temporal lobe epilepsy. *Neurology*. **70**: 1658–1663.
- Baxendale S, Thompson PJ, Duncan JS (2008). Improvements in memory function following anterior temporal lobe resection for epilepsy. *Neurology*. **71**: 1319–1325.
- Chang EF, Quigg M, Oh MC, Dillon WP, Ward MM, Laxer KD *et al.* (2010). Predictors of efficacy after stereotactic radiosurgery for medial temporal lobe epilepsy. *Neurology*. **74**: 165–172.
- Cross JH, Duchowny M (2014). Transition in lesional focal epilepsy, and following epilepsy surgery. *Epilepsia*. **55** Suppl 3: 34–36.
- Dulay MF, Levin HS, York MK, Mizrahi EM, Verma A, Goldsmith I *et al.* (2009a). Predictors of individual visual memory decline after unilateral anterior temporal lobe resection. *Neurology*. **72**: 1837–1842.
- Dulay MF, Levin HS, York MK, Li X, Mizrahi EM, Goldsmith I, Verma A, Goldman A, Grossman RG, Yoshor D (2009b). Changes in individual and group spatial and verbal learning characteristics after anterior temporal lobectomy. *Epilepsia*. **50**: 1385–1395.
- Engel J Jr, McDermott MP, Wiebe S, Langfitt JT, Stern JM, Dewar S *et al.* (2012). Early surgical therapy for drug-resistant temporal lobe epilepsy: a randomized trial. *JAMA*. **307**: 922–930.
- Georgiadis I, Kapsalaki EZ, Fountas KN (2013). Temporal lobe resective surgery for medically intractable epilepsy: a review of complications and side effects. *Epilepsy Res Treat*. **2013**: 752195.
- Grote A, Witt JA, Surges R, von Lehe M, Pieper M, Elger CE *et al.* (2015). A second chance-reoperation in patients with failed surgery for intractable epilepsy: long-term outcome, neuropsychology and complications. *J Neurol Neurosurg Psychiatry*. 2015 Apr 8. pii: jnnp-2015-310322. doi: 10.1136/jnnp-2015-310322. [Epub ahead of print]
- Hamberger MJ, Drake EB (2006). Cognitive functioning following epilepsy surgery. *Curr Neurol Neurosci Rep*. **6**: 319–326.
- Helmstaedter C (2013). Cognitive outcomes of different surgical approaches in temporal lobe epilepsy. *Epileptic Disord*. **15**: 221–239.
- Helmstaedter C, Petzold I, Bien CG (2011). The cognitive consequence of resecting nonlesional tissues in epilepsy surgery—results from MRI- and histopathology-negative patients with temporal lobe epilepsy. *Epilepsia*. **52**: 1402–1408.
- Hoggard N, Wilkinson ID, Griffiths PD, Vaughan P, Kemeny AA, Rowe JG (2008). The clinical course after stereotactic radiosurgical amygdalohippocampectomy with neuro-radiological correlates. *Neurosurgery*. **62**: 336–44; discussion 344–346.
- Kawai K, Suzuki I, Kurita H, Shin M, Arai N, Kirino T (2001). Failure of low-dose radiosurgery to control temporal lobe epilepsy. *Journal of Neurosurgery*. **95**: 883–887.
- Kawamura T, Onishi H, Kohda Y, Hirose G (2012). Serious adverse effects of gamma knife radiosurgery for mesial temporal lobe epilepsy. *Neurol Med Chir (Tokyo)*. **52**: 892–898.
- Kondziolka D (2012). Epilepsy and radiosurgery. *J Neurosurg*. **116**: 1219; discussion 1220.
- Leksell L (1951). The stereotaxic method and radiosurgery of the brain. *Acta Chir Scand*. **102**: 316–319.
- Liang S, Liu T, Li A, Zhao M, Yu X, Qh O (2010). Long-term follow up of very low-dose LINAC based stereotactic radiotherapy in temporal lobe epilepsy. *Epilepsy Res*. **90**: 60–67.
- Mathon B, Bédos-Ulvin L, Baulac M, Dupont S, Navarro V *et al.* (2015). Evolution of ideas and techniques, and future prospects in epilepsy surgery. *Rev Neurol (Paris)* **171**: 141–156.
- McDonald CR, Norman MA, Tecoma E, Alksne J, Iragui V (2004). Neuropsychological change following gamma knife surgery in patients with left temporal lobe epilepsy: a review of three cases. *Epilepsy Behav*. **5**: 949–957.
- Patil AA, Andrews R (2013). Long term follow-up after multiple hippocampal transection (MHT). *Seizure*. **22**: 731–734.
- Quigg M, Broshek DK, Barbaro NM, Ward MM, Laxer KD, Yan G *et al.* (2011). Neuropsychological outcomes after Gamma Knife radiosurgery for mesial temporal lobe epilepsy: a prospective multicenter study. *Epilepsia*. **52**: 909–916.
- Régis J (2013). Radiosurgery as neuromodulation therapy! *Acta Neurochir Suppl*. **116**: 121–126.
- Régis J, Peragui JC, Rey M, Samson Y, Levrier O, Porcheron D *et al.* (1995). First selective amygdalohippocampal radiosurgery for 'mesial temporal lobe epilepsy'. *Stereotact Funct Neurosurg*. **64** (Suppl 1): 193–201.
- Régis J, Rey M, Bartolomei F, Vladyka V, Liscak R, Schrottner O *et al.* (2004). Gamma knife surgery in mesial temporal lobe epilepsy: a prospective multicenter study. *Epilepsia* **45**: 504–515.
- Régis Y, Roberts DW (1999). Gamma Knife radiosurgery relative to microsurgery: epilepsy. *Stereotact Funct Neurosurg*. **72** (Suppl 1): 11–21.
- Sanyal SK, Chandra PS, Gupta S, Tripathi M, Singh VP, Jain S, *et al.* (2005). Memory and intelligence outcome following surgery for intractable temporal lobe epilepsy: relationship to seizure outcome and evaluation using a customized neuropsychological battery. *Epilepsy Behav*. **6**: 147–155.
- Sherman EM, Wiebe S, Fay-McClymont TB, Tellez-Zenteno J, Metcalfe A, Hernandez-Ronquillo L *et al.* (2011). Neuropsychological outcomes after epilepsy surgery: systematic review and pooled estimates. *Epilepsia*. **52**: 857–869.

- 32 Schramm J (2008). Temporal lobe epilepsy surgery and the quest for optimal extent of resection: a review. *Epilepsia*. **49**: 1296–1307.
- 33 Skirrow C, Cross JH, Harrison S, Cormack F, Harkness W, Coleman R *et al.* (2015). Temporal lobe surgery in childhood and neuroanatomical predictors of long-term declarative memory outcome. *Brain*. **138**: 80–93.
- 34 Srikijvilaikul T, Najm I, Foldvary-Schaefer N, Lineweaver T, Suh JH, Bingaman WE (2004). Failure of gamma knife radiosurgery for mesial temporal lobe epilepsy: report of five cases. *Neurosurgery*. **54**: 1395–1402; discussion 1402–4.
- 35 Vojtěch Z, Malíková H, Syrůček M, Krámská L, Šroubek J, Vladyka V *et al.* (2015). Morphological changes after radiosurgery for mesial temporal lobe epilepsy. *Acta Neurochir (Wien)*. **157**: 1783–91; discussion 1791–2.
- 36 Vojtěch Z, Malíková H, Krámská L, Liščák R, Vladyka V (2015). MRI-guided stereotactic amygdalohippocampectomy: a single center experience. *Neuropsychiatr Dis Treat*. **11**: 359–74.
- 37 Vojtech Z, Vladyka V, Kalina M, Nespor E, Seltenreichová K, Semnická J *et al.* (2009). The use of radiosurgery for the treatment of mesial temporal lobe epilepsy and long-term results. *Epilepsia*. **50**: 2061–2071.
- 38 Wagner K, Uhrek M, Horstmann S, Kadish NE, Wisniewski I, Mayer H *et al.* (2013). Memory outcome after hippocampus sparing resections in the temporal lobe. *J Neurol Neurosurg Psychiatry*. **84**: 630–636.
- 39 Wechsler D (1945). A standardized memory scale for clinical use. *J Psychol*. **19**: 87–95.
- 40 Wechsler D (1981). Wechsler Adult Intelligence Scale-Revised. New York: Psychological Corporation.
- 41 Wechsler D (1987). Manual for the Wechsler memory scale revised. San Antonio, Texas: The Psychological Corporation.
- 42 Wiebe S, Blume WT, Girvin JP, Eliasziw M; Effectiveness and Efficiency of Surgery for Temporal Lobe Epilepsy Study Group (2001). A randomized, controlled trial of surgery for temporal-lobe epilepsy. *N Engl J Med*. **345**: 311–318.
- 43 Willie JT, Laxpati NG, Drane DL, Gowda A, Appin C, Hao C *et al.* (2014). Real-time magnetic resonance-guided stereotactic laser amygdalohippocampotomy for mesial temporal lobe epilepsy. *Neurosurgery*. **74**: 569–584; discussion 584–5.
- 44 Yang I, NM, Barbaro N (2007). Advances in the radiosurgical treatment of epilepsy. *Epilepsy Curr*. **7**: 31–35.
- 45 York MK, Rettig GM, Grossman RG, Hamilton WJ, Armstrong DD, Levin HS *et al.* (2003) Mizrahi EM. Seizure control and cognitive outcome after temporal lobectomy: a comparison of classic Ammon's horn sclerosis, atypical mesial temporal sclerosis, and tumoral pathologies. *Epilepsia*. **44**: 387–398.
- 46 Zachenhofer I, Novak K, Baumgartner C, Prayer D, Czech T (2011). Reoperation after selective amygdalohippocampectomy: an MRI analysis of the extent of temporomesial resection in ten cases. *Acta Neurochir (Wien)*. **153**: 239–248.