

# Treatment of giant paraclinoid aneurysms. Own experience

Pawel P. Kolasa<sup>1</sup>, Zbigniew Kaurzel<sup>2</sup> & Andrzej Lewinski<sup>3</sup>

<sup>1</sup> Department of Neurosurgery,

<sup>2</sup> Department of Radiology, Copernicus Province Hospital in Lodz,

<sup>3</sup> Department of Endocrinology and Isotope Therapy, Medical University of Lodz, POLAND

*Correspondence to:* Dr. Pawel P. Kolasa  
Department of Neurosurgery, Copernicus Hospital in Lodz,  
93-513 Lodz, Pabianicka 62, POLAND  
TEL/FAX: +48 42 689 5341  
E-MAIL: pawelkolasa@poczta.fm

*Submitted:* May 03, 2004      *Accepted* June 14, 2004

*Key words:*      **giant aneurysms; paraclinoid aneurysms; endovascular treatment; surgery**

*Neuroendocrinol Lett 2004; 25(4):287-291 NEL250404A08 Copyright © Neuroendocrinology Letters www.nel.edu*

## Abstract

**OBJECTIVES:** The incidence of giant aneurysms in the paraclinoid section of the internal carotid artery (ICA) is low. They manifest their occurrence by subarachnoid haemorrhage and neurological and hormonal symptoms, resulting from compression on either the nervous structures or on the pituitary. The treatment of these aneurysms is a challenge for the surgeon, due to a difficult access, high operational risk and when the size of operated malformations is large.

**MATERIAL AND METHODS:** Between the years 1994 and 2001, twenty (20) patients with giant paraclinoid aneurysms of the carotid artery were submitted to: endovascular treatment – 7 patients and to microsurgery – 13 patients. The treatment, following the access to the aneurysm and consisting in short-time (temporary) endovascular occlusion of ICA, was applied in some cases, while trapping was the method of choice in other cases.

**RESULTS:** Good results of the endovascular treatment were obtained in 6 patients and, in one (1) case, satisfactory result was observed. Regarding the whole study group, hormonal symptoms (amenorrhoea) occurred in one case only. Four aneurysms were totally embolized, 1 – almost totally and 2 – partially. Recanalisation was observed in one case after 2 years.

In the surgical method, good and very good results were obtained in 10 patients and satisfactory results – in 3 patients.

**CONCLUSION:** Application of either the endovascular method or of the microsurgical method – or of both these methods – used individually in case of a given aneurysm, increases the chances for an effective occlusion with a lower operative risk.

## Introduction

Giant aneurysms stand for 12% of all aneurysms of cerebral vessels, while giant aneurysms in the paraclinoid section of the internal carotid artery (ICA) are very rarely observed. Their presence may be manifested by subarachnoid haem-

orrhage or by neurological, optic and hormonal symptoms, caused by the pressure of the aneurysmal sac on adjacent structures.

The treatment of giant aneurysms in the paraclinoid section of ICA – because of the size of the

aneurysmal sac and its localisation with regards to cranial nerves, the sella turcica (the pituitary) and bone structures (the anterior clinoid process of the sphenoid bone), is a challenge for the operating surgeon. However, much of the success of the treatment depends on the localisation of the aneurysmal sac with respect to ICA, as well as on the applied surgical technique. The surgical approach to the aneurysm, removal of a part of the sphenoid bone to gain approach to ICA and the aneurysmal neck, precise dissection of the aneurysmal sac with reduced brain retraction and the shortest time of possible temporary artery occlusion, as well as manoeuvres, consisting in aneurysmal sac volume reduction in order to decrease blood inflow into its lumen and lower the tension of its walls, are of great significance. An application of indirect methods – ligation of ICA and wrapping sac of aneurysm – do not fully protect the aneurysm against rupture or increase in size, while a direct endovascular or surgical intervention, providing an occlusion of the aneurysmal neck, seems to be an effective method for patient's protection against repeated haemorrhage [1].

The aim of the study was an evaluation of the endovascular method and of microsurgical method in the management of giant paraclinoid aneurysms.

#### *Patients included in the study*

During the years 1994–2001, 844 aneurysms of cerebral vessels were treated at the Department of Neurosurgery at the Copernicus Province Hospital in Lodz. In that material, 256 ICA aneurysms (30.3%) were diagnosed. Twenty (20) aneurysms, accounted to giant ones, were found in the paraclinoid section of ICA (2.4%). There were 17 females and 3 males among the patients, the age ranged from 18 to 67 years, with the mean age of the men:  $42.3 \pm 20.5$  years ( $\bar{x} \pm SE$ ) and of the women:  $51.3 \pm 14.0$  years. The aneurysms manifested their existence by subarachnoid hemorrhage – in 11 patients, by neurological symptoms – in 8 patients (paresis – 4 patients, blindness – 2 patients, dysfunction of oculomotor nerves – 1 patient and trigeminal neuralgia – 1 patient), and by hormonal symptoms (amenorrhoea) – in 1 female patient.

#### **Methods**

Patients with giant paraclinoid aneurysms, diagnosed as operationally difficult, were referred to endovascular treatment from various centres in Poland. Following angiography of cerebral vessels, endovascular treatment was routinely applied as the primary method of therapeutic management. In cases of wide aneurysmal neck and the probability of mass effect, surgical treatment was applied.

**Endovascular approach.** Under general anaesthesia, following preliminary angiography by Seldinger's method, performed from the approach *via* the femoral artery by an Angiorex (Toshiba) angiography device in the digital road mapping system, aneurysm embolization was performed, using a system of coaxial

catheters and tungsten or platinum coils in mechanical detachable system (MDS Balt Montmorency, France).

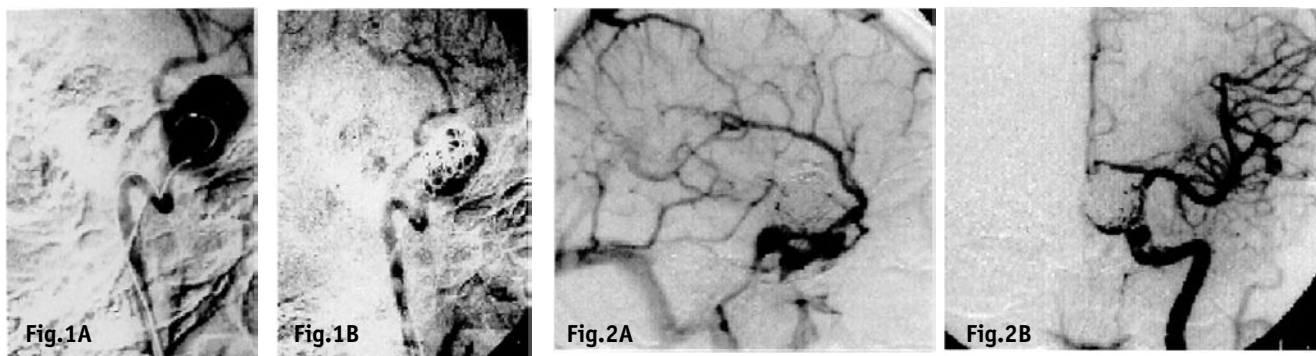
In that method, having reached the aneurysmal sac (of an aneurysm with a wide neck) with a catheter, it was important to insert the first and other coils in such a way that they made a basket-like structure with a dense network of coils at the aneurysm neck level, which would maintain the consecutively inserted coils on site. Such an approach decreased the probability of mass effect (Figures 1–2).

**Microsurgical approach.** The operations were performed from the approach via modified pterional (Yasargil's) craniotomy – the aneurysmal sac was dissected from the optic nerve and the anterior clinoid process of the sphenoid bone was removed, revealing, possibly the largest proximal part of the internal carotid artery. Then, the aneurysmal sac was dissected, maximally towards its neck. In case of aneurysms with upper localisation – suprasphenoid – a temporary clip was intracranially installed on the carotid artery. In other cases, temporary occlusion of ICA was used, effective by its direct closure with a Selverstone's clip or by balloon expansion, the balloon placed within the ICA lumen, close to or at the level of the aneurysm, the balloon inserted by femoral artery catheterisation by Seldinger's method. In cases of excessive retrograde blood flow, temporary clip trapping of the distal ICA fragment was applied, what allowed for a safe incision of the aneurysmal sac and decreasing its volume by removing its contents, i.e., blood and thrombus. Following the verification of the adjacent vessels and localisation of the aneurysmal neck, a clip – or clips – were mounted on it (Figures 3–4).

#### **Results**

**Endovascular method.** As a rule, no partial filling of the aneurysmal sac was applied as a preliminary step for neurosurgical operation. Seven patients (6 females and 1 male) were treated by the endovascular method. In 1 case, neurological symptoms were observed, which could have resulted from the mass effect. Total embolization included 4 aneurysms, almost total – 1 aneurysm, partial – 2 aneurysms. The obtained clinical results were evaluated in Glasgow Outcome Scale (GOS) [2]. The status of 6 patients was estimated as good (GOS score – 4 or 5), in 1 case the patient's status was severe (GOS – 2). Recanalisation appeared in one (1) case after 2 years, therefore, recoiling was performed, entirely closing the aneurysmal sac. In 3 cases, transient signs of focal neurological deficiency of ischaemic basis, observed after the operation, disappeared after about 6 months. In one (1) female patient with hormonal symptoms, amenorrhoea occurred; one (1) month after embolization – menstruation returned to normal without any pharmacological intervention.

**Surgical method.** Thirteen patients (11 females and 2 males) were qualified to surgical treatment immediately after performed angiography. Ten (10) good results (GOS 4 and 5) were obtained and, in 3 cases, the patient's status was assessed as moderate (GOS 3).



In 6 cases, transient hemiparesis was observed, probably resulting from the temporary ICA occlusion.

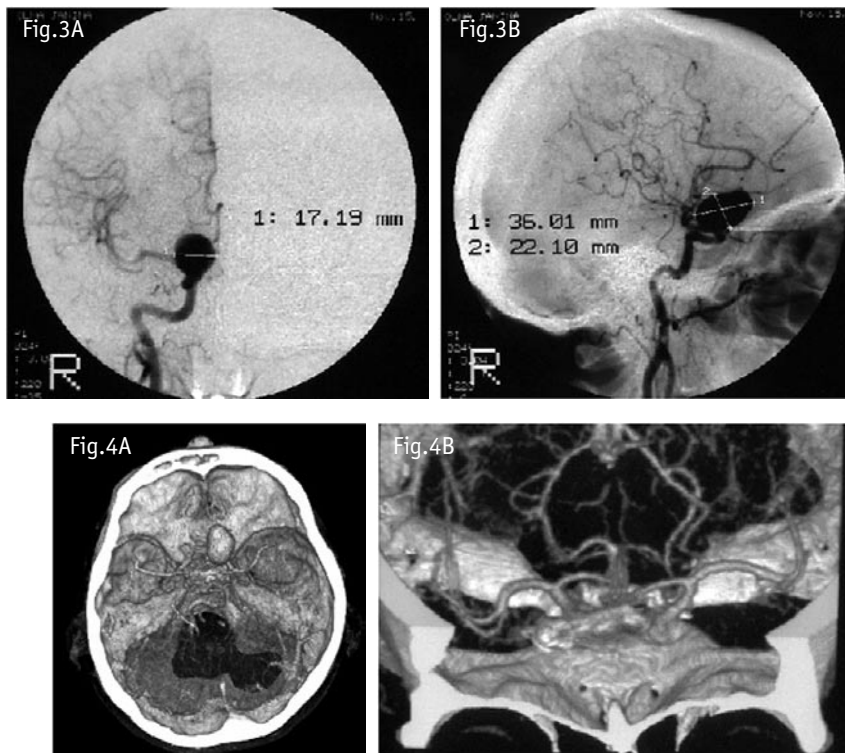
Apart from the aneurysm localisation and of its wide neck, organised clots and thickenings of the aneurysmal sac near its neck were significant obstacles during the surgical procedure, considerably impeding the quick localisation of the neck and proper and tight installation of the vascular clip. The elastic aneurysmal sac, with walls of equal thickness and loose clots, facilitated the decrease of its volume – by its incision and emptying of its contents – as well as allowed effective clipping or aneurysmoraphy (Tables 1–2).

### Discussion

The incidence rate of ICA aneurysms has been estimated for 30% of all cerebral aneurysms [4]. In the material from our Department, a similar incidence of ICA aneurysms was observed, i.e., about 30%. In comparison with other reported cases, concerning giant paraclinoid aneurysms, we observed in our material an increased number of those aneurysms (2.4%) [5]. We assume that it may have been associated with the preliminary qualification to endovascular treatment at our Department of those surgically challenging aneurysms by other centres in Poland.

In our material, the aneurysms manifested their presence mainly by subarachnoid haemorrhage (SAH) and optic symptoms, what is also confirmed by other authors [6, 7, 8, 9]. Hormonal symptoms were observed in the presented material in only one (1) case [8, 10]; they are also sporadically reported by other authors [5].

With the introduction of the endovascular method for cerebral an-



**Table 1.** Clinical results of treatment of giant paraclinoid aneurysms of the internal carotid artery, depending on applied treatment method (assessed in Glasgow Outcome Scale) [2]

Outcome – the clinical status GOS	Method of treatment	
	Surgical N	Endovascular N
5	5	4
4	5	2
3	3	
2		1
1		
Total	13	7

**Table 2.** The clinical outcome of treatment of giant paraclinoid aneurysms with regards to the baseline clinical status, assessed in Hunt-Hess's Scale [3] (H-H=0 – without SAH) (in Glasgow Outcome Scale).

H-H	GOS					Total
	5	4	3	2	1	
0	4	2				6
1	3	1				4
2		2				2
3	2	1	3			6
4		1		1		2
5						
Total	9	7	3	1		20

eurysm therapy, hopes have arisen for effective use of the method also for the treatment of giant aneurysms, including paraclinoid ones. It has turned out, however, that filling up of a giant aneurysm with coils may cause a still higher compression and induce further neurological deficiency signs. The occurrence of neurological deficiency signs in result of the, so-called, mass effect, caused certain limitations for unrestrained applications of this method in every giant aneurysm. It was found that an aneurysm, filled up with coils, became less elastic, causing permanent compression on sensitive structures in an anatomically tight location of the central nervous system (CNS) [11].

The wide aneurysmal neck, preventing appropriate fixation of coils, was another obstacle in the effective application of the method. The introduction of some methods to support the fixation of coils in the aneurysmal sac (remodelling with a balloon or 3D spirals) was not effective in some cases, either (due to a too wide aneurysmal neck) [8, 12].

Up to the year 1994, at our Department, indirect methods had been applied for aneurysm treatment in such location, including: ligation of the common or internal carotid artery or trapping. The methods are presently used but they do not protect the aneurysm against haemorrhage.

Since the year 1994, we have been using the endovascular treatment, being aware that proper diagnostics of an aneurysm, determining its morphological features, allows for an optimal choice of therapeutic method. It appears from our practice that such an evaluation, on the basis of monoplane angiography, is difficult, therefore, attempts of direct assessment were made in consideration of endovascular treatment application and, when that method failed, angiography was performed – allowing for a direct evaluation of the morphological features of the aneurysm (aneurysmography) and surgical treatment was applied.

Due to their close neighbourhood to sensitive structures, such as optic nerves, the optic chiasm, the oculomotor nerves of the orbital superior fissure, the pituitary and the bone structure, surrounding the cranial basis, paraclinoid aneurysms are difficult to be surgically approached. Additional problems are introduced by large and giant aneurysms.

In surgical treatment, the approach to the aneurysm is important via properly modified craniotomy. In the direct approach, the standard operative procedure was applied, generally accepted in the treatment of paraclinoid aneurysms and consisting in removal of the anterior clinoid process and decompression of the optic nerve canal, [1, 4, 5, 10, 11, 13]. The giant size of the aneurysm sac and the width of the aneurysmal neck did not allow for direct clipping of the aneurysmal neck, therefore, manipulations were attempted, consisting in aneurysmal sac reduction, e.g., by sucking out its contents with an aspirating nozzle [7, 11, 12, 14, 15].

In order to obtain higher surgical comfort and to decrease the risk of haemorrhage, microsurgical treatment was used with a temporary controlled oc-

clusion of the proximal ICA section. In our material of 11 cases, a direct approach was possible with removal of the anterior inclined process of the sphenoid bone and an application of a temporary clip on ICA. An unquestionable improvement was the application of a balloon (Balt), inserted through the femoral artery by Seldinger's method – expanding under control in the internal carotid artery near the aneurysm neck. In 2 cases, temporary occlusion of ICA-C1 and ICA-C2 was accomplished by a balloon, inserted into ICA via the femoral artery, and with application of trapping with clipping of the ICA in its section distal to the aneurysm. The time period of temporary ICA occlusion depended on anatomical conditions and technical skills of the operating surgeon, while the effects, such as pareses and neurological defects, were associated with the competence of collateral circulation from the contralateral ICA [11, 12, 15, 16].

In conclusion, the localisation of aneurysms in the paraclinoid section of the internal carotid artery within specific cranial basis structures makes the surgical approach rather difficult. The application of the endovascular technique allows for safer and easier treatment of small and medium size aneurysms in this localisation. The endovascular method reveals, however, certain limitations, when applied to giant aneurysms, because of the size of the aneurysmal sac (a risk of the occurrence of the, so-called, "mass effect", as well as for the wide aneurysmal neck (usually prevailing in giant aneurysms). In these cases, the microsurgical method is effective with the use of new surgical approaches and including the endovascular techniques of short-time parent artery occlusion or a direct occlusion of the aneurysmal neck. The application of the endovascular method or of the microsurgical method or of both these methods, used individually for a given aneurysm, increases the chances for effective occlusion with a lower operative risk [11, 12, 14, 15].

#### REFERENCES

- 1 Kaminogo M, Kitagawa N, Takahata H, Matsuo Y, Hayashi K, Yoshioka T, et al. Strategy for the treatment of inaccessible unruptured giant and large aneurysms of the internal carotid artery. *Neurol Res* 2001; **23**:388–396.
- 2 Teasdale G, Jannett B. Assessment of coma and impaired consciousness. A practical scale. *Lancet* 1974; **2**:81–84.
- 3 Hunt WE, Hess R.M. Surgical risk as related to time of intervention in the repair of intracranial aneurysms. *J Neurosurg* 1968; **28**:14–20.
- 4 Kattner KA, Bailes J, Fukushima T. Direct surgical management of large bulbous and giant aneurysms involving the paraclinoid segment of the internal carotid artery: report of 29 cases. *Surg Neurol* 1998; **49**:471–480.
- 5 Dolenc VV. A combined transorbital-transclinoid and transsylvian approach to carotid-ophthalmic aneurysms without retraction of the brain. *Acta Neurochir Suppl* 1999; **72**:89–97.
- 6 Dolenc VV. A combined epi- and subdural direct approach to carotid-ophthalmic artery aneurysms. *J Neurosurg* 1985; **62**: 667–672.
- 7 Heros RC, Nelson PB, Ojemann RG, Crowell RM, DeBrun G. Large and giant paraclinoid aneurysms: surgical techniques, complications and results. *Neurosurgery* 1983; **12**:153–163.

- 8 Kolasa P, Kaurzel Z, Lewinski A. Brak miesiaczki w wyniku olbrzymiego tetniaka o lokalizacji wewnątrzsiodłowej. [(Amenorrhoea as a result of gigantic aneurysm with intrasellar location.) (In Polish, with English abstract)]. *Endokrynol Pol – Polish J Endocrinol* 2002; **53**:401–406.
- 9 Tropinskaia OF, Serova NK, Lazarev VA. Neuro-ophthalmological symptoms in patients with para-clinoid aneurysms. *Vestn Oftalmol* 2002; **118**:24–28.
- 10 Gurian JH, Vinuela F, Guglielmi G, Gobin YP, Duckwiler GR. Endovascular embolization of superior hypophyseal artery aneurysms. *Neurosurgery* 1996; **39**:1150–1154.
- 11 Arnautovic KI, Al-Mefty O, Angtuaco E. A combined microsurgical skull-based and endovascular approach to giant and large paraclinoid aneurysms. *Surg Neurol* 1998; **50**:504–520.
- 12 Mericle RA, Wakhloo AK, Rodriguez R, Guterman LR, Hopkins LN. Temporary balloon protection as an adjunct to endosaccular coiling of wide-necked cerebral aneurysms: technical note. *Neurosurgery* 1997; **41**:975–978.
- 13 Batjer HH, Kopitnik TA, Giller CA, Samson DS. Surgery for paraclinoid carotid artery aneurysms. *J Neurosurg* 1994; **80**:650–658.
- 14 Fahlbusch R, Nimsky C, Huk W. Open surgery of giant paraclinoid aneurysms improved by intraoperative angiography and endovascular retrograde suction decompression. *Acta Neurochir* 1997; **139**:1026–1032.
- 15 Meyer FB, Friedman JA, Nichols DA, Windschitl WL. Surgical repair of clinoidal segment carotid artery aneurysms unsuitable for endovascular treatment. *Neurosurgery* 2001; **48**:476–485.
- 16 Ng PY, Huddle D, Gunel M, Awad IA. Intraoperative endovascular treatment as an adjunct to microsurgical clipping of paraclinoid aneurysms. *J Neurosurg* 2000; **93**:554–560.