

Coexisting acromegaly and primary empty sella syndrome

Zeliha Hekimsoy¹, Nilgün Yünter² & Seda Sivrioglu³

¹ Celal Bayar University Medical Faculty Department of Internal Medicine, Division of Endocrinology and Metabolism, Manisa, TURKEY.

² Ege University Medical Faculty, Department of Radiology, Izmir, TURKEY.

³ Izmir Atatürk Training and Research Hospital, Department of Internal Medicine, Izmir, TURKEY.

Correspondence to: Zeliha Hekimsoy, M.D.
259 sok. No 36/1, D. 3 (Özlu Apt.)
Hatay, Izmir
35360 TURKEY
TEL: +90-232-2441292
EMAIL: zhekimsoy@hotmail.com

Submitted: October 24, 2003 Accepted: April 24, 2004

Key words: **acromegaly; empty sella syndrome; octreotide; growth hormone; pituitary infarct**

Neuroendocrinol Lett 2004; 25(4):307-309 NEL250404AC1 Copyright © Neuroendocrinology Letters www.nel.edu

Abstract

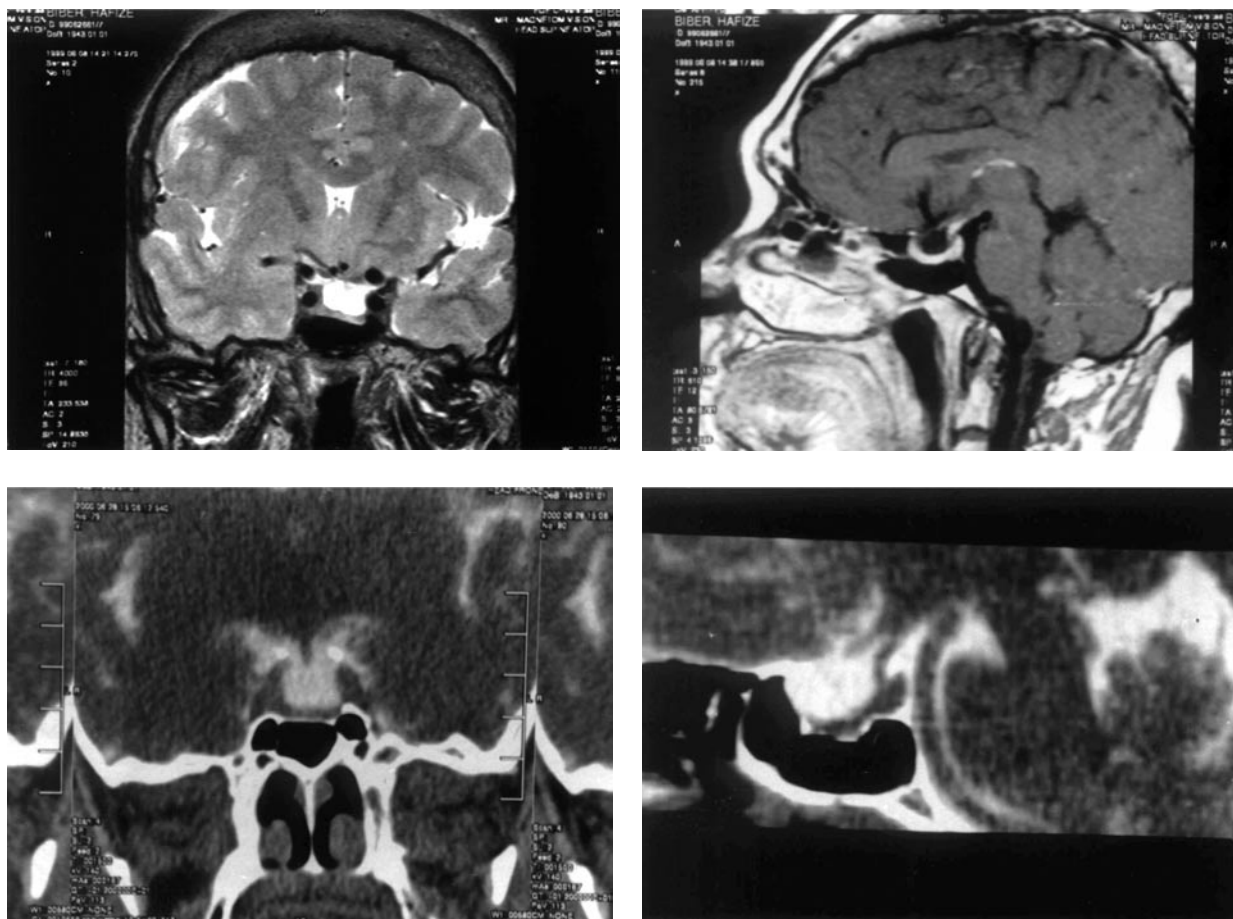
The normal functions of the pituitary gland may be suppressed when the gland is compressed onto the sella floor by arachnoid tissue extending through an impaired sella diaphragm. Interestingly, pituitary hormone hypo- and hypersecretion, including acromegaly, have been observed in patients with an 'empty sella' (1-4). This 'empty sella syndrome' has been classified into a primary form, in which no inciting factor (pituitary irradiation or surgery for a pituitary tumor) is present, and a secondary form, in which the empty sella occurs after pituitary procedures. In this report we describe a patient who presented with clinical and biochemical features of acromegaly and who had an empty sella on pituitary magnetic resonance imaging (MRI).

Case report

A fifty-eight year old female presented to our Division of Endocrinology for evaluation of a goiter. Her history was positive for hypertension. She had given birth to three children. On physical exam she had typical features of acromegaly: an enlarged tongue, hands and feet; a very large head, with oily and thickened skin, prominent supraorbital ridges, a broad nose, and prognathism. Her blood pressure was 170/110 mm Hg. The thyroid was palpable. There was no galactorrhea. Her visual acuity and visual fields were normal.

On more detailed questioning, she had noticed changes consistent with acromegaly for approximately 15 years. About 18 years previously, she remembered an episode of an extremely severe, generalized headache. To date, she had not received any treatment for acromegaly.

Baseline growth hormone (GH) was slightly elevated (5.4 µg/L; normal value: 0-5 µg/L) and there was a paradoxical elevation of GH to 7.1 µg/L during an oral glucose load (75 gm). Insulin-like growth factor-1 (IGF-1) level was elevated (523 ng/mL; normal value: 92-483 ng/mL). Estradiol (E₂), follicle-stimulating hormone (FSH) and luteinizing hormone (LH) levels were appropriate for a postmenopausal woman. Prolactin, corticotropin (ACTH), free triiodothyronine (fT₃), free tetraiodothyronine (fT₄) and cortisol levels were normal. Thyroid stimulating hormone (TSH) was low (0.01 µIU/mL;



The figures show a partial empty sella. On both MRI and CT cisternography images, a 2 mm-thick area of pituitary tissue is seen on the floor of the sella.

Figure 1a: T₂-weighted coronal MR image

Figure 1b: T₁-weighted post-contrast sagittal MR image

Figure 2a: CT cisternography: coronal image

Figure 2b: CT cisternography: sagittal image, by multiplanar reconstruction

normal value: 0.5–5.1 μ IU/mL). Complete blood count, liver and kidney function tests were also normal. The oral glucose tolerance test was abnormal, with a serum glucose of 165 mg/dL at 2 hours. No laboratory in our country is able to measure GH-releasing hormone levels.

Although chest X-ray and abdominal ultrasonography were normal, chest and abdominal CT scans were done to look for a possible GH or GH-releasing hormone producing tumour, but these were normal. Thyroid gland imaging revealed multiple solid nodules on ultrasound and multiple autonomous (suppressing the surrounding thyroid tissue) nodules on scintigraphy. Fine needle aspiration biopsy revealed a colloid goiter. Pituitary MRI (Figs. 1a and 1b) showed a partially empty sella. This was confirmed by CT cisternography with water-soluble contrast media (Figs. 2a and 2b). Dynamic MRI revealed no adenoma. Sellar MRI scan was performed using high resolution TSE T₂-weighted (TR: 5000, TE: 96, FA: 180), precontrast and postcontrast T₁-weighted (TR: 690, TE: 12, FA: 150) images. On CT cisternography, 2 mm slices were obtained for multiplanar reconstruction.

Because somatostatin analogues are known to both relieve symptoms and lower GH levels in acromegaly patients (5,6), we began the patient on a course of subcutaneous octreotide injections, 100 μ g three times daily. With this treatment she experienced marked clinical as well as biochemical improvement (serum postglucose GH and IGF-1 returned to normal: 0.9 μ g/L and 282 ng/dL, respectively). The patient is continuing to be treated with intramuscular injections of a long-acting octreotide (Sandostatin LAR®).

Discussion

Acromegaly is a rare pituitary disorder with an estimated incidence of three to four cases per million population per year (7). Acromegaly has occasionally been found in patients with an empty sella secondary to prior pituitary irradiation and/or surgery. Active acromegaly, on the other hand, has only rarely been found in patients with a primary empty sella (1–3). In a retrospective study of 76 patients with empty sella, Gallardo et. al. identified only three patients with acromegaly (4). Our patient did not meet commonly used criteria for removal of hypersecreting pituitary tissue:

incapacitating headache, very large arachnoidocoele with thinning or suspected erosion of the sellar floor, cerebrospinal fluid rhinorrhoea, damage to optic pathways, or suspected coexistence of a pituitary adenoma.

The two most commonly held hypotheses concerning the aetiology of the PES are: a) hydrodynamic transmission of cerebrospinal fluid pressure through a congenital defect in the diaphragm sella, and b) infarction of the pituitary contents (1–3). By our patient's history, we suspect that she may have had a pituitary infarct which caused her intense prolonged headache about three years before she began to notice signs of acromegaly.

This patient reminds us that patients without any prior pituitary procedures may present with a concomitant empty sella and symptoms and signs of active acromegaly. Our patient most likely had a pituitary infarct that resulted in an empty sella. This possible infarct did not totally ablate the hyperfunctioning tissue in this patient however, as demonstrated by elevated, nonsuppressible GH levels.

REFERENCES

- 1 Login I, Santen RJ. Empty sella syndrome. *Arch Intern Med* 1975; **135**:1519–21.
- 2 Molitch ME, Hieshima GB, Marcovitz S, Jackson IMD, Wolpert S. Coexisting primary empty sella syndrome and acromegaly. *Clin Endocrinol* 1977; **7**:261–3.
- 3 Bjerre P, Lindholm J, Videbek H. The spontaneous course of pituitary adenomas and occurrence of an empty sella in untreated acromegaly. *J Clin Endocrinol Metab* 1986; **63**:287–91.
- 4 Gallardo E, Schachter D, Caceres E, Becker P, Colin E, Martinez C, Henriquez C. The empty sella: results of treatment in 76 successive cases and high frequency of endocrine and neurological disturbances. *Clin Endocrinol* 1992; **37**:529–33.
- 5 Ezzat S, Snyder PJ, Young WF, Boyajy LD, Newman C, Klibanski A, et al. Octreotide treatment of acromegaly. *Ann Intern Med* 1992; **117**:711–8.
- 6 Lamberts SWJ, Van Der Lely AJ, DE Herder WW, Hofland LJ. Octreotide. *N Engl J Med* 1996; **334**:246–54.
- 7 Melmed S. Acromegaly. *N Engl J Med* 1990; **322**:966–77.