

# Precocious puberty with congenital hypothyroidism

<sup>1</sup>Abdelrahman M Radaideh, <sup>2\*</sup>Mohamad Nusier, <sup>3</sup>Zeyad El-Akawi & <sup>4</sup>Duried Jaradat

<sup>1</sup> Internist, Endocrinologist. Department of Internal Medicine. Princess Basma Teaching Hospital Ministry of Health. Irbid. Jordan.

<sup>2\*</sup> Associate Professor and Chairman,

<sup>3</sup> Assistant Professor. Department of Biochemistry and Molecular Biology. Jordan University of Science and Technology School of Medicine. Irbid, 22110. Jordan.

<sup>4</sup> Radiologist. Department of Radiology. Princess Basma Teaching Hospital Ministry of Health. Irbid. Jordan

*Correspondence to:* Mohamad Nusier, M.D., Ph.D.  
Department of Biochemistry and Molecular Biology  
Jordan University of Science and Technology, School of Medicine  
Irbid 22110, JORDAN  
FAX: +962 2 7095010  
EMAIL: [mick@just.edu.jo](mailto:mick@just.edu.jo)

*Submitted:* March 3, 2005

*Accepted:* April 10, 2005

*Key words:* **precocious; puberty; hypothyroidism; multicystic; ovaries; vaginal bleeding**

Neuroendocrinol Lett 2005; **26**(3):253-256 **PMID:** 15990731 NEL260305A10 © Neuroendocrinology Letters [www.nel.edu](http://www.nel.edu)

## Abstract

Precocious puberty associated with profound hypothyroidism is a rare condition. It is usually characterized by breast development, vaginal bleeding, lack of pubic hair and delayed bone age. Multicystic ovaries in profound hypothyroid patients with precocious puberty have been rarely described. Vaginal bleeding in adolescent girls should be considered as a clinical significance particularly when it is prolonged or heavy, whereas vaginal bleeding in younger girls, regardless of its duration and quantity is always of clinical importance. Bleeding in such patients could be caused by local causes such as vulvar or vaginal lesions, or it could be from the endometrium, which is usually a sign of systemic hormonal disturbance [1].

In this report a rare case of vaginal bleeding, large, multicystic ovaries, precocious puberty and delayed bone age in a 7 years old girl with profound hypothyroidism is described.

## Case Report

Seven years old female patient was referred by the Gynecological Department in Al Amirah Basma Teaching Hospital for endocrinological consultation because of a history of cyclic vaginal bleeding for the last 3 months. The bleeding lasts 3-4 days per cycle with small amount of blood loss. She was diagnosed as a case of ovarian mass and was planned for surgery. The patient did not have a history of convulsions, meningitis, encephalitis, head injury or hormonal therapy. She was born at term pregnancy without any

complications in a poor illiterate family. Her parents noticed that she had slow mental and physical development since birth compared with her brothers and sisters. There was no previous family history of similar condition.

On examination, patient looked lethargic, pale with coarse features and puffy face (Figure1). Her temperature was 36.8°C. Height was 98 cm (< 5<sup>th</sup> percentile), body weight was 18 kg (50-75<sup>th</sup> percentile). Her blood pressure was 95/55 mmHg, pulse was regular with a rate of 64/min. No thy-

roid and lymph node enlargement, heart and chest were normal. Her breast buds were developed as Tanner stage 2-3 (Figure 2), without galactorrhea or other external signs of sexual maturation. Abdomen was distended; no abnormal pelvic and abdominal masses were palpated. No pitting edema.

On genital examination no abnormalities were detected. There was an increase in body hair growth, mainly on her back. She was severely intolerant to cold.

Initial laboratory data showed: hemoglobin 11.4 g/dl, hematocrit 32.3%, white blood cell count 16.600/mm<sup>3</sup>. Platelets 350.000/mm<sup>3</sup>. MCV 89mm, MCH 31.3pg, RDW 11.4%, PT 14.4s, PTT 39.9, INR 0.99 (0.8-1.2). Fasting blood sugar, blood urea, nitrogen, creatinine, and electrolytes were normal, Ca<sup>++</sup> and PO<sub>4</sub><sup>+++</sup> were also normal. Cholesterol 12.1 mmol/l. Triglyceride 3.3 mmol/l. Alkaline phosphatase 200 u/l. SGOT 83 u/l. SGPT 51 u/l LDH 4.6 u/l. Creatinine phosphokinase 975 u/l. Urine analysis was normal.

Chest X-ray was normal. Bone age (Greulich and Pyle) was 30 months (Figure 3).

Pelvic ultrasound: Adult type uterus with the endometrial thickness about 1.5 mm and myometrium thickness about 5 mm. The uterus size was 5.5x2.5x3 cm. The cervical length was 2.5x1.5 cm. The right ovary measured about 2x1.3x3.4 cm. The left ovary measured about 3.2x3x3.4 cm. Both right and left ovaries were large and multicystic (Figure 4).

Abdominal CT scan showed enlargement of both ovaries with a mass in the right one.

Endocrinological evaluation revealed thyroxin (FT4) 0.4 ng/dl (normal 0.8-1.9), FT3 <1.0 pg/ml (normal 1.5-4.1). TSH (thyroid stimulating hormone) >75miu/ml (0.4-4.0). Antithyroperoxidase Antibodies (Anti-TPO-Abs) 132 iu/ml (<15). Antithyroglobulin antibodies 22 iu/ml (nd-40). Follicle stimulating hormone (FSH) 10.6 miu. Lutenising hormone (LH) 0.17miu. Prolactin 86.3 ng/ml (1.9-25 adult female).

Progesterone 0.34 miu/ml Total testosterone 57.0 (65-119 female).

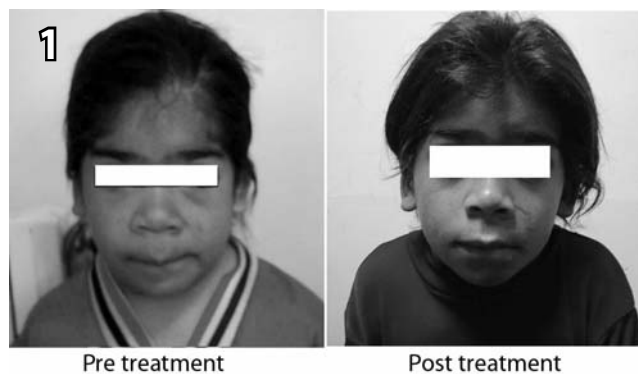


Figure 1. Pre and post treatment – patient's face

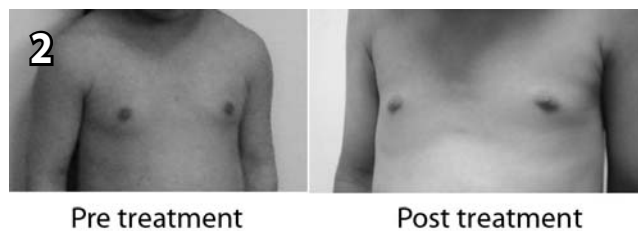


Figure 2. Pre and post treatment – patient's breasts

Thyroid ultra sound demonstrates small thyroid gland with right lobe 6x6x8 mm. Left lobe 7.5x6.5x5 mm with apparent homogenous echo pattern without focal lesions.

Technetium 99 thyroid scan revealed thyroid gland almost none visualized, no evidence of functioning ectopic thyroid tissue in the neck.

Pituitary MRI and Brain MRI: enlarged pituitary gland (puberty age size) 1.2x1.1x1.5 cm. Bilateral peritrigonal area of high signal intensity on T2 suggestive of encephalomalacia (Figure 5).

After the establishment of the diagnosis of congenital hypothyroidism and precocious puberty, L-thyroxine 50 mg once daily was given. Within few days after

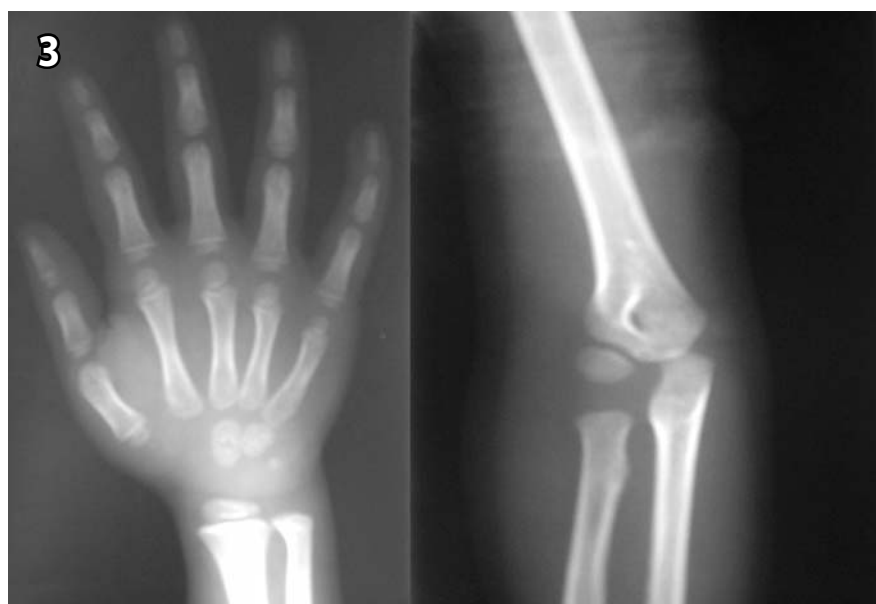
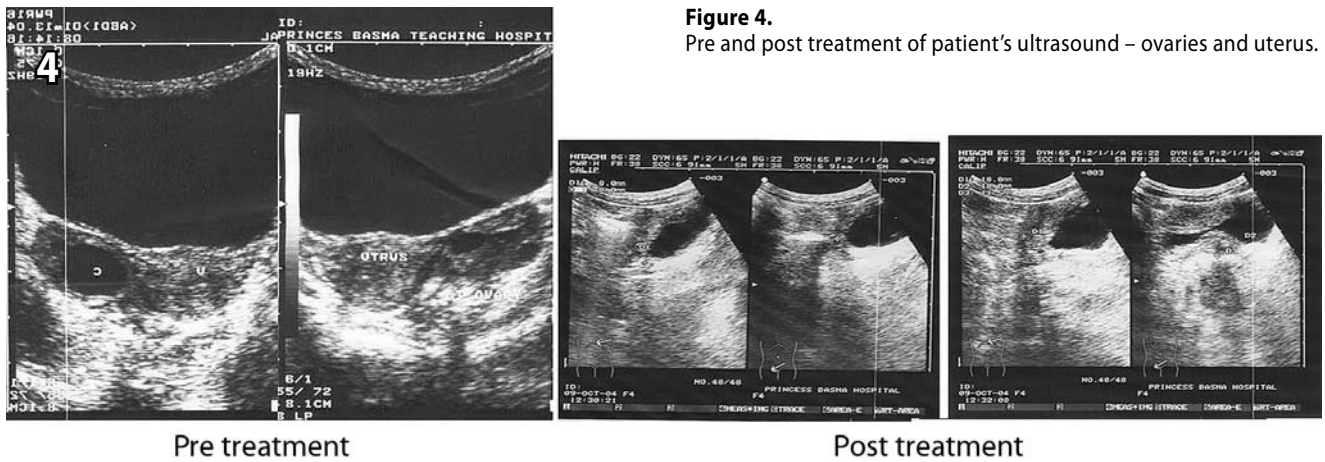
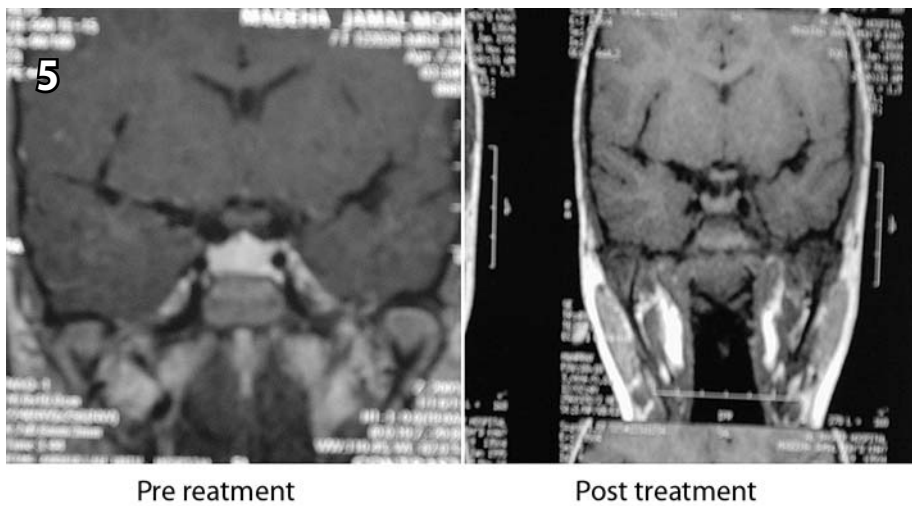


Figure 3. X-ray showing bone age (Greulich and Pyle)



**Figure 4.**  
Pre and post treatment of patient's ultrasound – ovaries and uterus.



**Figure 5.**  
Pre and post treatment – patient's Pituitary.

treatment vaginal bleeding was stopped. In addition the patient was improved both physically and mentally (Figure 1). Over the last 6 months of follow up the post treatment laboratory data showed: Cholesterol 4.6 mol/l. Triglyceride 2.0 mmol/l. CPK 185 iu/l. Alkaline phosphatase 756 u/l and normal SGOT and SGPT. Hb 12.4 HCT 39.4%, WBC 12.600/mm<sup>3</sup>. FT4 2.1 ng/dl. TSH 0.38 mIU/ml. FSH 2.2. LH 0.5 Progesterone 35.0. PRL 22.5 and testosterone <20.

Pelvic ultra sound revealed normal uterus and ovaries. Figure 4

Pituitary MRI revealed small pituitary gland. Figure 5

## Discussion

The cause of vaginal bleeding must be sought when bleeding occurs in young girl and clinical presentations may help in establishing the correct diagnosis. We report a typical case of vaginal bleeding that caused by hypothyroidism and its successful treatment with thyroxin replacement therapy. Findings of delayed bone age in girls with precocious puberty narrows the differential diagnosis to hypothyroidism because other causes of precocious puberty should have an advanced bone age [2]. Generally, children

with primary hypothyroidism present with delayed pubertal development and short stature [2].

This case presented with precocious pubertal development, short stature and delayed bone development. These findings are consistent with other reports [2,3,4,5,6]. However, in other reported cases, 6 isolated menarche occurred in hypothyroidism in the absence of breast development. Interestingly, important clinical presentations that were reported previously, and were detected in our case are bilateral ovarian enlargement with multiple cysts [2,7,8], hyperprolactinemia and increased levels of gonadotropins mainly follicle stimulating hormone [7,9,15].

Figure 5, demonstrated the magnetic resonance imaging (MRI) shows hypertrichosis and enlarged pituitary (puberty age size); such findings were also reported by other researchers [10,11,12].

A convincing explanation of sexual precocity and bilateral ovarian enlargement is that high levels of thyroid stimulating hormone (TSH) seen in profound hypothyroidism could act through the follicle stimulating hormone receptor (FSH-r) and cause gonadal stimulation [13]. This causes breast development, uterine bleeding, multicystic ovaries in girls [2,8,13] and macroorchidism without excessive virilization in boys [13,14]

Other mechanisms which may explain these manifestations are; an increased ovarian sensitivity to gonadotropines [16]. An increased aromatization of androstenedione to oestrone [17], and hypothalamic encephalopathy that impairs the normal tonic suppression of gonadotropine release by hypothalamus [18].

On the other hand, hyperprolactinemia reduces gonadotropine clearance and decreases dopaminergic and opioid tone at the hypothalamic pituitary axis [19,20]. Pituitary enlargement with long standing profound hypothyroidism results from prolonged and or target organ failure in the absence of the appropriate hormone replacement, the loss of negative feedback of hypothalamus and secondary hypertrophy or hyperplasia of the thyrotrophic cells in the anterior lobe of the pituitary gland [12].

The appropriate treatment of this case was thyroid hormone replacement which is consistent with other reports [2,3,4,5, 8,15].

Following thyroid hormone replacement therapy, bleeding ceased within few days. Multicystic ovaries completely resolved and breasts regressed after 6 months. Pituitary enlargement resolved within 6 months of thyroxin treatment. These treatment results are consistent with other reports [5,8,12,15].

## Conclusion

Where vaginal bleeding occurs in young girls, hypothyroidism should be considered especially when vaginal bleeding is accompanied with additional clinical presentations such as short stature, delayed bone age and multicystic ovaries. Thyroxin replacement therapy should lead to complete resolution of such disorder and promote normal physical and mental development of young girls.

## REFERENCES

- 1 Muram D. Vaginal Bleeding In Child Hood and Adolescence. *Obstet Gynecol Clin North Am* 1990; **17**:389-408.
- 2 Gordon C M, Austin DJ, Radovick S, Laufer M R. Primary Hypothyroidism Presenting As Severe Vaginal Bleeding In A Prepubertal Girl. *J Pediatric Adolesc Gynecol* 1997; **10**:35-38.
- 3 Barnes ND, Hayles AB, Rayan RJ. Sexual Maturation in Juvenile Hypothyroidism *Mayo clinic Proc* 1973; **48**:849-858.
- 4 Bahansali A, Kashyap A, Lodha S, Kotwal N, Ganapathi B, Mittal BR, Dash RJ. Isosexual Precocity: Uncommon Presentation Of A Common disorder. *Postgrad Med J* 2000; **76**:177-178
- 5 Dinesh Dhanwal, Nikhil Tandon. Isolated Menarche and Multicystic ovaries in 71/2 Girl with Hypothyroidism *Indian Pediatr* 2001; **38**:432-433.
- 6 Piziak VK, Hahn HB JR. Isolated Menarche in Juvenile Hypothyroidism. *Clin Pediatr* 1984; **23**:177-179.
- 7 C.H Chen, C. M, Tin, Y.H. Chon, W. Y-K. Chen, B. Hwang, D. M, Niu. Congenital Hypothyroidism with Multiple Ovarian Cyst. *Eur J Pediatr* 1999; **158**:851-852.
- 8 Lidsay AN, Vorrhes MI, Mac Gilliary Mh. Multicystic Ovaries Detected By Sonography in Children With Hypothyroidism. *Am J Dis Child* 1980; **139**:588-592.
- 9 Rakover Y, Weiner E, Shalev E, Luboshitsky R. Vaginal Bleeding Presenting Symptom of Acquired Primary Hypothyroidism in a Seven Year Old Girl. *J Pediatr Endocrinol* 1993; **6**:197-200.
- 10 Nishi Y, Hamamoto K, Kajiyama M, et al., Pituitary Enlargement, Hypertrichosis and Blunted Growth Hormone Secretion in Primary Hypothyroidism. *Acta Pediatr* 1989; **78**:136-140.
- 11 Atchison JA, Lee PA, Albright AL. Reversible Pituitary Mass Secondary to Hypothyroidism. *JAMA* 1989; **262**:3175-3177.
- 12 Meena P, Desai, MD, Rajiv V. Mehta, MD, Chandra S Choksi, MD, Maria Prisca Colaco, MD., Pituitary Enlargement on Magnetic Resonance Imaging in Congenital Hypothyroidism. *Arch Pediatr Adolesc Med.* 1996; **150**:623-628.
- 13 Anaski J N, Flack M R, Froehlich J, Nelson L M Nisuta BC 1995 A Potential Novel Mechanism for Precocious Puberty in Juvenile Hypothyroidism. *Clin Endocrinol Metab.* 1996; **80**:276-279
- 14 Bruder JA, Samnels MH, Bremner WJ, et. al., Hypothyroidism-Induced Macro-Orchidism: Use Of Gonadotropin-Releasing Hormone Agonist To Metab. 1995; **80**:11-16.
- 15 W Chemaitilly, C Thalassinou, S Emond, E Thibaud. Metrorrhagia and Precocious Puberty Revealing Primary Hypothyroidism in a Child with Down's syndrome. *Arch Dis Child* **2003**; **88**:330-331.
- 16 Mandl AM. Factors Influencing Ovarian Sensitivity To Gonadotropines. *J Endocrinol* 1957; **15**:448-457.
- 17 Adams WC, Senseman DM. Aromatization of Androstenedione by Induced Polycystic Ovaries in the Rat *J Steroid Biochem.* 1976; **7**:309-310.
- 18 Reichlin S. Neuroendocrinology. In: William's Textbook of Endocrinology. 19th edition Eds. Wilson J D, Foster D W, W.B. Saunders Company. 1998 p.165-248
- 19 Suter S N, Kaplan S L, Aubert M I. Plasma prolactin and thyrotropine and the response to thyrotropine releasing Factor in children with primary and tertiary hypothyroidism. *J Clin Endocrinol Metab.* 1978; **47**: 1015-1020
- 20 Thomas R, Reid R L. Thyroid disease and reproductive dysfunction a review. *Obstet Gynecol* 1987; **70**:789-798