

Adrenal cortex – the next biological clock?

Marek Pawlikowski

Department of Experimental Endocrinology and Hormone Diagnostics, Chair of Endocrinology,
Medical University of Lodz, Lodz, Poland.

Correspondence to: Professor Marek Pawlikowski, MD, PhD
Department of Experimental Endocrinology and Hormone Diagnostics,
Chair of Endocrinology, Medical University of Lodz,
Sterling str.3, 91-425 Lodz, POLAND
TEL/FAX +48 42 6365427
EMAIL pawlikowski.m@wp.pl

Submitted: March 21, 2005

Accepted: April 3, 2005

Key words: **adrenal cortex; zona reticularis; DHEA; aging**

Neuroendocrinol Lett 2005;26(3):193-195 PMID: 15990720 NEL260305R01 ©Neuroendocrinology Letters www.nel.edu

Abstract

It is well known that plasma levels of dehydroepiandrosterone (DHEA), a steroid hormone secreted by zona reticularis (ZR) of the adrenal cortex, reach the maximal values in the third decade of life and then gradually decline with age. Moreover, the DHEA deficiency is probably responsible for several functional disturbances connected with aging. It was also found that ZR reaches its definitive volume at puberty and undergoes selective atrophy during the aging. Thus, the decline of DHEA may be a simple consequence of ZR atrophy in aged subjects. A hypothesis presented here attempts to explain the mechanism of the age-related ZR atrophy and is based on the adrenal cortex cell kinetics. In the adrenal cortex the cell proliferation indices are lower when we pass from zona glomerulosa (ZG) to the inner zones and are the lowest in ZR. In contrast, the apoptotic index is the highest in ZR. It is suggested that adrenocortical cells renew from the progenitor cells located in ZG /zona fasciculata boundary and /or in subcapsular layer. These cells migrate centripetally undergoing the subsequent steps of differentiation and consecutive divisions– and –if not die en route – reach the most central localization in ZR. In consequence, ZR includes the “oldest” adrenocortical cells which probably in majority reached the “Hayflick’s number” and cannot divide. This results in the preponderance of apoptosis over proliferation leading to progressive ZR atrophy followed by a decline of secretion of ZR-derived steroid hormones.

Introduction

It is well known that plasma levels of dehydroepiandrosterone (DHEA), a steroid hormone secreted by zona reticularis (ZR) of the adrenal cortex and circulating mainly as DHEA-sulfate (DHEAS), undergoes marked changes during the lifespan. Its levels are very low in the early childhood and increase at the puberty reaching the maximal values in the third decade of human life. This is followed by a steady decline with age [1,2,3]. The age-related drop of DHEA and DHEAS contrasts

with the unchanged levels of cortisol, the hormone secreted by zona fasciculata of the adrenal cortex. The experimental animal studies showed several effects of DHEA which seem opposite to the aging processes including immunostimulation, the increase of insulin sensitivity, anti-atherogenic and anti-cancer activities [for review see:4,5]. DHEA levels were suggested to be the markers of longevity in several species including man [6] Thus, DHEA deficiency (called “adrenopause”) is prob-

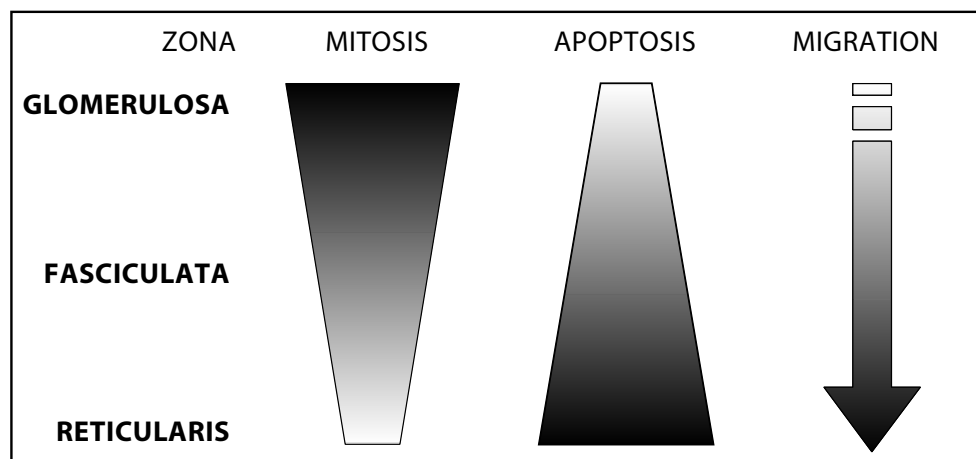


Figure 1.
Schematic presentation of cell kinetics in the adrenal cortex

ably an important factor involved in the mechanism of functional disturbances connected with aging. Interestingly, the age-related changes in DHEA and DHEAS levels reflect the changes in adrenal cortex morphology. The volume of zona reticularis (ZR) is very small in the early childhood, maximal in the third decade of life and diminishes in the middle-aged and old human subjects [7]. The atrophy of ZR in old subjects was also confirmed by more recent studies and it was found to depend on the decrease of cell number in this adrenocortical zone [8]. In contrast, there is no distinct atrophy of zona glomerulosa (ZG) and zona fasciculata (ZF) in the aged subjects, and secretion of hormones elaborated by these zones (aldosterone and cortisol, respectively) is not substantially diminished. Although we cannot exclude the age-related decrease of expression and/or activity of the enzymes involved in DHEA biosynthesis, it seems that ZR atrophy in aging subjects is the simplest explication the age-related decline of DHEA. A question arises what is the cause of the age-related morphological changes in ZR volume? Why does zona reticularis develop at pubertal age but not earlier? Why does it undergo atrophy earlier than the remaining zones of the adrenal cortex? I present here a hypothesis explaining the mechanism of the age-related ZR changes based on the adrenocortical cell kinetics.

Why zona reticularis undergoes a “selective” atrophy during the aging?

It was repeatedly demonstrated in many studies that in the adrenal cortex the cell proliferation indices are the highest in ZG and in the outer part of ZF but the lowest in ZR. This observation was repeatedly done in numerous studies performed in our [9–11] and other laboratories [12–14]. In contrast, the apoptotic index is the highest in ZR [15]. Although the majority of these studies were performed in rodents, the similar observations concern the human adrenal gland [16]. It is suggested that adrenocortical cells renew from the progenitor cells located in ZG /zona fasciculata boundary and /or in subcapsular layer. These cells migrate centripetally undergoing the subsequent steps of differentiation and consecutive divisions, and, finally – if not die en

route – reach the most central localization in ZR [17]. The centripetal migration of adrenocortical cells was demonstrated in experiments with tritiated thymidine labeling in rats. One hour after labeling, 95% of the cells are located in the outer quarter of cortex. Then, in subsequent days, they reach progressively the more central position reaching ZR after 104 days [18]. Another experimental model of centripetal migration is adrenal regeneration in rats after the enucleation of the gland. The regeneration of the adrenal cortex begins from the subcapsular layer and zona glomerulosa appears the first whereas ZR reappears as the last one [19]. If the course of adrenocortical morphogenesis presented above (summarized on Fig.1) is true, the answers for the mentioned questions are rather simple. First, adrenocortical cells (or progenitor cells) have to use a proper time period to migrate from the external layers of the gland to the deepest place where they can differentiate into ZR cells. In consequence, the postnatal development of ZR completes later than that of ZG and ZF. On the other hand, ZR includes the “oldest” adrenocortical cells which reach the so-called “Hayflick’s number” first – the maximal number of possible division and thus cannot divide [20]. This results in the preponderance of apoptosis over proliferation leading to progressive ZR atrophy followed by a decline of secretion of ZR-derived steroid hormones.

Adrenal zona reticularis as a “biological clock”

As it was discussed above the changes of adrenocortical morphology are transposed to the hormonal signal – DHEA and /or DHEAS level in the blood (Fig.2). At the end of childhood the appearance of high DHEA/DHEAS levels are a signal responsible for adrenarche – the important step of the puberty. During the adulthood sufficient DHEA/DHEAS levels assure (obviously acting in concert with many other factors) the well-being of the organism.

In turn, a fall of DHEA/DHEAS secretion resulting from the atrophy of ZR determinates the biological age of senescence. It is known that the high secretion of DHEA is specific for humans [4]. Attractive is a

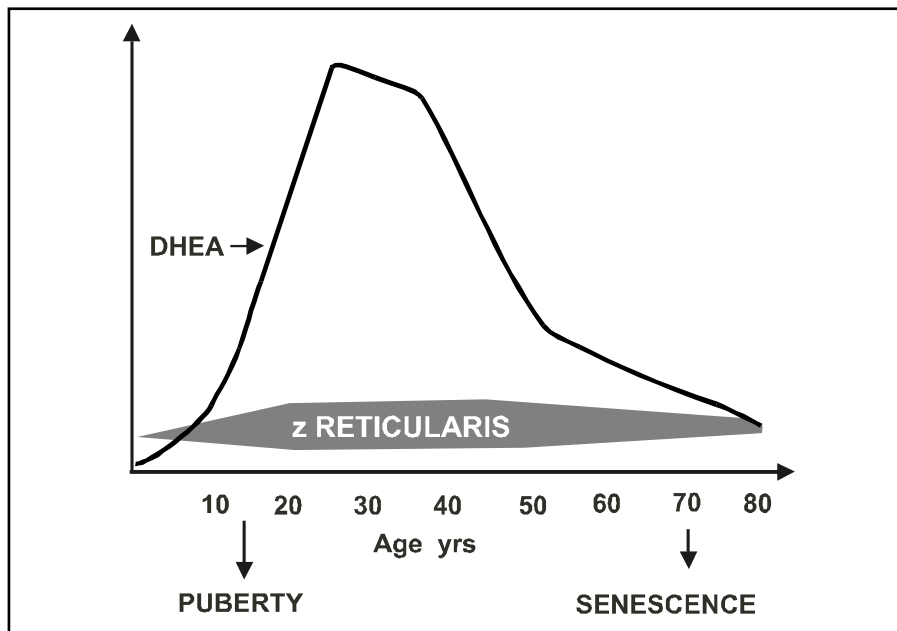


Figure 2. Age-related changes in DHEA secretion (measured as DHEAS levels in blood) and zona reticularis volume.

hypothesis that the high secretion of this steroid is an important factor determining the relative longevity of human species, the latter being in turn very important for culture transmission between the generations. If the adrenal cortex plays a role of “biological clock” all factors which modulate the adrenocortical cell turnover may have an important long-term influence on the processes of maturation and aging. It includes, among others, stress and activity of the renin-angiotensin system, because ACTH and angiotensin peptides strongly affect the adrenocortical cell turnover [17, 21–23]

REFERENCES

- Orentreich N, Brind JL, Rizer RL, Vogelmann JH Age changes and sex differences in serum dehydroepiandrosterone sulfate concentration throughout adulthood *J Clin Endocrinol Metab* 1984; **59**:551–555
- Salvini S, Stampfer MJ, Barbieri RL, Hennekens CH Effect of age, smoking and vitamins on plasma DHEAS levels: a cross-sectional study in men *J Clin Endocrinol Metab* 1992; **74**:139–143
- Vermeulen A Dehydroepiandrosterone sulfate and aging *Ann NY Acad Sci* 1995; **774**:121–127
- Beaulieu EE Studies on dehydroepiandrosterone (DHEA) and its sulfate during aging. *CR Acad Sci Paris- Life Sciences* 1995; **318**: 7–11
- Nawata H, Yanase T, Goto K, Okabe T, Nomura M, Ashida K, Watanabe T Adrenopause *Horm Res* 2004; **62** (suppl 3):110–114
- Roth GS, Lane MA, Ingram DK, Mattison JA, Elahi D, Tobin JD, Muller D, Metter EJ Biomarkers of caloric restriction may predict longevity in humans *Science* 2002; **297**:811–811
- Pawlikowski T Endocrine glands in children (in polish) *Endokr.Pol.*1962; **13**:467–485
- Staton BA, Mixon RL, Dharia S, Brissie RM, Parker CR Jr Is reduced cell size the mechanism for shrinkage of the adrenal zona reticularis in aging? *Endocr Res* 2004; **30**:529–534
- Żerek-Meleń G, Pawlikowski M. Effects of TRH and TRH-like peptide pGlu-HisGlyNH₂ on adrenocortical cell proliferation in rats. *Endocrine* 1996; **5**:179–183, .
- Sewerynek E, Lewiński A Melatonin inhibits mitotic activity of adrenocortical cells in vivo and in organ culture *J Pineal Res* 1989; **7**:1–12
- Pawlikowski M, Gruszka A, Mucha S, Meleń-Mucha G Angiotensins II and IV stimulate the rat adrenocortical cell proliferation acting via different receptors *Endocrine Regulations* 2001; **35**: 139–142.
- Hunt TE, Hunt EA A radioautographic study of the proliferative activity of adrenocortical and hypophyseal cells of the rat at different periods of the estrus cycle *Anat Rec* 1966; **156**:361–368
- Reiter RJ, Hoffman RA Adrenocortical cytogenesis in the adult golden hamster: a radioautographic study using tritiated thymidine *J Anat* 1967; **101**:723–729
- Kasprzak A, Lesniewska B, Malendowicz LK: Sex differences in adrenocortical structure and function XXI The effects of gonadectomy and testosterone or estradiol replacement on mitotic activity of the rat adrenal cortex *Exp clin Endocrinol* 1986; **87**: 26–30
- Carsia RV, MacDonald GJ, Gibney JA, Tilly KI, Tilly JL Apoptotic cell death in the rat adrenal gland: an in vivo and in vitro investigation. *Cell Tissue Res* 1996; **283**:247–254
- Sasano H, Imatani A, Shizawa S, Suzuki T, Nagura H Cell proliferation and apoptosis in normal and pathological human adrenal *Mod Pathol* 1995; **8**: 11–17
- Hornsby PJ Aging of the human adrenal cortex *Ageing Res Rev* 2002; **1**:229–242
- Zajicek G, Ariel I, Arber N The streaming adrenal cortex: direct evidence of centripetal migration of adrenocytes by estimation of cell turnover rate *J Endocrinol* 1986; **111**:477–482
- Zieleniewski J, Nowakowska-Jankiewicz B Studies on mitotic activity in course of adrenal cortex regeneration after enucleation *Acta Med Pol* 1986; **27**:93–96
- Peacocke M, Campisi J Cellular senescence: a reflection of normal growth control, differentiation, or aging? *J Cell Biol* 1991; **45**: 147–155
- Mitani F, Miyamoto H, Mukai K, Ishimura Y Effects of long term stimulation of ACTH and angiotensin II secretions on the rat adrenal cortex *Endocrine Res* 1996; **22**:421–431
- Mc Ewen PE, Lindop GB, Kenyon CJ Control of cell proliferation in the rat adrenal gland in vivo by the renin-angiotensin system *J Physiol* 1996; **271**: E192–E198
- Mazzocchi G, Malendowicz KL, Gotterdo G, Rebuffat P, Nussdorfer GG Angiotensin II stimulates DNA synthesis in rat adrenal zona glomerulosa cells: receptor subtypes involved and possible signal transduction mechanism *Endocrine Res* 1997; **23**:191–203