

Diagnosis and treatment of solitary fibrous tumor/ hemangiopericytoma of central nervous system. Retrospective report of 17 patients and literature review

Long MA¹, Lu WANG¹, Xiaoxuan FANG¹, Cong-hai ZHAO¹, Libo SUN¹

¹ Department of Neurosurgery, China-Japan Union Hospital, JiLin University, China.

Correspondence to: Libo Sun, NO.126, XianTai Street, China-Japan Union Hospital, JiLin University, ChangChun, JiLin, 130033, China
E-MAIL: sunlibo@jlu.edu.cn

Submitted: 2017-09-04 Accepted: 2018-02-05 Published online: 2018-07-12

Key words: **central nervous system neoplasms; solitary fibrous tumor; hemangiopericytoma; diagnosis; therapy; prognosis**

Neuroendocrinol Lett 2018; **39**(2):88–94 PMID: 30183202 NEL390218A05 ©2018 Neuroendocrinology Letters • www.nel.edu

Abstract

To investigate the diagnosis, treatment and prognosis of solitary fibrous tumor (SFT)/ hemangiopericytoma (HPC) of central nervous system (CNS), we retrospectively reviewed records of 17 patients who were treated for CNS SFT/HPC at the Department of Neurosurgery, China–Japan Union Hospital of Jilin University from December 2010 to June 2016, and reevaluated their pathological diagnoses according to the 2016 WHO classification of CNS tumors. We then analyzed their clinical symptoms, imaging characteristics, treatments and outcomes. Clinical manifestations of CNS SFT/HPC were diverse, but mainly included headache, increased intracranial pressure, seizures, and focal neurological deficits. In MRI, CNS SFT/HPC usually shows heterogeneous signals, and unusual enhancements; we saw lobulated shapes in 13 patients and necrotic or cystic changes in 12 patients. Tumors of all 17 patients were resected surgically; 9 patients also received postoperative adjuvant radiotherapy. Mean follow-up time was 21 months (range: 2–67 months). The 17 surgeries included 11 total resections, 4 subtotal resection, and 2 partial resections. We followed up 12 patients; 9 of the patients who received total resections had no disease progression; among the 6 patients who did not receive total resections, 2 died of tumor recurrence, 1 has not shown any disease progression. Thus, extent of resection has an apparently crucial influence on prognosis. Postoperative radiotherapy should be chosen carefully, based on resection extent and pathologic grade.

INTRODUCTION

Solitary fibrous tumor (SFT)/ hemangiopericytoma (HPC) of the central nervous system (CNS) is a new diagnosis proposed by WHO in 2016 (Louis *et al.* 2016a). Here, we analyzed retrospectively clinical data of 17 patients with CNS SFT/HPC who were admitted to Department of Neu-

rosurgery, China-Japan Union Hospital, Jilin University, from December 2010 to June 2016, and reclassified their diagnoses according to the new classification system. We have summarized their clinical characteristics, diagnoses, treatments and outcomes, in the light of previous literature.

MATERIALS AND METHODS

Clinical data

We enrolled 17 patients with SFT/HPC, including 9 men and 8 women, whose average age was 48.8 years (range: 33–78 years). Clinical manifestations included headache and dizziness in 11 patients, nausea and vomiting in 4 patients, weakness in lower limbs and gait instability in 2 patients, and ataxia, facial numbness, and hearing loss in 1 patient each. Average duration of primary SFT/HPC symptoms in 13 patients was 8.5 months (range: 2 weeks to 60 months); 4 patients of recurrent SFT/HPC were the first recurrence, the recurrence time was 8 years and 14 years after operation (Table 1)

Imaging data

All patients underwent preoperative CTs, and plain and enhanced MRI scans. Magnetic resonance venography (MRV) was performed in 4 patients whose foci were involved in their intracranial venous sinuses, and 3 patients underwent diffusion tensor imaging (DTI). Magnetic resonance angiography (MRA) and proton magnetic resonance spectroscopy (^1H resonance spectroscopy, ^1H -MRS) were performed in 2 patients. We found 19 clear-boundary foci, 3 of which were found in 1 patient.

Therapeutic method

All 17 patients underwent tumor surgical resections, a total of 17 surgeries. Two patients also underwent

Tab. 1. Clinic data of 17 patients with HPC/SFT

Case	Gender	Age	Position	The mass diameter	Clinical symptoms	Classification in WHO	Therapies	Follow-up
1	F	56	Frontal lobe parenchyma	4.0*2.4cm	Dizziness, headache	II	TR	Clinical cure
2	F	38	Anterior skull base	4.4*2.7*2.9cm	Dizziness, headache, upper limb numbness	II	TR,PPR	Clinical cure
3	M	47	Anterior skull base	2.4*2.4cm	Interrupted occipital headache	II	TR	Delayed bleeding in 4 days after surgery, conservative treatment
4	F	44	Near frontal sinus falx	4*5cm	Interrupted occipital headache	II	TR,PPR	Postoperative right
5	M	63	in vertebral canal	2.6*1.4cm	Occipital and neck pain for two months	II	TR,PPR	Clinical cure
6	M	40	Anterior skull base, communicated with the extracranial	12*5*2cm	Second operation, headache	II	SR,PPR	Dead after 8 months
7	M	43	Middle cranial base	3.0*2.0*3.4cm	Nausea ,vomiting, headache,stroke onset	II	PR	Coma, death after 2 months
8	M	33	Lateral occipital sinus	3*3*3cm	Unclear vision	II	TR,PPR	Clinical cure
9	M	39	Cerebellum tentorial	3.9*2.7*3.1cm	Progressive headache, stiff neck	II	TR	Loss to follow-up
10	F	57	Frontal lobe parenchyma	4.4*3.5*5.1cm	Meningiomas, headache	III	TR,PPR	Clinical cure
11	F	55	Multiple intracranial tumor		Headache, dizziness and memory loss	II	PR	2 months after surgery, tumor stroke, the family abandoned
12	F	49	Anterior skull base	4.1*3.9*3.4cm	Nausea and vomiting	II	TR	Loss to follow-up
13	F	50	Middle cranial base	5.2cm*4.2cm	Ataxia and headache	Atypical SFT	TR	Loss to follow-up
14	M	78	Left CPA	3*3	Nausea and vomiting	SFT	SR,PPR	Died of lung infection
15	F	40	Middle cranial base	3.7*5.8*4.6cm	Nausea and vomiting	II	SR,PPR	Remote postoperative bleeding, drilling
16	F	47	Frontal lobe parenchyma	3.4*4.0*3.5	Headache, scalp numbness	II	TR	Loss to follow-up
17	M	53	Near frontal sinus falx	3*4*6	Headache	II	SR,PPR	Loss to follow-up

drilling and drainage for postoperative intracranial hemorrhage. During surgery, all tumors appeared as red or gray-red nodules with hard-tough texture. In 11 patients, tumor envelope structures were clear. In 10 patients, the tumor bases were attached to the meninges, with abundant blood supplies.

Surgical approaches were selected according to the site of each tumor. For a patient whose tumor was located in the skull base, because of its low basal position, we chose the improved and extended middle cranial fossa approach and resected the tumor after transection of the zygomatic arch. For a patient with a tumor in the cerebellopontine, we chose a posterior sigmoid sinus approach. For a patient with a tumor in the vertebral canal, we chose a posterior median approach. We considered relationships between the foci and important nerves and vascular tissue, with electrophysiological monitoring used in all surgeries. Nine patients also underwent adjuvant radiotherapy (RT).

Follow-up

Follow-up time averaged 21 months (range: 2–67 months), and included both imaging and telephone follow-up.

RESULTS

Imaging

Most of the CT images showed mixed- and high-density shadows; a few only showed high-density shadow and cystic degeneration but no calcification. MRI showed equal T1 signal, and high or mixed T2 signal. We saw 13 lobulated cases, 12 cases with necrosis, cystic degeneration and/or uneven enhancement, and 7 cases with void vessels or blood flow shadows. Two patients had skull invasion and in-extracranial communication.

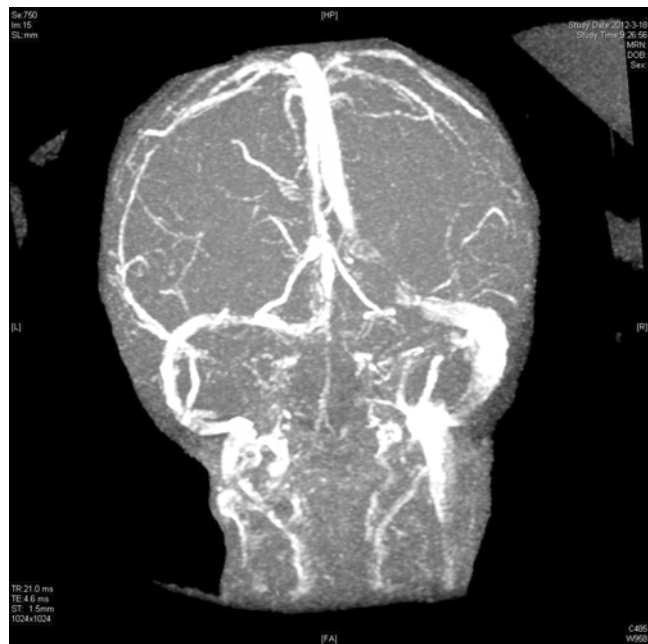

Fig. 1. MRV shows invasion and occlusion of the intracranial venous sinus.

Enhanced MRI scan showed obvious tumor enhancement, with obvious “dural tail signs” in 5 patients. MRV showed invaded and occluded intracranial venous sinuses, and MRA showed abundant tumor blood supplies (Figure 1).

DTI examination showed fiber bundles around tumor were interrupted or compressed. 1H MRS showed that the aspartic acid peak decreased obviously and disappeared in part of the region, the creatine peak decreased, and the choline peak increased significantly (Figure 2).

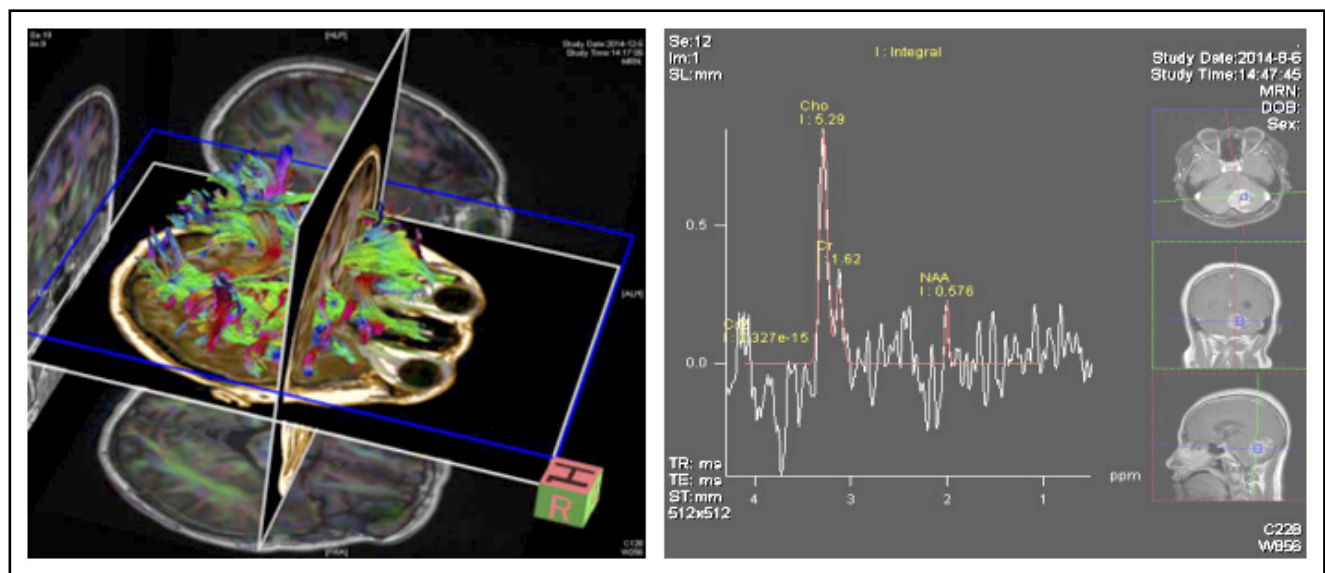


Fig. 2. DTI examination shows the fiber bundle around the tumor was interrupted or compressed. 1H-MRS shows that the aspartic acid peak decreased obviously and disappeared in a part of the region, the creatine peak decreased, and the choline peak increased significantly. There is no inositol peak at 3.56 ppm.

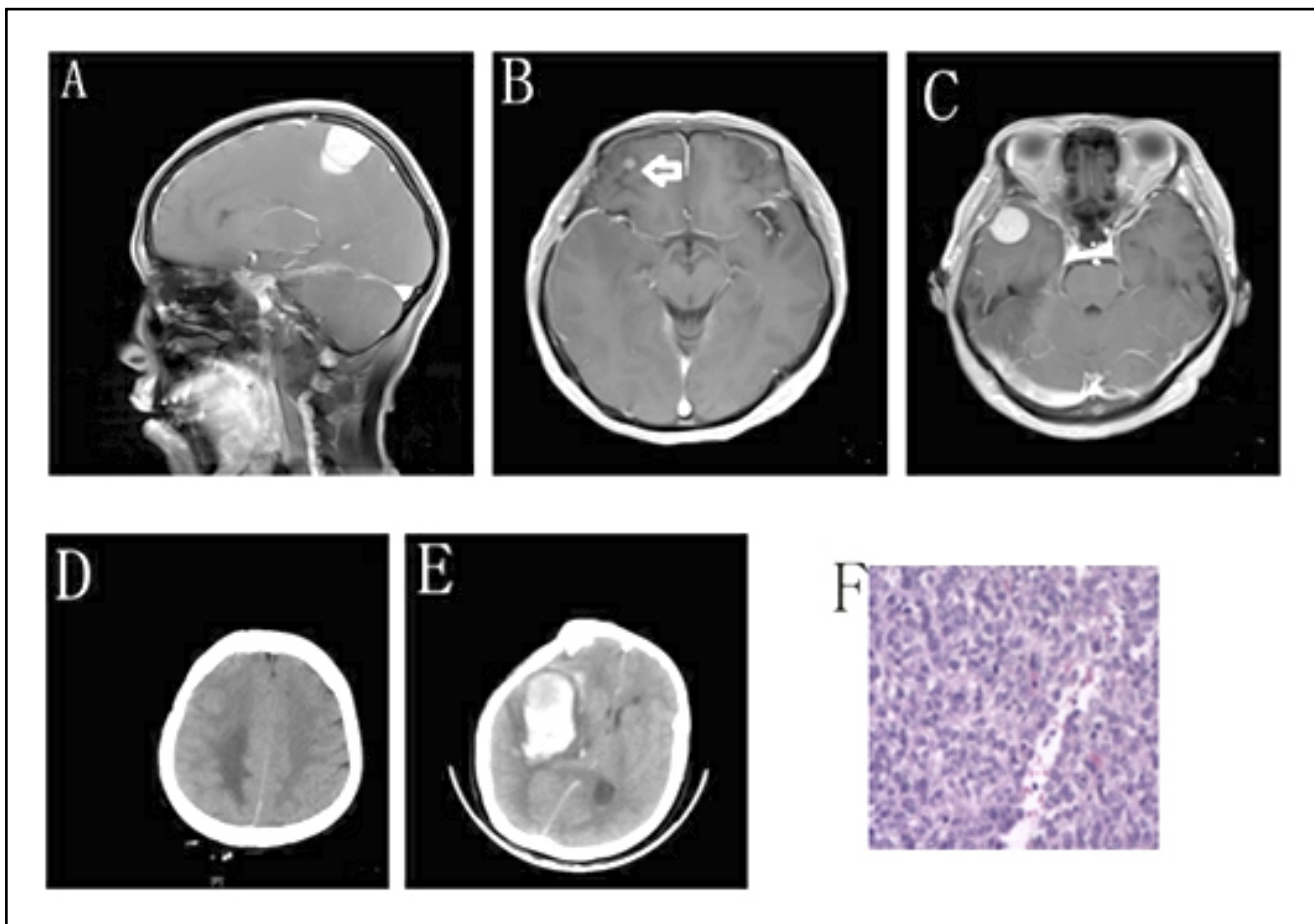


Fig. 3. This is a 55-year-old female patient who was eventually diagnosed with WHO stage II SFT/HPC. A–C: Multiple lesions. D. Postoperative reexamination. E. Two months after surgery, the patient was unconscious; cranial CT showed a temporal lobe lesion. F. Postoperative pathological results (HE staining, $\times 200$) showed many special cells and small amounts of collagen and “staghorn” vessels

Four patients had tumors in their anterior skull bases, 3 in their middle cranial bases, 2 near their frontal sinus falces, 2 patients in their parietal parenchyma, 1 patient each with tumors in the frontal lobe parenchyma, lateral occipital sinus, tentorial cerebellum, cerebellopontine angle, or vertebral canal, and 1 patient had multiple intracranial tumors. The smallest tumor was $1.5 \times 2.0 \times 2.4$ cm; the largest was $2.5 \times 5.5 \times 12.0$ cm, located in the anterior skull base and extending extracranially.

Surgical outcome and complications

Of the 17 patients, total resections were achieved in 11 patients, subtotal resections in 4 patients, and partial resections in 2 patients. Of the 2 patients who underwent partial resections, 1 patient had lesions in the frontal, parietal and temporal lobes. After resection of the parietal lobe lesions, residual lesions were treated with adjuvant RT (Figure 3).

One patient suffered a considerable bleeding during surgery, for which a hematoma cavity was formed. After the hematoma was removed, the tumor was not completely removed, and 3 days after surgery, the residual tumor wound closure showed bleeding.

Patients' families abandoned treatment for different reasons. An elderly patient had a successful operation, but died of pulmonary infection owing to long-term bed rest. A patient was diagnosed with hematenkephalon a day after surgery and underwent drilling drainage. Two patients were diagnosed with delayed cerebral hemorrhage; one had hemorrhaged during surgery but improved through conservative treatment, and the other patient bled in an area far from the lesions, and improved after drilling drainage.

Pathological results

According to the 2007 WHO classification standard for CNS tumors, these 17 patients had been diagnosed (respectively) with 13 cases of differentiated HPC, and one case each of anaplastic HPC, typical SFT, atypical SFT, and SFT-or-HPC. According to the 2016 WHO classification standard, all the patients were diagnosed with SFT/HPC, including 3 Grade I cases, 13 Grade II cases, and 1 Grade III case.

Follow-up results

Of the 17 patients, 12 were followed up, 5 were lost to follow-up, 1 patient died, and 1 was abandoned by his

family. In the 12 followed-up patients, 7 patients who underwent total tumor resections had no disease progression in follow-up period. In the subtotal resection group ($n=3$), 1 patient underwent postoperative RT and died of disease progression 8 months later, 1 is in smooth condition. One patient who received a partial resection underwent postoperative RT, residual tumor stroked in 2 months postoperatively, the family abandoned treatment on the patient.

DISCUSSION

SFT and HPC are both solid tumors that arise from mesenchymal tissue and are found mostly in soft tissue, rarely in the CNS. Since 1996, when Carneiro *et al.* (1996) first reported CNS SFT, about 200 patients have been reported, including 28 Chinese patients described in one report (Yin Weining *et al.* 2009).

HPC is less rare, and accounts for about 1% of intracranial tumors, and 2%–3% of meningeal tumors. Stout and Murray described HPC for the first time in 1942, and noted that this tumor with a rich blood supply was made up of perivascular cells (Louis *et al.* 2016a). Until WHO divided meningioma into two subtypes in 1993, HPC existed as an independent diagnosis; and was further divided into differentiated HPC and variant HPC by WHO in 2007.

The development of molecular pathology showed SFT and HPC both to have reversed 12q13 and the *NAB2-STAT6* fusion gene, leading to nuclear STAT6 expression, which can be detected immunohistochemically. This expression inevitably causes their diagnoses to overlap (Carneiro *et al.* 1996).

One patient in our cohort was diagnosed as “HPC-or-SFT.” Zhang Jie and coworkers (Zhang Jie & Du Guhong 2010) retrospectively analyzed 106 patients with CNS HPC, but they also could not exclude the possibility of SFT in their cohort. Bouvier *et al.* (2012) noted that HPC and SFT have similar clinical and morphological features, including their component vascular pericytes (Yin Weining *et al.* 2009); they also found a patient with primary HPC that recurred as SFT postoperatively, whereas 4 patients with primary SFT recurred with HPC.

Because of these findings, in 2016, WHO combined CNS SFT and HPC into SFT/HPC and proposed the following classifications: Grade I SFT/HPC showed more collagen and relatively low cell density; Grade II showed more cells and less collagen, mast cells and “staghorn” vessels; Grade III showed more features of the HPC variants—specifically, >5 nuclear fission images every 10 high magnification fields (Fountas *et al.* 2006).

Because the SFT/HPC was only recently identified as a diagnosis and the number of patients is small, epidemiological studies of SFT/HPC are rare. After Fargen *et al.* (2011) evaluated 189 cases of SFT, they noted that incidence peaks at 51 to 60 years of age. Bisceglia *et al.* (2011) analyzed 217 SFT cases (103 males and

114 females) and found that 89.58% of patients were >30 years old, whereas those <18 years old accounted for only 3.64% (Louis *et al.* 2007b). Rutkowski's study (Rutkowski *et al.* 2010) included 563 HPC cases, whose average age of morbidity was 41 years old, and who were 55% men and 45% women; they found incidence did not significantly differ by sex (Zhang Jie & Du Guhong 2010), which was similar to our results. A group of 15 patients included one patient whose tumor was located in the atlas spinal canal. According to the literature, the probability of SFT/HPC occurring in the spinal canal is 5%–6% – mostly in the cervical or thoracic segments (Bouvier *et al.* 2012; Fargen *et al.* 2011).

In our group, one patient had a rare case of primary intracranial multiple tumors. Although multiple intracranial and spinal SFT/HPC have been reported previously (Fargen *et al.* 2011; Bisceglia *et al.* 2011), to our knowledge, this is the first report of a patient with multiple intracranial tumors. We consider that the intracranial multiple lesions was caused by intracranial tumor spread over the patient's 2-year disease course.

In addition to the 2 patients who relapsed, the possibility of SFT/HPC was excluded preoperatively. All 17 patients in our cohort were misdiagnosed, 16 as having meningioma, and 1 as having hemangioblastoma. Considering that images for some patients featured typical “dural tail signs,” the possibility of SFT/HPC should not be ignored, especially for putative “meningiomas” with lobulated shapes or necrotic signals in diagnostic images. These patients underwent ¹H-MRS and MRA to confirm diagnoses, and MRV and DTI to help guide their surgeries. Barba *et al.* (2001) thought that SFT/HPC would increase inositol peaks to about 3.56 ppm in ¹H-MRS (Rutkowski *et al.* 2010). However, no patients in this group had inositol peaks. SFT/HPC could be differentiated from meningioma on this basis. Reportedly, MRAs in 2 patients showed tumors to have rich blood supplies but no stain (Shirzadi *et al.* 2013). As MRA failed to show whether the external carotid artery could supply blood flow to the tumor, its diagnostic value was lower than that of digital subtraction angiography(DSA).

Prior to establishment of SFT/HPC diagnosis, characteristics of HPC imaging included: (a) lobulated appearance; (b) abundant blood supply, mainly supported by the internal and external carotid arteries; and (c) multiple cystic or necrotic signals, rare calcifications, and obviously uneven enhancements on enhanced MRI scans. As SFT had a lower incidence, its imaging characteristics were less defined. MRI signals for SFT were considered by some to be changeable, with more mixed signals based on T1 isosignals and low T2 signals, and rare calcifications (Shirzadi *et al.* 2013; Radley & McDonald 2001). With enhanced MRI scanning, T2-low signal areas were clearly strengthened. In addition, areas rich or lacking in tumor cell that appear alternately, as the “Yin and Yang” or “black and white” pattern, support the diagnosis of SFT. In DSA, both SFT

and HPC were found to be rich in blood supply; SFT could also be seen the presence of double blood supply. Thus, as HPC and SFT have similar imaging features, their combined diagnosis can reduce the incidence of presurgical misdiagnosis (Yang Jun *et al.* 2001).

Although intracranial SFTs and HPCs showed similar clinical distributions by patient sex, age, tumor site and tumor size (Yang Jun *et al.* 2001; Barba *et al.* 2001), Bouvier *et al.* (2012) showed (using univariate analysis) that SFT/HPC prognosis was closely related to the degree of surgical resection. A retrospective study of 189 patients with SFT by Fargen *et al.* (2011) showed that, compared with a 14% recurrence rate from total resection, the relapse rate from subtotal resection could be as high as 54%. The study of 15 patients with HPC by Kumar *et al.* (2012) also showed that patients with total resection had longer median survival.

Radiotherapy for SFT is not widely researched. Five SFT patients who did not receive total resections underwent postsurgical RT, but the results were not satisfactory (Zhai Bo Zhi *et al.* 2010). Although RT after HPC surgery is widely used as an auxiliary modality, a consensus on optimal RT treatment is not available for these patients. Rutkowski *et al.* (2010) thought that postoperative RT could not effectively prolong survival of HPC patients (Clarenqon *et al.* 2011); those who received RT doses >50 Gy in his study had even worse outcomes than patients who received lower doses. The current study showed that the prognosis of patients who underwent total tumor resections was better; although patients who did not receive total resections underwent adjuvant RT, their prognosis is not ideal. Possibly patients in whom complete tumor resections were not feasible had a longer or more severe disease for which prognosis was not improved by RT. Because the SFT/HPC diagnosis is so recently established, selection of RT for patients with HPC/SFT should be carefully considered with regard to the extent of resection and tumor pathological grading.

As the benefits of postoperative RT or chemotherapy on SFT/HPC are unclear, well-executed surgical treatment is required. At the same time, the tumor's rich blood supply brings great challenges to the surgeon. Death from intraoperative bleeding has been reported, as has intraoperative bleeding that led to only partial or subtotal resections (Kumar *et al.* 2012). In our group, 1 patient was unable to receive a total resection because of intraoperative bleeding, and 4 patients suffered postoperative hemorrhages.

Suspected SFT/HPC patients need complete examinations. DSA can assist in diagnosis and preoperative embolization of feeding arteries (Zeng *et al.* 2016). DTI examinations are needed for lesions in functional areas, and MRVs for lesions located near sinuses. The SFT/HPC lesions were hard, which made use of ultrasonic aspirators less effective; although capsule-like structure may be visible, the coating is not complete. Most

of the patients were treated with tumor resections; their tumors were resected completely or partially. For tumors seated near important nerve or vascular tissue, intraoperative electrophysiological monitoring can improve surgical guidance. The key to successful resection is properly addressing the tumor wound and hemostasis. Three of our patients suffered postoperative delayed bleeding. Even if intraoperative hemostasis is effective, postoperative bleeding is possible, and thus more attention should be paid to related risk factors (Ambrosini-Spaltro & Eusebi 2010).

REFERENCES

- 1 Ambrosini-Spaltro A, Eusebi V (2010). Meningeal hemangiopericytomas and hemangiopericytoma/solitary fibrous tumors of extracranial soft tissues: a comparison. *Virchows Arch. Apr*; **456**(4): 343–54.
- 2 Barba I, Moreno A, Martinez-Pérez I, Tate AR, Cabañas ME, Baquero M, Capdevila A, Arús C (2001). Magnetic resonance spectroscopy of brain hemangiopericytomas: high myoinositol concentrations and discrimination from meningiomas. *J Neurosurg.* 2001 Jan; **94**(1): 55–60.
- 3 Bisceglia M, Galliani C, Giannatempo G, Lauriola W, Bianco M, D'angelo V, Pizzolitto S, Vita G, Pasquinelli G, Magro G, Dor DB (2011). Solitary fibrous tumor of the central nervous system: a 15-year literature survey of 220 cases (August 1996-July 2011). *Adv Anat Pathol. Sep*; **18**(5): 356–392. doi: 10.1097/PAP.0b013e318229c004.
- 4 Bouvier C, Metellus P, de Paula AM, et al (2012). Solitary fibrous tumors and hemangiopericytomas of the meninges: overlapping pathological features and common prognostic factors suggest the same spectrum of tumors. *Brain Pathol*, **22**(4):511–521.
- 5 Carneiro SS, Scheithauer BW, Nascimento AG, et al (1996). Solitary fibrous tumor of the meninges: a lesion distinct from fibrous meningioma. A clinicopathologic and immunohistochemical study. *Am J Clin Pathol*. **106**(2): 217–224.
- 6 Clarenqon F, Bonneville F, Rousseau A, et al (2011). Intracranial solitary fibrous tumor: imaging findings. *Eur J Radiol*, **80**(2): 387–394.
- 7 Fargen KM, Opalach KJ, Wakefield D, et al (2011). The central nervous system solitary fibrous tumor: a review of clinical, imaging and pathologic findings among all reported cases from 1996 to 2010. *Clin Neurol Neurosurg*, **113**(9): 703–710.
- 8 Fountas KN, Kapsalaki E, Kassam M, et al (2006). Management of intracranial meningeal hemangiopericytomas: outcome and experience. *Neurosurg Rev*, **29**(2): 145–153.
- 9 Kumar N, Kumar R, Kapoor R, et al (2012). Intracranial meningeal hemangiopericytoma: 10 years' experience of a tertiary care Institute. *Acta Neumchir (Wien)*, **154**(9): 1647–1651.
- 10 Louis DN, Perry A, Reifenberger G, et al (2016a). The 2016 World Health Organization Classification of Tumors of the Central Nervous System: a summary. *Acta Neuropathol*, **131**(6): 803–820.
- 11 Louis DN, Ohgaki H, Wiestler OD, et al (2007b). The 2007 WHO classification of tumours of the central nervous system. *Acta Neuropathol*, **114**(2): 97–109.
- 12 Radley MG, McDonald JV (2001). Meningeal hemangiopericytoma of the posterior fossa and thoracic spinal epidural space: case report. *Neurosurgery*, 1992, **30**(3): 446–452.
- 13 Rutkowski MJ, Sughrue ME, Kane AJ, et al (2010). Predictors of mortality following treatment of intracranial hemangiopericytoma. *J Neurosurg*, **113**(2): 333–339.
- 14 Shirzadi A, Drazin D, Gates M, et al (2013). Surgical management of primary spinal hemangiopericytomas: an institutional case series and review of the literature. *Eur Spine J*, **22** Suppl 3: S450–S459.

- 15 Yang Jun, Zhou Wei, Shen Feng (2001). A case of multiple hemangiopericytoma in cervical and thoracic vertebral canal. *The Chinese journal of neurosurgery*, **17**(6):349.
- 16 Yin Weining, Cai Bowen, Chen Huijiao, et al (2009). The diagnosis and treatment on solitary fibrous tumors of the Central Nervous System(attach with the report of 28 cases). *Chinese Journal of Clinical Neurosurgery* **14**(1): 1–3.
- 17 Zeng L, Wang Y, Wang Y, Han L, Niu H, Zhang M, Ke C, Chen J, Lei T (2016). Analyses of prognosis-related factors of intracranial solitary fibrous tumors and hemangiopericytomas help understand the relationship between the two sorts of tumors. *Neurooncol*, Sep 26. **131**(1):153–161.
- 18 Zhai Bo Zhi, Zhuo Jie, Liu Chunsheng, et al (2010). The clinical characteristics and treatment of intracranial hemangiopericytoma. *The Chinese journal of neurosurgery*, **26**(9): 778–780.
- 19 Zhang Jie, Du Guhong (2010). Hemangiopericytoma of the central nervous system:106 cases of clinical analysis. *The Chinese journal of neurosurgery*, 2010, **26**(10): 935–937.