

# High grade intermediate cell neuroendocrine cancer of the larynx - Case report

Magdalena DUTSCH-WICHEREK<sup>1</sup>, Marek KLIMEK<sup>2</sup>, Katarzyna URBANCZYK<sup>3</sup>,  
Maciej MODRZEJEWSKI<sup>1</sup> & Jacek SKLADZIEN<sup>1</sup>

<sup>1</sup> ENT Head and Neck Surgery Department of the Jagiellonian University,  
Sniadeckich 2 Str, 31-501 Krakow, Poland

<sup>2</sup> Department of Gynecology and Infertility, Jagiellonian University, Krakow, Poland.

<sup>3</sup> Department of Pathomorphology, Jagiellonian University, Krakow, Poland.

*Correspondence to:* Magdalena Dutsch-Wicherek MD, PhD  
ENT Head and Neck Surgery  
Department of the Jagiellonian University  
Sniadeckich 2 Str, 31-501 Krakow, POLAND  
PHONE: +48 12 4247900; FAX: +48 124247925  
EMAIL: mowicher@cyf-kr.edu.pl

*Submitted:* August 1, 2006

*Accepted:* August 12, 2006

*Key words:* **neuroendocrine carcinoma; laryngeal cancer; neuroendocrine cancer of larynx**

Neuroendocrinol Lett 2006; **27**(5):573-577 PMID: 17159827 NEL270506C02 ©Neuroendocrinology Letters [www.nel.edu](http://www.nel.edu)

## Abstract

Primary poorly differentiated neuroendocrine carcinomas are rare pathological findings in the upper respiratory tract, approximately 650 cases have been reported in the literature. We report a case of 51-year old male with a high grade intermediate cell neuroendocrine epiglottic cancer. The current classification according to the WHO Classification of Tumors published in 2005 is discussed.

## Introduction

Primary poorly differentiated neuroendocrine carcinomas are rare pathological findings in the upper respiratory tract, approximately 650 cases have been reported in the literature [3]. The terminology and classification of these tumors have been confusing for many years; the current WHO Classification of Tumors published in 2005 systematized the nomenclature of these tumors [1]. Basing on the tissue of origin neuroendocrine tumors of the larynx are divided into two types: paraganglionic and epithelial. Epithelial tumors constitute 0.06% of all laryngeal cancers and include carcinoid, atypical carcinoid, neuroendocrine carcinoma and carcinoma of composed structure containing neuroendocrine, squamous and glandular components [1,2]. The most common tumor is atypical carcinoid (54% of neuroendocrine tumors), small cell neuroendocrine carcinoma (34%), paraganglioma (9%) and carcinoid (3%) [1]. Carcinoid and atypical carcinoid in this

localization are now classified as neuroendocrine carcinoma of respectively, low grade or high grade [1,2]. The histological picture is typical for neuroendocrine neoplasms [1]. Poorly-differentiated neuroendocrine carcinoma constitutes 0.5% of all laryngeal cancers, and is three times more common in men being unusual in patients below 40 years. The tumor may arise in any region of the larynx, the supraglottic region is the most common site. It occurs as an oat cell carcinoma or carcinoma composed of intermediate cells. The first type is characterized by monomorphous cell population, whereas in the second one cell and nuclear polymorphism occurs, sometimes with formation of rosettes and glandular or squamous differentiation [1]. Poorly differentiated neuroendocrine neoplasms in immunohistochemical analysis may stain for epithelial antigens like EMA (epithelial membrane antigen), CK (cytokeratin) and neuroendocrine

markers, NSE (neuron specific enolase), chromogranin, S-100, synaptophysin, bombesin and calcitonin [1,2].

We present a case of neuroendocrine poorly differentiated cancer of intermediate cell type arising in larynx.

### Report of case

A 51-year old man presented to ENT Head and Neck Surgery Department of the Jagiellonian University with a discomfort in swallowing. He had smoked 1 package of cigarettes per day since the age of 18 years. Direct laryngoscopy disclosed an ulcerating tumor 1,0 cm in greatest dimension in the laryngeal surface of epiglottis perforating to the glottic surface, well separated from the adjacent tissue, the other portions of larynx were free of disease. The biopsy of the tumor revealed high grade neuroendocrine carcinoma. Cervical lymph nodes were not enlarged on palpation. Because of local range of the disease and the presence of ulcerating tumor with clinical symptoms like effort dyspnoe and discomfort in swallowing the decision of surgical treatment was undertaken; the patient underwent a horizontal laryngeal resection with bilateral neck dissection with subsequent additional chemotherapy.

#### Pathologic findings

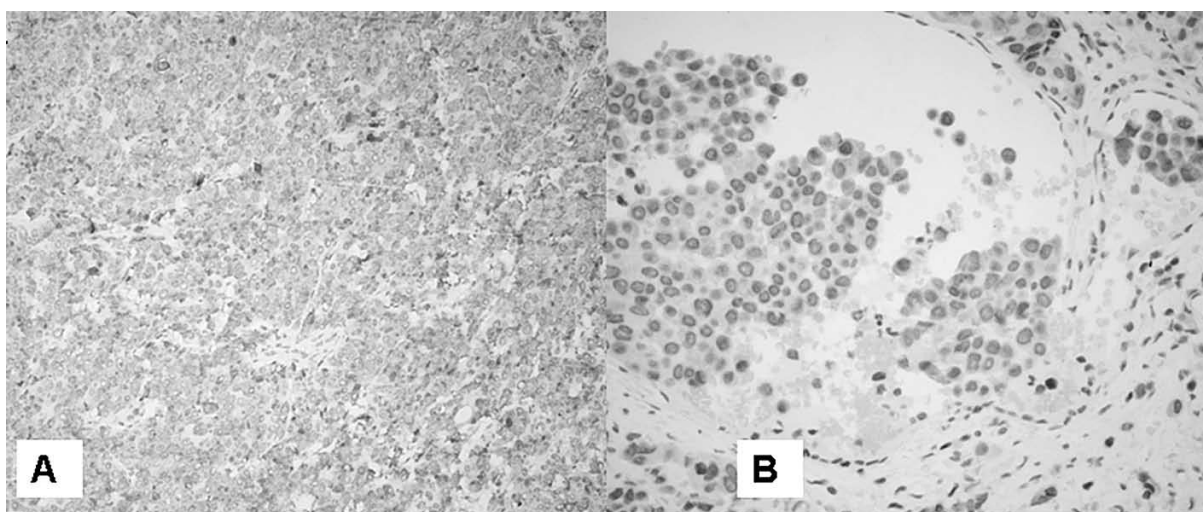
For histopathological examination at the Department of Pathomorphology CMUJ the slide stained with HE with adequate paraffin block was sent. According to clinical data the specimen was obtained from a tumor located in epiglottis in a 51-year old man. Immunohistochemistry was performed on paraffin sections using DAKO Immunostainer and following antibodies: chromogranin A (1:100, DAKO), synaptophysin (1:50, DAKO), EMA (1:100, DAKO), CK7 (1:50, DAKO), CK20 (1:50, DAKO), CD34 (1:25, DAKO), S-100 (1:200, DAKO).

Microscopically small pieces of mucosa were visible, covered by non-keratinizing squamous epithelium, with


infiltrate of poorly differentiated small cell neoplasm in the stroma. The neoplastic cells were chromogranin A (Fig.1A), synaptophysin (Fig.1B) and EMA-positive on immunohistochemistry. So, the diagnosis of high grade neuroendocrine carcinoma was established.

The surgical material encompassed epiglottis with adjacent fibrous and fatty tissue, 4x3x2cm in size. On the laryngeal surface of the epiglottis ulceration was visible 1cm in diameter, and cut sections revealed solid, whitish, tumorous infiltrate up to 3cm in the greatest dimension beneath it.

Histopathological examination revealed solid infiltrate of poorly differentiated carcinoma, with foci of coagulative necrosis as well as single apoptotic neoplastic cells. The neoplastic infiltrate involved almost the entire epiglottis, however the surgical margins were free from disease. Approximately 2/3 of the cancer area were composed of medium-size cells with moderately abundant cytoplasm and mild polymorphism (Fig.2A). The oval nuclei presented features of atypia, with prominent, pink nucleoli and finely granular or clumped chromatin (Fig.2B). Solid areas were composed of uniform cells with high N:C ratio, with very scanty weakly eosinophilic cytoplasm. Nuclei with distinct nuclear membranes presented "salt and pepper" chromatin pattern, and only in part of them the nucleoli were visible (Fig.2C). Mitotic figures were numerous (Fig.2D). Single cells revealed signs of modeling. In these areas the histological picture resembled poorly differentiated squamous carcinoma. In c.a. 1/3 the tumor presented as a typical small cell neoplasm (Fig.3A). Focally, the medium-sized cells formed nests with numerous thin-walled blood vessels (Fig.3B) at their periphery or trabeculae both resembling carcinoids (Fig.3D). Additionally, a single focus of pseudoglandular structures was found (Fig.3C). The covering epithelium was normal.



**Figure 1:** Microscopical view of mucosa, covered by non-keratinizing squamous epithelium, with infiltrate of poorly differentiated small cell neoplasm in the stroma. The neoplastic cells were chromogranin A (A) and synaptophysin (B) positive. The diagnosis of high grade neuroendocrine carcinoma was established. The tumor cells were visible in neoplastic cells forming the emboli in vessels (B).



**Figure 2:** Approximately 2/3 of the cancer area were composed of medium-size cells with moderately abundant cytoplasm and mild polymorphism (A). The oval nuclei presented features of atypia, with prominent, pink nucleoli and finely granular or clumped chromatin (B). In c.a. 1/3 the cancer was small cell neoplasm in the picture. Nuclei presented "salt and pepper" chromatin pattern (C). In all visual fields multiple mitotic figures were found (D). HE

The results of immunohistochemistry were identical to that observed in previous diagnostic specimen: almost all carcinoma cells were strongly chromogranin A-positive. In about 50% of the tumor cells rather moderate positive reaction to synaptophysin was also observed in the infiltrating cells as well as in the cells forming the emboli in vessels. In differential diagnosis, squamous cell carcinoma was considered, especially its subtype – basaloid squamous carcinoma, because the areas composed of medium-sized cells. Trabecular and pseudoglandular structures may occur in both neuroendocrine and squamous carcinomas. Small cells areas and above mentioned results of immunohistochemistry were decisive for final histopathological diagnosis.

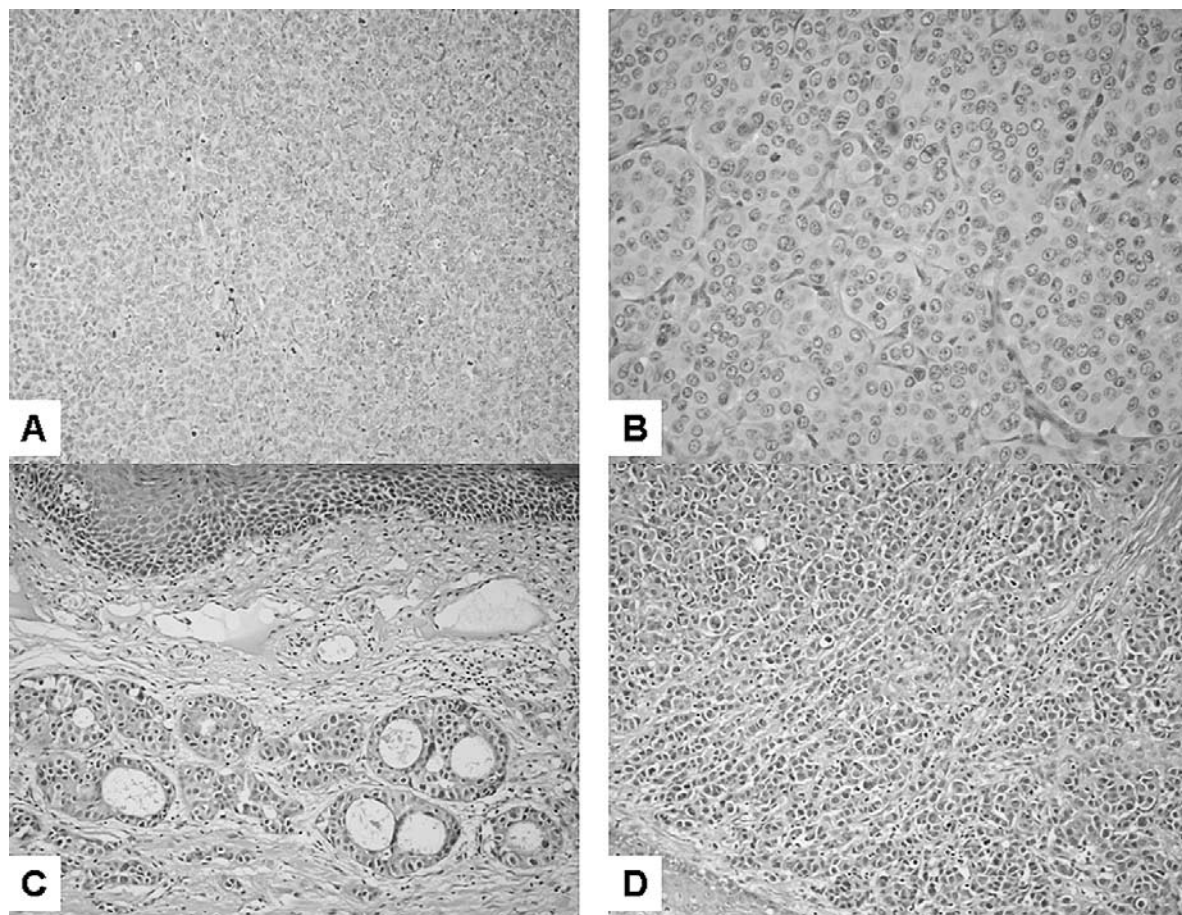
Carcinoma metastases were found in 4 out of 28 lymph nodes of the surgical material. Additional specimens from surgical margins and the piece of thyroid cartilage were free from carcinoma.

After 10 months following the surgical treatment patient remains without any symptoms of the disease.

## Discussion

The putative cells of origin of neuroendocrine epithelial type tumors are Kultchitsky cells of the bronchi which are found also in the larynx and the pluripotential endobronchial stem cells [1]. In 1938 the concept of diffused neuroendocrine system developed to interrelate tumors in several anatomical localizations with potentially secretory function and comparable morphological structure [7], the acronym APUD was used to describe the biochemical characteristics of these tumors in 1974 [9]. Exceptionally poorly differentiated neuroendocrine carcinoma may be associated with paraneoplastic syndromes including inappropriate ADH (antidiuretic hormone) secretion (Schwarz-Bartter syndrome), Eaton-Lambert syndrome (paraneoplastic myasthenic syndrome), or Cushing syndrome (ACTH syndrome) [1]. Paraneoplastic syndrome was not observed in the presented case.

Small cell neuroendocrine carcinoma occurs most commonly in the lung, only 4% of these tumors arise in extrapulmonary sites, larynx is one of the most common



**Figure 3:** In c.a. 1/3 the tumor presented as a typical small cell neoplasm (Fig.3A). The medium-sized cells formed nests with numerous thin-walled blood vessels at their periphery (Fig.3B) or trabeculae both resembling carcinoids (Fig.3D), a single focus of pseudoglandular structures was found (Fig.3C). HE

extrapulmonary site for this tumor [6,8]. The localization of presented tumor seems to be typical regarding the reported in the literature [1,2].

Small cell neuroendocrine carcinoma is the most aggressive type of neuroendocrine tumors, the prognosis is poor, it was reported in recent series that 73% of patients died with an average survival of only 9.8 months (range 1–26 months). Two- and five years survivals were 16% and 5%, respectively. Almost half of patients present with positive cervical lymph nodes at diagnosis and 60–90% will develop regional and distant metastases [1]. The treatment should be non-surgical, according to the protocols used for small-cell carcinoma of the lung the combination of radiation and chemotherapy should be used [1,2,3]. Radical surgical procedures should be avoided [3]. In the presented case because of the clinical symptoms like ulcerating tumor of epiglottis, discomfort in swallowing and unpalpable regional cervical lymph nodes, the decision of surgical treatment was undertaken; the patient underwent a horizontal laryngeal resection with bilateral neck dissection. The additional chemotherapy was applied. In our opinion surgical treatment should be considered in some cases in combination with radiation or chemical treatment, as in our case to avoid complications resulting from a disruption of un

ulcerating tumor and to protect the upper respiratory tract patency.

Since the prognosis of poorly differentiated neuroendocrine carcinomas is poor the classification criteria and treatment indications should be clear. However, the nomenclature and terminology applied to neuroendocrine tumors had been confusing for many years, following terms were historically applied: carcinoid, atypical carcinoid, Kulchitsky cell carcinoma, argentaffinoma, APUD-oma, atypical endocrine carcinoma, oat-cell carcinoma, medullary thyroid carcinoma, islet cell tumor and cutaneous Merkel cell carcinoma; as a replacement of all these terms the term neuroendocrine carcinoma was proposed [1,10]. The lack of an uniform classification might have caused misunderstanding and errors in interpretation and treatment. The division of the neuroendocrine neoplasms into four types (typical carcinoid, atypical carcinoid, small cell neuroendocrine carcinoma and paraganglioma) was proposed [5]. Next, the neuroendocrine neoplasms of the larynx were separated according the cells' origin into epithelial (including typical carcinoid, atypical carcinoid, small cell neuroendocrine carcinoma) and neural (paraganglioma) [4]. Subsequently, the neuroendocrine carcinomas were classified with respect to cells' differentiation (Grade I-

typical carcinoid, Grade II-atypical carcinoid, Grade III-small cell neuroendocrine carcinoma) [10]. The current WHO classification of tumors accepted by International Agency for Research on Cancer in 2005 systematizes the terminology and nomenclature reflecting the previous discussions concerning the classification problems and seems to be a useful task in the diagnosis and treatment of neuroendocrine laryngeal tumors [1].

In conclusion, the present case represents an example of neuroendocrine carcinoma, intermediate cell variant arising in supraglottic area of larynx, which seems to be a typical localization for these tumors within larynx. The correct pathological diagnosis required the use of immunohistochemistry. The treatment of choice was surgery combined with chemotherapy and until now, after ten months follow-up the patient remains without the symptoms of the disease.

#### REFERENCES

- 1 Barnes L, Eveson JW, Reichart P, Sidransky D. WHO Classification of Tumors. Pathology and Genetics of Head and Neck Tumors. Lyon: IARC Press. 2005. 135–139.
- 2 Douglas R. Gnepp, ed.: Diagnostic Surgical Pathology of the Head and Neck, W.B. Saunders Company, A Harcourt Health Sciences Company, Philadelphia London New York St. Louis Sydney Toronto, 2001, pp. 57–59, 281–283.
- 3 Ferlito A, Rinaldo A: The spectrum of endocrinocarcinomas of the larynx. *Oral Oncology* 2005; **41**:878–883.
- 4 Ferlito A, Rosai J. Terminology and classification of neuroendocrine neoplasms of the larynx. *ORL J Otorhinolaryngol Relat Spec* 1991; **53**:185–187.
- 5 Ferlito A, Friedmann I. Review of neuroendocrine carcinomas of the larynx. *Ann Otol Rhinol Laryngol* 1989; **98**:780–790.
- 6 Ferlito A: Diagnosis and treatment of small cell carcinoma of the larynx: a critical review. *Ann Otol Rhinol Laryngol* 1986; **95**:590–600.
- 7 Feyrter F. *Über Diffuse Endokrine Epitheliale Organe*. Leipzig: JA Barth, 1938; 1–334.
- 8 Gnepp DR: Small cell neuroendocrine cancer of the larynx: critical review of the literature. *J Otorhinolaryngol Relat Spec* 1991; **53**:210–219.
- 9 Pearse AGE. The APUD cell concept and its implications in pathology. *Pathol Annu* 1974; **9**:27–41.
- 10 Wick MR, Ritter JH. Neuroendocrine neoplasms: evolving concepts and terminology. *Curr Diagn Pathol* 2002; **8**:102–112.