

The usefulness of laparoscopy and hysteroscopy in the diagnostics and treatment of infertility

Pawel KAMINSKI, Malgorzata GAJEWSKA, Miroslaw WIELGOS, Iwona SZYMUSIK, Kinga ZIOLKOWSKA & Robert BARTKOWIAK

1st Department of Obstetrics and Gynecology, Medical University of Warsaw, Poland

Correspondence to: Ass. Prof. Miroslaw Wielgos, MD., PhD.
1st Department of Obstetrics and Gynecology, Medical University of Warsaw,
Plac Starynkiewicza 1/3, 02-015 Warsaw, Poland
PHONE: +48-22-5021421
FAX: +48-22-5022157
EMAIL: mwielgos@amwaw.edu.pl

Submitted: November 13, 2006

Accepted: November 25, 2006

Key words: laparoscopy; hysteroscopy; sterility; infertility treatment

Neuroendocrinol Lett 2006; 27(6):813–817 PMID: 17187014 NEL270606A10 ©Neuroendocrinology Letters www.nel.edu

Abstract

OBJECTIVES: The aim of the study was to analyze the use of endoscopic procedures in the group of infertile patients.

MATERIAL AND METHODS: The study material consisted of 636 patients, aged 20–41. They all had endoscopic procedures performed (laparoscopy and/or hysteroscopy) due to infertility, and were qualified for the procedure after a gynecological examination and ultrasound scan. The study group was divided into subgroups of primary and secondary sterility and endoscopic procedures were then analyzed.

RESULTS: A total of 724 endoscopic procedures were performed on 636 patients. Eighty eight women had both hysteroscopy and laparoscopy performed, 476 had only laparoscopy, while 72 – only hysteroscopy. Women diagnosed due to primary sterility more often had no visible abnormalities in the pelvic region (30%) and patent oviducts than those with secondary sterility. The remaining 70% more often had ovaries typical for polycystic ovarian syndrome and endometriosis. However, periadnexal adhesions and tubal impatency were more common in the group of secondary sterility. As to hysteroscopy, women with primary sterility more often had congenital uterine malformations, while submucosal myomas and intrauterine adhesions were less common in that group. All the surgical procedures performed during laparoscopies were analyzed. Tubal patency assessment and ovarian drilling were significantly more often performed in the subgroup of primary sterility. All intrauterine pathologies were treated during hysteroscopy.

CONCLUSIONS: Laparoscopy and hysteroscopy play an important role as both diagnostic and therapeutic tools in the infertility treatment centers.

Introduction

Sterility has become a very serious social problem nowadays, affecting up to 20% of all couples. Endoscopic procedures, such as laparoscopy and hysteroscopy, have long been considered important among clinical diagnostic tools for infertile patients. Moreover, they can also be therapeutic, not only diagnostic procedures, in cases of pathological findings limiting fecundity. Endoscopies are the type of minimally invasive surgery, shortening the diagnostic process and allowing fast postoperative recovery, which is especially important for women of reproductive age. It is worth remembering that the number of infertile patients over the age of 35 is increasing and that their age alone is an important factor confining the long-term diagnostic process. In such cases endoscopic methods are sometimes crucial for the proper diagnosis and further treatment qualification.

The aim of the study was to analyze the use of endoscopic procedures in the group of infertile patients.

Material and methods

The study material consisted of 636 patients, aged 20–41 (mean age 30.2 ± 4.4 years), admitted to the 1st Department of Obstetrics and Gynecology, Medical University of Warsaw, in the years 1996–2005, for the diagnostics and/or treatment of sterility. Both primary and secondary sterility (abortion or delivery in the anamnesis) were included in the study. The average age of patients with primary sterility was 29.4 ± 4.2 years, while with secondary – 32.1 ± 4.8 ($p < 0.05$). Laparoscopy was performed typically in general anesthesia with endotracheal intubation, while hysteroscopy in short general anesthesia. Karl Storz optics and Karl Storz, Olympus, Stryker and Pajunk instruments were used both for hysteroscopy and laparoscopy.

All the patients were examined and had a transvaginal ultrasound scan performed at admission. They were qualified for the operation based on medical history, gynecological examination, biochemical parameters and

ultrasound scan. Sterility was an indication for all laparoscopic procedures. All the pathological findings were either removed during surgery or left and only described in the protocol. Tubal patency (chromoscopy) was assessed in each patient with no previous hysterosalpingography (HSG). Hysteroscopy was performed in all women with abnormal ultrasound scans and / or HSG result prior to assisted reproduction.

The study group was divided into subgroups of primary and secondary sterility and endoscopic procedures were then analyzed. Statistical analysis was performed afterwards using t-Student test, where values of $p < 0.05$ were considered significant.

Results

In the years 1996–2005, a total of 724 endoscopic procedures (564 laparoscopies and 160 hysteroscopies) were performed on 636 patients, diagnosed and treated due to sterility. Eighty eight women had both hysteroscopy and laparoscopy performed, 476 had only laparoscopy, while 72 – only hysteroscopy (Figure 1).

Among 564 laparoscopies, the majority (430 patients) suffered from primary sterility (Figure 2). Table 1 shows the results of laparoscopic procedures in both groups. Women diagnosed due to primary sterility more often had no visible abnormalities in the pelvic region and patent oviducts than those with secondary sterility (31.4% vs 17.9%, $p < 0.05$ and 67.9% vs 43.3%, $p < 0.01$, respectively). They also more often had ovaries typical for polycystic ovarian syndrome (PCOS) (22.8% vs 8.2%, $p < 0.01$) and endometriosis (14.4% vs 6%, $p < 0.05$). However, periadnexal adhesions and tubal impatency were more common in the group of secondary sterility.

Among 160 hysteroscopies, 100 women were diagnosed due to primary and 60 due to secondary sterility (Figure 2). Table 2 shows the results of those endoscopic procedures. Women with primary sterility more often had congenital uterine malformations (16% vs 3%, $p < 0.05$), while submucosal myomas and intrauterine adhesions were less common in that group (13% vs 30%,

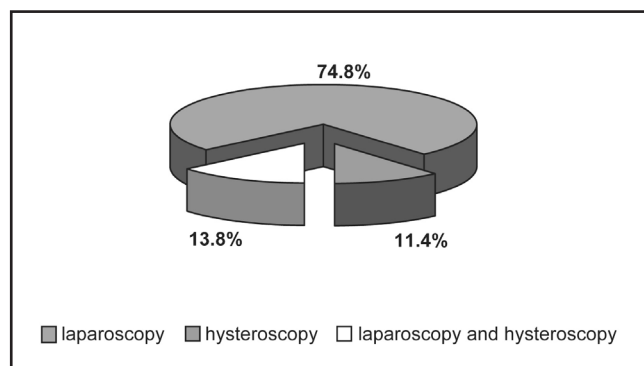


Figure 1. Types of endoscopic procedures in the study group.

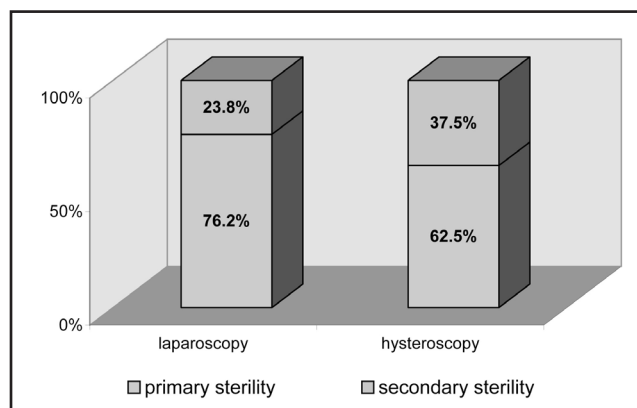


Figure 2. The number of laparoscopic and hysteroscopic procedures in the study group after the division into primary and secondary sterility.

Table 1. The outcomes of laparoscopic procedures in patients with primary and secondary sterility

The outcome of laparoscopy	Primary sterility		Secondary sterility		p
	n=430	%	n=134	%	
Both oviducts patent	292	67.9	58	43.3	<0.01
No visible abnormalities	135	31.4	24	17.9	<0.05
PCOS	98	22.8	11	8.2	<0.01
Periadnexal adhesions	76	17.7	37	27.6	<0.05
Ovarian cysts	65	15.1	21	15.7	ns
Endometriosis	62	14.4	8	6.0	<0.05
Perioviductal cysts	51	11.9	9	6.7	ns
Uterine myomas	49	11.4	12	8.9	ns
One or both oviducts not patent	46	10.7	28	20.9	<0.05
Hydrosalpinx	26	6.0	3	2.2	ns
Congenital uterine malformations	10	2.3	5	3.7	ns

Table 2. The outcomes of hysteroscopic procedures in patients with primary and secondary sterility

The outcome of hysteroscopy	Primary sterility		Secondary sterility		p
	n=100	%	n=60	%	
Normal uterine cavity	37	37	15	25	ns
Endometrial polyps	33	33	12	20	ns
Congenital uterine malformations	16	16	3	5	<0.05
Submucosal myomas	13	13	18	30	<0.05
Adhesions in the uterine cavity	1	1	12	20	<0.01

$p < 0.05$ and 1% vs 20%, $p < 0.01$, respectively). All the found abnormalities in the uterine cavity (polyps, adhesions, myomas) were removed during hysteroscopy and metroplasty was performed in each case of a diagnosed uterine septum.

All the surgical procedures performed during laparoscopies were analyzed (Table 3). Tubal patency assessment and ovarian drilling were significantly more often performed in the subgroup of primary sterility (78.6% vs 64.2%, $p < 0.05$ and 22.8% vs 8.2%, $p < 0.05$, respectively). Among all the enucleated ovarian cysts, the most common changes were: endometrial tumors in 42 (48.8%) patients, dermoid cysts in 12 (14%) and simple ovarian cysts in 7 (6%) studied women.

There were no intraoperative complications during laparoscopy or hysteroscopy. One case of fever accompanied by abdominal pain in the postoperative period was noted after laparoscopy (0.15%). The patient was administered antibiotics because adnexitis was suspected and the symptoms withdrew. There were no complications after hysteroscopic procedures.

Table 3. Procedures conducted during laparoscopies in patients with primary and secondary sterility

Procedures performed during laparoscopy	Primary sterility		Secondary sterility		p
	n=430	%	n=134	%	
Tubal patency assessment	338	78.6	86	64.2	<0.05
Ovarian drilling	98	22.8	11	8.2	<0.05
Ovarian cyst enucleation	65	15.1	21	15.7	ns
Perioviductal cyst excision	51	11.9	9	6.7	ns
Enucleation of myomas	38	8.8	6	4.5	ns
Laparoscopic adhesiolysis	36	8.4	11	8.2	ns
Salpingoplasty	17	3.9	2	1.5	ns
Salpingectomy	9	2.1	1	0.7	ns
Coagulation of endometrial lesions	8	1.9	3	2.2	ns
GIFT	6	1.4	2	1.5	ns
ZIFT	0	0	1	0.7	ns

Discussion

It is generally accepted that laparoscopy is a very important procedure in centers dealing with the diagnosis and treatment of sterility, especially in women suspected of intra-abdominal pathologies, difficult to visualize by means of other diagnostic tools, such as hysterosalpingogram or ultrasound. Moreover, laparoscopy may reveal abnormal findings also in patients with normal HSG. In literature the percentage of such cases varies from 21 to 68% and the problem has been discussed by many clinicians for years [1,4]. This high prevalence of abnormalities gives the impression that diagnostic laparoscopy might be of considerable value even when there seems to be no other indications for such a procedure. The use of endoscopy might as well contribute to the decision of which treatment should be applied – based on the severity of the laparoscopic findings, the initial treatment decision can be changed into one giving better chances of success. It especially concerns patients initially qualified for intrauterine insemination (IUI). Additional pathological abnormalities found during laparoscopy may suggest a referral to in vitro fertilization (IVF) or on the contrary – performing a fertility-improving corrective surgery, increasing the success rate after a simpler and cheaper treatment.

The above presented study describes the use of endoscopic procedures in the population of 636 infertile women, mostly with primary sterility (73%). In the study of Shokeir et al. [18] there were 300 patients (49%) with primary sterility out of 612 who had both laparoscopy and hysteroscopy performed. Hinckley et al. [8] reported the results of 1000 hysteroscopies performed because of sterility prior to IVF. One of the largest analyzed population consisted of 1584 patients with primary and

secondary sterility diagnosed over a period of 10 years in the hospital in Athens, Greece [15].

More than 30% of women with primary sterility had no visible abnormalities in the pelvic region and both oviducts patent. However, the remaining 68.6% more often suffered from endometriosis and PCOS. The occurrence of endometrial lesions in the pelvic region is quite common, but it does not necessarily lead to infertility. It can, however, significantly reduce fecundity, especially in women who have never been pregnant before – in our material endometriosis was diagnosed in almost 15% of all patients with primary sterility and in 6% with secondary sterility (12.4% of all study group – 70 women). Periadnexal adhesions were the most common laparoscopic finding in all the study group – 113 women (20%). In the study of Milingos et al., adhesions and endometriosis were also the most frequent, especially in women suffering from chronic pelvic pain (in almost 77% of them, laparoscopy revealed the above mentioned pathologies). They therefore concluded that laparoscopy is an invaluable diagnostic tool especially for symptomatic patients and should be used early in the diagnostic infertility work-up [15]. In our material endometrial peritoneal lesions were treated with laser fulguration, endometrial cysts were enucleated and adhesiolysis was performed if necessary. Endometrial cyst removal is especially important for women undergoing controlled ovarian hyperstimulation, as it increases the chances of success. There are, however, controversies as to laser fulguration [5,20]. A controlled randomized study assessing the influence of such treatment on fertility revealed an increased chance of pregnancy in the study group (OR 2.03, 95% CI 1.28 to 3.24) [9,13]. Paulson et al. also concluded that if endometriosis was diagnosed at the time of laparoscopy and was easily amenable to treatment, it should be treated at the time of surgery regardless of prior treatment and results [16]. Finally, all the researchers agree that laparoscopy is a golden standard of treatment in endometriosis stage III and IV according to AFS, especially for pain relief [17,20].

Tubal patency assessment was the most frequent laparoscopic procedure in our study group (424 women – 75%), as it is one of the crucial steps in the diagnosis of sterility. Ovarian electrocautery was the second most common procedure (109 patients – 19.3%), which is a result of a large number of diagnosed polycystic ovarian syndromes in the studied population. It was performed in patients after unsuccessful pharmacological ovulation stimulation. Gomel et al. reported that the majority of clomiphene-resistant patients became pregnant after such a procedure [7]. Cleeman et al. [3] and Marianowski et al. [14] also described ovarian drilling as an important step in PCOS treatment.

Uterine myomas were diagnosed in 61 women (10.8% of the study group) and removed in 44 (72.1%) of them. The remaining tumors were too big (or there were too many) at the time of the operation. Those patients were referred to GnRH analogues treatment prior to another laparoscopy in the future. However, there are different opinions as to the removal of myomas before

planned pregnancy. Soriano et al. reported that patients after laparoscopic myomectomy became pregnant in a much shorter time than those who were not operated or had laparotomy performed [19]. Strandell et al. concluded that the positive value of intramural or subserous myomas' removal in sterility treatment has not yet been proven [20]. Since each operation on the uterine muscle can result in cicatrices and adhesions formation, it can be an obstacle for a successful pregnancy instead of being the way of infertility treatment. Malzoni et al. stated that myomas should be removed in infertile women only when rapid growth was observed or when they were the reason of abdominal pain or irregular bleedings [11]. Their study revealed that among 26 pregnancies following myomectomy, 9 patients delivered spontaneously and there were no uterine ruptures. Kumari et al. reported that among 23 pregnant patients after myomectomy, 19 delivered spontaneously and there were also no uterine ruptures in their studied material [10].

In the above study all the women with hydrosalpinx generally had salpingectomy performed – such a procedure is said to increase the success rate of in vitro fertilization [20]. Moreover, Marchino et al. conclude that laparoscopy alone might be insufficient in predicting tubal integrity. They suggest that performing salpingoscopy during laparoscopy could increase the accuracy in predicting short-term fertility outcome [12].

As to hysteroscopy, it was performed in 160 women (25.1% of all infertile patients). More than 30% of those women had a normal uterine cavity. They usually had the procedure performed prior to in vitro fertilization after unsuccessful IUI. Hysteroscopy was also performed in infertile patients who had some abnormalities described in ultrasound examination or in HSG. Hinckley et al. reported the results of a thousand hysteroscopies in patients with primary and secondary sterility. Their results were similar to our study – the most common pathological findings in their study were endometrial polyps (32%), submucosal myomas (3%) and intrauterine adhesions (3%) – all the pathologies were also treated at the time of procedure. More than 60% of their study group, however, had normal uterine cavity [8].

Shokeir et al. reported the results of combined laparoscopy and hysteroscopy in the group of 612 infertile patients. They concluded that the number of intrauterine abnormalities found by hysteroscopy was significantly greater than by hysterosalpingography. Laparoscopy revealed significant abnormal lesions in as many as 64.3% of their study group and the rate of diagnosis rose to 76.6% when the hysteroscopic findings were included [18].

Recently, however, a few studies questioning the frequent use of laparoscopy have been published. Fatum et al. [6] and Balasch et al. [2] suggested bypassing diagnostic laparoscopy in couples with unexplained infertility and normal HSG. According to Fatum et al. [6], such patients should be treated with IUI in stimulated cycles and after 3–6 unsuccessful procedures switched directly to IVF. The researchers conclude that it is the most cost effective and efficient treatment protocol. Tanahat et al.

al. [21] analyzed 494 laparoscopic procedures in infertile women, who were initially qualified for IUI after normal HSG result. As many as 25% of those patients had additional abnormalities found during diagnostic laparoscopy, mostly periaadnexal adhesions and lesions of minimal/mild endometriosis (20.8%). The discovered abnormalities resulted in a changed treatment decision. Moreover, in the above mentioned cases laparoscopy was not only diagnostic but also a therapeutic procedure.

Conclusions

1. Laparoscopy and hysteroscopy play an important role as both diagnostic and therapeutic tools in the infertility treatment centers.
2. The percentage of abnormalities found during laparoscopy and hysteroscopy, difficult to visualize by the use of other non-invasive methods, increases the clinical value of those procedures and justifies their application.

REFERENCES

- 1 al-Badawi IA, Fluker MR, Bebbington MW. Diagnostic laparoscopy in infertile women with normal hysterosalpingograms. *J Reprod Med.* 1999; **44**(11):953–7.
- 2 Balasch J. Investigation of the infertile couple: investigation of the infertile couple in the era of assisted reproductive technology: a time for reappraisal. *Hum Reprod.* 2000; **15**(11):2251–7.
- 3 Cleemann L, Lauszus FF, Trolle B. Laparoscopic ovarian drilling as first line of treatment in infertile women with polycystic ovary syndrome. *Gynecol Endocrinol.* 2004; **18**(3):138–43.
- 4 Corson SL, Cheng A, Gutmann JN. Laparoscopy in the „normal“ infertile patient: a question revisited. *J Am Assoc Gynecol Laparosc.* 2000; **7**(3):317–24.
- 5 Donnez J, Pirard C, Smets M, Jadoul P, Squifflet J. Pre- and post-surgical management of endometriosis. *Semin Reprod Med.* 2003; **21**(2):235–42.
- 6 Fatum M, Laufer N, Simon A. Investigation of the infertile couple: should diagnostic laparoscopy be performed after normal hysterosalpingography in treating infertility suspected to be of unknown origin? *Hum Reprod.* 2002; **17**(1):1–3.
- 7 Gomel V, Yarali H. Surgical treatment of polycystic ovary syndrome associated with infertility. *Reprod Biomed Online.* 2004; **9**(1):35–42.
- 8 Hinckley MD, Milki AA. 1000 office-based hysteroscopies prior to in vitro fertilization: feasibility and findings. *JSL.* 2004; **8**(2):103–9.
- 9 Jacobson TZ, Barlow DH, Koninckx PR, Olive D, Farquhar C. Laparoscopic surgery for subfertility associated with endometriosis. *Cochrane Database Syst Rev.* 2002; **(4)**:CD001398.
- 10 Kumakiri J, Takeuchi H, Kitade M, Kikuchi I, Shimanuki H, Itoh S, Kinoshita K. Pregnancy and delivery after laparoscopic myomectomy. *J Minim Invasive Gynecol.* 2005; **12**(3):241–6.
- 11 Malzoni M, Rotond M, Perone C, Labriola D, Ammaturo F, Izzo A, Panariello S, Reich H. Fertility after laparoscopic myomectomy of large uterine myomas: operative technique and preliminary results. *Eur J Gynaecol Oncol.* 2003; **24**(1):79–82.
- 12 Marchino GL, Gigante V, Gennarelli G, Mazza O, Mencaglia L. Salpingoscopic and laparoscopic investigations in relation to fertility outcome. *J Am Assoc Gynecol Laparosc.* 2001; **8**(2):218–21.
- 13 Marcoux S, Maheux R, Berube S. Laparoscopic surgery in infertile women with minimal or mild endometriosis. *Canadian Collaborative Group on Endometriosis. N Engl J Med.* 1997; **337**(4):217–22.
- 14 Marianowski P, Kaminski P, Wielgos M, Szymusik I. The changes of hormonal serum levels and ovulation/pregnancy rates after ovarian electrocautery in microlaparoscopy and laparoscopy in patients with PCOS. *Neuro Endocrinol Lett.* 2006; **27**(1–2):214–8.
- 15 Milingos S, Protopapas A, Kallipolitis G, Drakakis P, Makriganakis A, Liapi A, Milingos D et al. Laparoscopic evaluation of infertile patients with chronic pelvic pain. *Reprod Biomed Online.* 2006; **12**(3):347–53.
- 16 Paulson JD, Habli M, Alizade A, Borromeo R. The treatment of mild endometriosis with laser laparoscopy: a two-step treatment analysis of patients whose primary therapy was successful. *JSL.* 2006; **10**(1):30–6.
- 17 Panel P, Chis C, Gaudin S, Letohic A, Raynal P, Mikhayelyan M, Fraleu B et al. [Laparoscopic surgery of deep endometriosis. About 118 cases.] [Article in French with an English abstract] *Gynecol Obstet Fertil.* 2006; **34**(7–8):583–92.
- 18 Shokeir TA, Shalan HM, El-Shafei MM. Combined diagnostic approach of laparoscopy and hysteroscopy in the evaluation of female infertility: results of 612 patients. *J Obstet Gynaecol Res.* 2004; **30**(1):9–14.
- 19 Soriano D, Dessolle L, Poncelet C, Benifla JL, Madelenat P, Dairai E. P regnancy outcome after laparoscopic and laparoscopic converted myomectomy. *Eur J Obstet Gynecol Reprod Biol.* 2003; **108**(2):194–8.
- 20 Strandell A. Surgery in contemporary infertility. *Curr Womens Health Rep.* 2003; **3**(5):367–74.
- 21 Tanahatooe SJ, Hompes PG, Lambalk CB. Investigation of the infertile couple: should diagnostic laparoscopy be performed in the infertility work up programme in patients undergoing intrauterine insemination? *Hum Reprod.* 2003; **18**(1):8–11.