

An alternative management for growth retarded fetus with absent end-diastolic velocity in umbilical artery and normal cardiotocography

Vladimír FERIANEC¹, Mikuláš REDECHA¹, Ingrid BRUCKNEROVÁ²,
Ivan HOLLÝ¹, Karol HOLOMÁNĚ¹

1. 2nd Department of Obstetrics and Gynecology, School of Medicine, Comenius University, Bratislava, Slovak Republic
2. 1st Department of Paediatrics, Comenius University, School of Medicine, Comenius University, Bratislava, Slovakia Republic

Correspondence to: Vladimír Ferianec, MD., PhD
2nd Department of Obstetrics and Gynecology
School of medicine, Comenius University
826 06 Bratislava, Ružinovská 6, Slovak Republic
TEL.: +421 905385670
E-MAIL: ferianec@hotmail.com

Submitted: 2008-06-30 Accepted: 2008-09-12

Key words: IUGR; Doppler; flowmetry; cordocentesis; oligohydramnion; cardiotocography

Neuroendocrinol Lett 2008; 29(5):635–638 PMID: 18987611 NEL290508A09 ©2008 Neuroendocrinology Letters • www.nel.edu

Abstract

OBJECTIVES: Intrauterine growth retardation (IUGR) is associated with fetal adverse conditions. The most important cause of growth restriction and poor perinatal outcome is chronic fetal hypoxemia (CFH). Adaptation to CFH can be studied by Doppler velocity waveform on umbilical and fetal arteries and cardiotocography (CTG).

METHODS: Preterm delivery, as an elimination of CFH, has to be confronted with the risks of prematurity. A special situation may occur when CTG is normal at the absence of end-diastolic velocity (AEDV). AEDV in the umbilical artery precedes the onset of abnormal CTG, whose duration differs considerably among the fetuses. The time after the onset of AEDV in pregnancy may be utilized for performing exact diagnosis by fetal blood analysis.

CASE: Primigravida at 30 gestational weeks was referred because of IUGR. IUGR, AEDV, oligohydramnion, and normal fetal anatomy were revealed. CTG was normal. Indication for cordocentesis was to perform cord blood gases analysis and to obtain fetal karyotype. Cordocentesis revealed normal karyotype, values of pH, and fetal blood gases were considered satisfactory. Continuation of pregnancy was decided in spite of persistent AEDV. At 33 gestational weeks pathological CTG was an indication for induction of labor. Labor, delivery, umbilical blood gases, postpartal and neonatal outcome were normal.

CONCLUSION: In the case of fetal monitoring controversy assessment of umbilical blood analysis may be crucial. This examination is significant and independent of the interval between cordocentesis and the onset of CTG pathology. This interval may be utilized for intrauterine treatment and for optimizing obstetric management.

INTRODUCTION

Decision for preterm delivery is very difficult in the cases of expected prematurity of the fetus with the diagnosis of chronic fetal malnutrition. The goal is to prevent intrauterine fetal hypoxemia and acidosis and to overcome the factors causing harm to the fetus and the newborn. Fetuses with intrauterine growth retardation (IUGR) are typical example of the described situation. Fetal biometrical measurement cannot distinguish the cause of the growth retardation, nor because of limited haemodynamic situation neither because of other reasons like chromosomal aberrations (Wienerroither *et al.*, 2001). Pathological blood flow in fetoplacental unit is easily observed using Doppler technology by analysing the characteristics of the Doppler velocity waveform (DVWF). By studying DVWF on umbilical and fetal arteries it is possible to assess the characteristics of the blood flow from mother to the fetus and to monitor the aspects of the fetal adaptation if CFH is present. If present, it is possible to monitor the evolution obtaining information of clinical validity in order to optimize the management and the timing of the delivery, if necessary. This pathological situation can be caused for example by haemodynamic placental insufficiency (Šuška, 1995; Foltinova *et al.*, 2007).

However, Doppler flowmetry is not the only way to monitor fetal condition. Therefore, some situations can bring controversy when Doppler flowmetry results are in controversy to the results of cardiotocography (CTG). It is therefore necessary, to evaluate objectively the fetal condition and to set the optimal management, especially in cases of premature fetus (Schwarze *et al.*, 2005; Urdzík *et al.*, 2007).

Cordocentesis can be performed in the case of fetus with serious IUGR in order to get fast caryotype and to analyze blood gases and pH level in the umbilical blood (Arduini *et al.*, 1996, Ferianec *et al.*, 2000; Figueras *et al.*, 2005). Its efficacy is evident in cases of unclear or opposite results from different fetal monitoring modalities. Cordocentesis offers information that cannot be gained

by any other diagnostic method. It can be helpful to set the best management for both, the monitored fetus and indirectly for the mother, with minimal risk taken.

The aim of this article is to present, in specific clinical case, possible diagnostic and therapeutic guideline in this controversial situation.

CASE

33-year-old woman, first time pregnant, was sent to our clinic in the 31th week of pregnancy with the suspicion of oligohydramnion. Ultrasound examination proved the result: oligohydramnion, fetal hypotrophy with severe flowmetry defect – AEDV (absent end diastolic velocity) (Figure 1). The patient was admitted to the hospital, taken blood samples for blood examination and was set for continual CTG monitoring. The CTG showed normal, reactive curve during the whole monitoring time without contractions of the uterus (Figure 2). Because the Doppler flowmetry remained pathological throughout 24 hours – AEDV persisted, we performed invasive prenatal diagnostics – cordocentesis, despite physiological CTG in order to get fast caryotype, umbilical blood pH, and fetal blood gases. At the same time we performed amniocentesis to evaluate the maturity of the fetus.

Cordocentesis and amniocentesis were performed without complications. We have considered the results of the umbilical blood analysis to be satisfactory and therefore decided for expectant management. Thereafter we got the results of fetal maturity L/S – 1.5 and AF Krea – 157, that proved the expectant management as a good decision with regard to the fetal immaturity (Table 1).

Fast caryotypisation of the umbilical blood proved normal male caryotype. During the remaining time of the pregnancy the pathological Doppler waveform persisted to the mentioned degree and the CTG showed no pathology at all.

In the 33th week CTG showed some pathological patterns in the means of periodic early decelerations. After lung maturity induction we induced the delivery in the

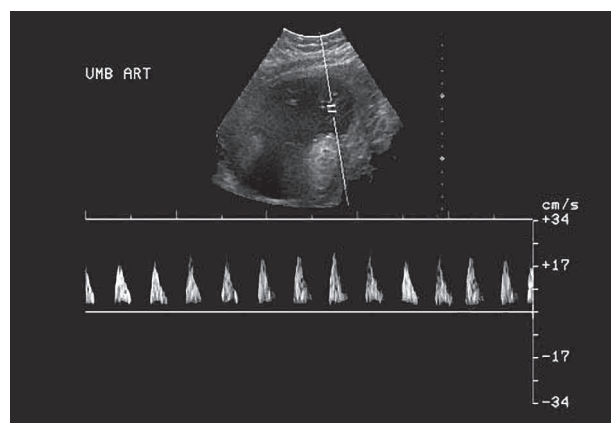


Figure 1. AEDV at the time of admittance

Table 1. Summary results from invasive prenatal diagnostics

Amniocentesis + cordocentesis			Normal fetus
Results			
L/S ratio	1.5		Over 2.0
AB	pH	7.39	7.38–7.42
	pCO ₂	4.85 kPa	4.6–6.0
	HCO ₃	21.5 mmol/l	21–29
	BE	–2.8 mmol/l	–2 to +2
	pO ₂	2.72 kPa	2.8–4.4
	sO ₂	50.3%	
Caryotype	46XY		

33th week of pregnancy with the mature cervical status. The patient was set to continual CTG monitoring during I. and II. stage of the delivery. The delivery lasted 5 hours without severe CTG pathology (Figure 3). Newborn, male, with the Apgar scoring: 8, 9, 10. Postpartal newborn's blood gases and pH were in the physiological range. Morphological examinations of placenta and umbilical cord, which was twisted ones around newborn's neck, were normal. Following histopathological examination of the umbilical cord and placenta did not find any pathology. Postpartal course of the mother and the fetus were physiological.

DISCUSSION

Histopathological findings suggest that AEDV in umbilical arteries is associated with placental lesions characteristic for reduction in number of arterioles in tertiary villy (Giles *et al.*, 1985). As a result, the exchange of oxygen and nutrition through placenta is reduced which causes alteration in acidobasic homeostasis in umbilical blood (Nicolaidis *et al.*, 1988). This state is associated with higher perinatal morbidity and mortality.

AEDV in umbilical artery usually precedes fetal heart rate alterations. However, the length of this preceding period cannot be exactly set (Arduini *et al.*, 1993; Fairle *et al.*, 1991; Ghidini *et al.*, 1993). One study reports that AEDV precedes CTG alteration with a latency of 0 – 35 days (Chaoui *et al.*, 1991).

Based on these facts, we suggest examining umbilical blood in fetus with IUGR in order to diagnose acidobasic status of the fetus and to specify the length of the period that precedes the onset of fetal distress (Figure 4).

It is obvious that cordocentesis is an invasive procedure with its relative risks especially for fetuses with IUGR (Ghidini *et al.*, 1993). However, the final benefit, potentially gained by this process, highly exceeds its potential risks. The best-known fact is that up to 8 % of fetuses with AEDV in umbilical artery have abnormal caryotype, which is difficult to diagnose by sonographic

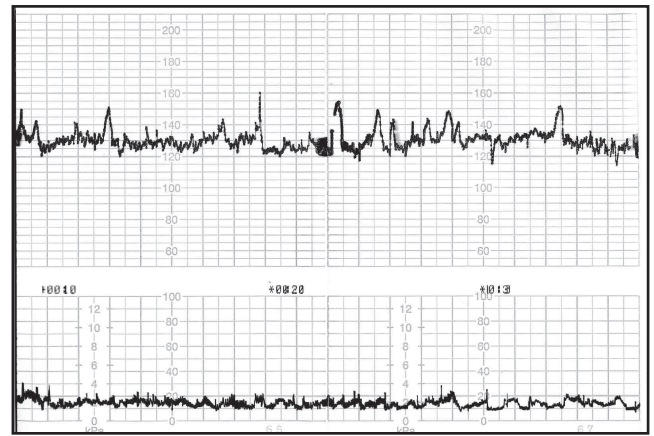


Figure 2. CTG at the time of admittance

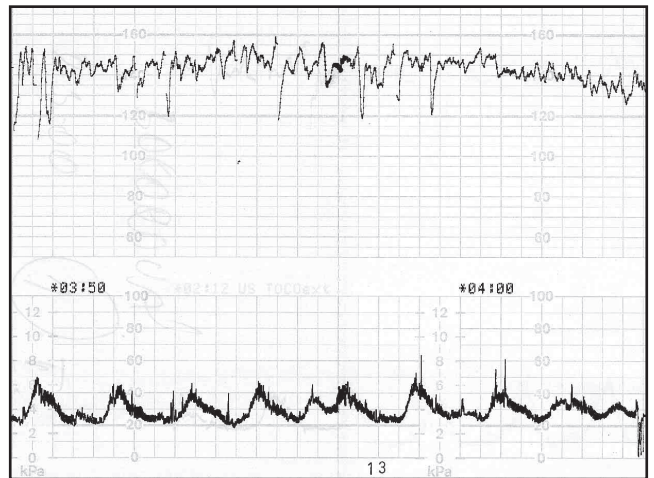


Figure 3. Intrapartal CTG record

and Doppler examination (Rizzo *et al.*, 1994; Ferianec *et al.*, 2000; Hecher *et al.*, 2001; Mari *et al.*, 2007). In these cases it is therefore indicated, in order to reduce unwanted surgical procedures (cesarean section), to perform fast examination of fetal caryotype. Simultaneous examination of pH in umbilical blood seems to be useful (Figure 5).

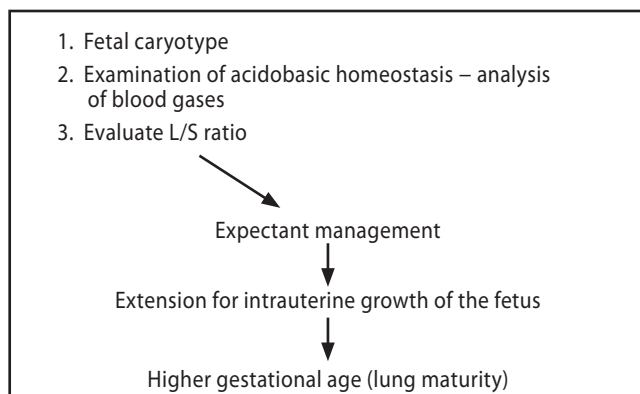


Figure 4. Use of the results from invasive diagnostics in the management

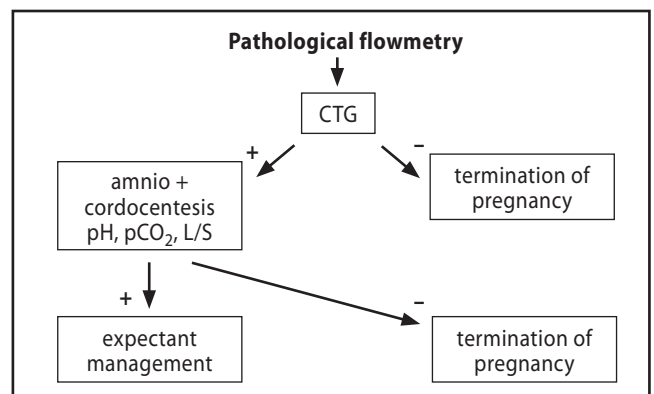


Figure 5. Management of fetus with pathological flowmetry

CONCLUSION

Up to 8% of fetuses with IUGR and AEDV may have an abnormal karyotype. Its rapid acquisition by fetal blood sampling is indicated to avoid unnecessary interventions. In the case of normal karyotype a simultaneous assessment of the fetal umbilical blood analysis is very useful for these fetuses. This kind of examination is very significant and independent to the interval between cordocentesis and the onset of cardiotocographic pathology. This interval may be utilized for intrauterine treatment, exact monitoring of the fetal wellbeing and to optimize obstetric management. The acidobasic state of the fetus is significant and does not necessarily rely on the time period between the onset of AEDV in umbilical artery and appearance of CTG pathology. The real significance of this information for everyday clinical management in these fetuses needs to be evaluated in future prospective trials.

REFERENCES

- 1 Arduini D, Rizzo G, Capponi A, Rinaldo D, Romanini C (1996). Fetal pH determined by cordocentesis: an independent predictor of the development of antepartum fetal heart rate late decelerations in growth retarded fetuses with absent end-diastolic velocity in umbilical artery. *J Perinat Med.* **24**: 601–607.
- 2 Arduini D, Rizzo G, Romanini C. The development of abnormal heart rate patterns after absent end-diastolic velocity in umbilical artery: analysis of risk factors (1993). *Am J Obstet Gynecol.* **168**: 43–48.
- 3 Fairle FM, Moretti M, Walker JJ, Sibai BM (1991). Determinants of perinatal outcome in pregnancy – induced hypertension with absence of umbilical artery end-diastolic frequencies. *Am J Obstet Gynecol.* **164**: 1084–1089.
- 4 Ferianec V, Pohlodek K, Holáň M, Kostolný I, Holomáň K, Halásová E (2000). Význam kordocentézy u plodu s IUGR. [(Importance of cordocentesis in IUGR.) (In Slovak.)] Proceedings of the VII. International Congress of Slovak Gynecological Society; May 24–27; Bratislava, Slovakia.
- 5 Figueras F, Eixarch E, Meler E, Palacio M, Puerto B, Coll O, Figueras J, Cararach V, Vanrell AJ (2005). Umbilical artery Doppler and umbilical cord pH at birth in small-for-gestational-age fetuses: valid estimate of their relationship. *J Perinat Med.* **33**: 219–25.
- 6 Foltinová J, Foltin V, Neu E (2007). Occurrence of lead in placenta – important information for prenatal and postnatal development of child. *Neuroendocrinol Lett.* **28**: 335–340.
- 7 Ghidini A, Sepulveda W, Lockwood C, Romero R (1993). Complications of fetal blood sampling. *Am J Obstet Gynecol.* **168**: 1339–1342.
- 8 Giles WB, Trudinger BJ, Baird P (1985). Fetal umbilical artery velocity waveforms and placental resistances: pathological correlation. *Br J Obstet Gynaecol.* **92**: 31–36.
- 9 Hecher K, Bilardo CM, Stigter RH, Ville Y, Hackelöer BJ, Kok HJ, Senat MV, Visser, GH (2001). Monitoring of fetuses with intrauterine growth restriction: a longitudinal study. *Ultrasound Obstet Gynecol.* **18**: 564–70.
- 10 Chaoui R, Hoffmann H, Zienert A, Bollmann R, Halle H, Grauel EL (1991). Clinical significance and fetal outcome in end-diastolic decreased flow in the umbilical artery and/or fetal aorta: analysis of 51 cases. *Geburtshilfe Frauenheilkd.* **51**: 532–539.
- 11 Mari G, Hanif F, Kruger M, Cosmi E, Santoloya-Forgas J, Treadwell MC (2007). Middle cerebral artery peak systolic velocity: a new Doppler parameter in the assessment of growth-restricted fetuses. *Ultrasound Obstet Gynecol.* **29**: 310–6.
- 12 Nicolaides KH, Bilardo CM, Soothill PW, Campbell S (1988). Absence of end diastolic frequencies in umbilical artery: a sign of fetal hypoxia and acidosis. *Br Med J.* **297**: 1026–1033.
- 13 Rizzo G, Pietropolli A, Capponi A, Arduini D, Romanini C (1994). Chromosomal abnormalities in fetuses with absent end-diastolic velocity in umbilical artery: analysis of risks factors for an abnormal karyotype. *Am J Obstet Gynecol.* **171**: 827–831.
- 14 Schwarze A, Gembruch U, Krapp M, Katalinic A, Germer U, Axt-Fliedner R (2005). Qualitative venous Doppler flow waveform analysis in preterm intrauterine growth-restricted fetuses with ARED flow in the umbilical artery correlation with short-term outcome. *Ultrasound Obstet Gynecol.* **25**: 573–9.
- 15 Šuška P (1995). Placentárna insuficiencia. [(Placental insufficiency.) (In Slovak)] In: Šuška P. *Patológia placenty a jej klinický význam.* 1st ed. Bratislava: Slovak Academic Press, p. 124–144.
- 16 Urdzík P, Dankovčík R, Ostró A, Lazár Igor (2007). Prediction of intrauterine growth retardation using the integrated test markers. [In Slovak with English abstract] *Česká gynekol.* **72**(4): 268–279.
- 17 Wienerroither H, Steiner H, Tomaselli J, Lobedanz M, Thun-Hohenstein L (2001). Intrauterine Blood Flow and Long-Term Intellectual, Neurologic, and Social Development. *Obstet Gynecol.* **3**: 449–453.