

# Clinical value of real time 3D sonohysterography and 2D sonohysterography in comparison to hysteroscopy with subsequent histopathological examination in perimenopausal women with abnormal uterine bleeding

Dariusz KOWALCZYK<sup>1</sup>, Wojciech GUZIKOWSKI<sup>1,2</sup>,  
Jacek WIĘCEK<sup>1</sup>, Urszula SIOMA-MARKOWSKA<sup>3</sup>

<sup>1</sup> Gynecologic - Obstetrical and Neonates Hospital Opole, Poland

<sup>2</sup> Public Higher Medical Professional School Opole, Poland

<sup>3</sup> Department of Gynecology and Obstetrics, The School of Health Care, Medical University of Silesia, Katowice, Poland

*Correspondence to:* Dariusz Kowalczyk, MD., PhD.  
Gynecologic - Obstetrical and Neonates Hospital Opole  
ul. Reymonta 8, 45-056 Opole, Poland.  
TEL: +48 077 4545401; E-MAIL: kowdarius@poczta.onet.pl

*Submitted:* 2012-01-27 *Accepted:* 2012-03-09 *Published online:* 2012-04-25

*Key words:* abnormal uterine bleeding; sonohysterography; transvaginal ultrasound

Neuroendocrinol Lett 2012; **33**(2):212-216 PMID: 22592204 NEL330212A13 ©2012 Neuroendocrinology Letters • [www.nel.edu](http://www.nel.edu)

## Abstract

**OBJECTIVE:** In many publications the transvaginal ultrasound is regarded as the first step to diagnose the cause of uterine bleeding in perimenopausal women. In order to improve the sensitivity and specificity of the conventional ultrasound physiological saline solution was administered to the uterine cavity and after expansion of its walls the interior uterine cavity was examined. And this procedure is called 2D sonohysterography (SIS 2D). By the ultrasound scanners which enable to get 3D real time image a spatial evaluation of the uterine cavity is possible. Clinical value of the real time 3D sonohysterography and 2D sonohysterography compared to hysteroscopy with histopathological examination in perimenopausal women.

**MATERIAL AND METHODS:** The study concerned a group of 97 perimenopausal women with abnormal uterine bleeding. In all of them after a standard transvaginal ultrasonography a catheter was inserted into the uterine cavity. After expansion of the uterine walls by administering about 10 ml of 0,9% saline solution the uterine cavity was examined by conventional sonohysterography. Then a 3D imaging mode was activated and the uterine interior was examined by real time 3D ultrasonography. The ultrasound results were verified by hysteroscopy, the endometrial lesions were removed and underwent a histopathological examination. **RESULTS:** In two cases the SIS examination was impossible because of uterine cervix atresion. In the rest of examined group the SIS 2D sensitivity and specificity came up to 72 and 96% respectively. In the group of SIS 3D the sensitivity and specificity reached 83 and 99% respectively.

**CONCLUSIONS:** Adding SIS 3D, a minimally invasive method, to conventional sonohysterography improves the precision of diagnosis of endometrial pathology, allows to get three-dimensional image of the uterine cavity and enables examination of endometrial lesions. The diagnostic precision of this procedure is similar to the results achieved by hysteroscopy.

## INTRODUCTION

The beginnings of transvaginal sonography reach the fifties of the last century when Wild and Red found and described the use of presentation A in transvaginal and transrectal transducers. The practical advantages of transvaginal (TV-USG) were barely used in 1985 when KreutzTechnik® presented the first transvaginal transducer with real time image. In the next years several producers tried to improve the image received by this way (Phillips 1986, Aloka 1987). From this time on increasing interest in transvaginal ultrasonographic diagnosis in gynecology was observed. In the last years the possibilities of ultrasound diagnosis were enhanced by ultrasound imaging of Doppler flowmetry and 3D real scans. These possibilities are used as well in the transvaginal ultrasonography and in imaging of uterine cavity after their expansion by saline solution – this procedure is called sonohysterography (SIS). This method introduced by Randolph *et al.* who achieved higher sensitivity and specificity in diagnosing of pathology of uterine cavity (Randolph *et al.* 1986).

Today the SIS technique is commonly used in diagnosis of endometrial pathology (Fakuda *et al.* 1993; Goldstein *et al.* 1997; Goldstein *et al.* 2002; Kowalczyk 1999; Parsons & Lense 1993). Introducing ultrasonography to clinical praxis allows obtaining real time 3 dimensional image enabled the spatial assessment of uterine cavity.

In many publications the transvaginal ultrasonography is used as the first step in the diagnosis of cause of uterine bleeding in the perimenopausal women (Bakos & Heimer 1998; Bedner & Rzepka-Górska 2002; Davidson & Dubinsky 2003; Oriol & Schragr 1999).

In the last years there occurred publication which asses and compare sensitivity and specificity of 2D and 3D sonohysterography and diagnostic hysteroscopy.

## OBJECTIVE

In this paper we tried to evaluate the clinical significance of the real time 3D sonohysterography and 2D sonohysterography compared to hysteroscopy with histopathological examination in women with perimenopausal uterine bleeding.

## MATERIAL AND METHODS

In the time from January 1<sup>st</sup> through December 31<sup>st</sup> 97 women hospitalized because of perimenopausal uterine bleeding were examined. The age of these patients was 43 to 57 years; the mean age was 51 years.

Before the examination each patient was administered 600 mg of ibuprofen. In all patients a standard ultrasound transvaginal ultrasonography was performed and the middle echo of endometrium was assessed.

Then the external uterine cervix os was shown in the specula and under sterile conditions was inserted a thin, (0.2 mm) flexible catheter into the uterine cavity. In cases of a broad cervical canal a balloon catheter was used in order to seal it up. Through the catheter to the uterine cavity was administered approximately 10 ml of physiological saline solution which temperature was 37°C. After the expansion of uterus walls the uterine cavity was assessed by sonohysterography (SIS 2D) and next by real time 3D ultrasonography (SIS 3D). On the basis of ultrasonographic examination results the patients were qualified to one of the following groups: 1 – endometrial hyperplasia, 2 – endometrial polyp or polyps, 3 – submucosal fibroma, 4 – normal uterine cavity.

After finishing the ultrasonographic examinations the obtained three dimensional images allowed an additional working using the post-processing option. All patients underwent Bettocchi method hysteroscopy (fluid medium, diameter of hysteroscopy telescope 5 mm and 4mm (Bettocchi *et al.* 2003).

The uterine cavity was assessed and the results of ultrasonographic examination were verified. If a lesion was found bigger than 2 cm in size, like fibroma or polypus, in order to avoid difficulties in operating resectoscope rather than thin hysteroscope was used. The other pathological lesions were removed with scissors, clamps or Versapiont® electrode. The removed underwent histopathological examination. The hysteroscopic examinations and histopathological findings made the ground to asses two methods of ultrasound imaging – SIS and SIS 3D.

The results were statistically analyzed with use of Chi<sup>2</sup> test and dependence between used method and detectability of pathology was calculated. The non-parametric Chi<sup>2</sup> test is used to compare a pair of results regarding two criteria. So in the paper were regarded two methods (for instance 3D and hysteroscopy) and next the detectability/non detectability of lesions

## RESULTS

97 patients underwent the examination. The examples of images achieved in the transvaginal ultrasonography and sonohysterography are shown in the following pictures (Figures 1–4).

In the ultrasonographic examinations beside a normal mucosa there were found following changes: thickened endometrium, endometrial polyp or polyps, submucosal fibroma. The type of changes found with different ultrasonographic methods are shown in table 1. In two patients the SIS examination was impossible to examine because of cervical canal atresia.

In two cases on the SIS 2D examination a polypus proliferation was suspected, the same diagnose was made in three cases on SIS 3D examination and one case of endometrial proliferation was found. Finally in hysteroscopy endometrial polyps were diagnosed.

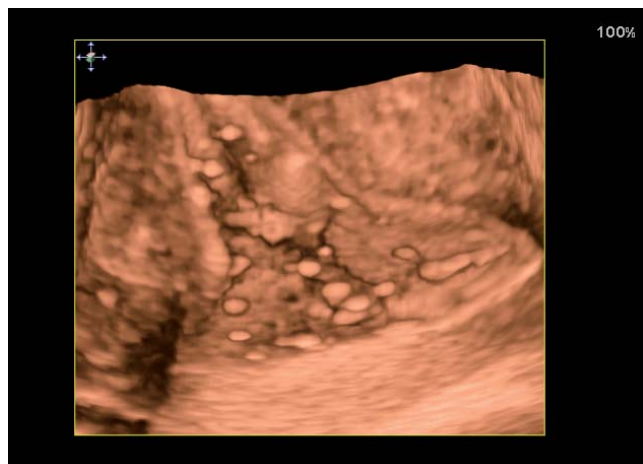


Fig. 1. Normal uterine cavity in SIS 3D.

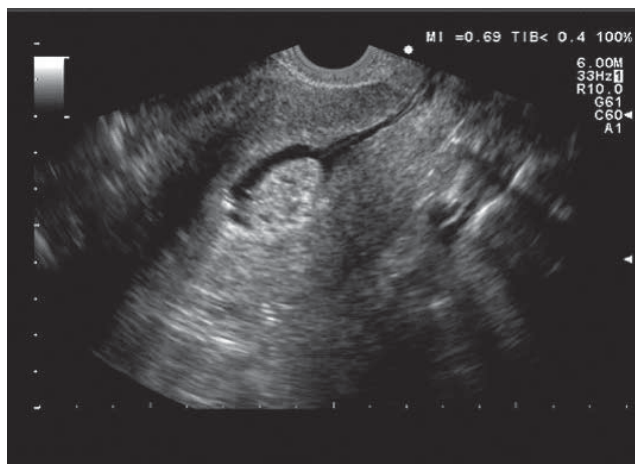


Fig. 2. Endometrial polyp seen in SIS 2D.

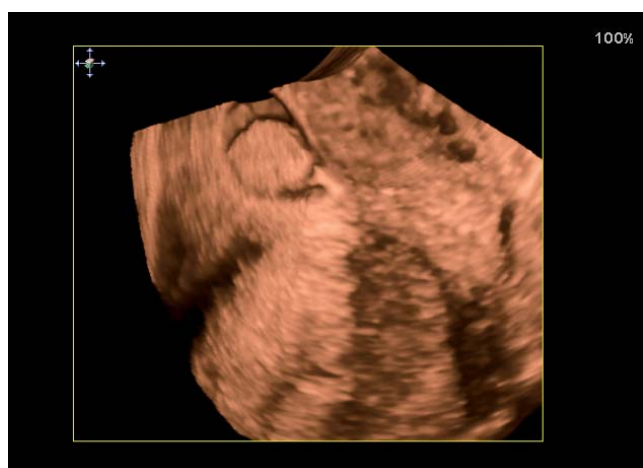

Fig. 3. The same polyp seen in SIS 3D.

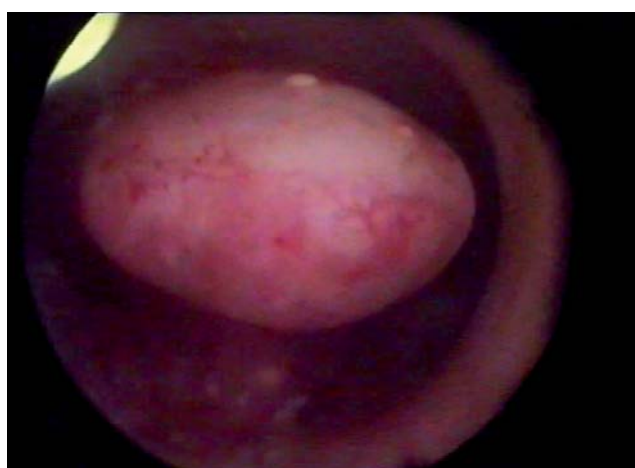

Fig. 4. The same polyp seen in hysteroscopy.

In the hysteroscopy all local changes (polyps, fibroids) were diagnosed. All the results are shown in Tables 1 and 2.

In the studied group the sensitivity and specificity of SIS 2D was respectively 72% and 98%, in the SIS 3D examination the sensitivity was 72% and specificity 99%.

The Chi<sup>2</sup> test analysis of SIS 2D in comparison with SIS 3D that in cases of endometrial hyperplasia the diagnosis does not depend on the method used. The statistical detectability is statistical significant if SIS 2D and histopathological examination or SIS 3D and histopathological examination are compared. In the histopathological findings dominated proliferation of endometrium or its simple hyperplasia and also endometrial polyps.

The efficacy of detectability of endometrial polyp is similar if SIS 3D and hysteroscopy are compared. It is to emphasize that in two cases that in two cases SIS 2D examination endometrial polyps were not shown, which were seen in the SIS 3D method and it was confirmed in the hysteroscopy. In both cases small polyps were located in the uterine horn and in SIS 2D exami-

nation they could not be seen so easily as in SIS 3D examination. In one of the polyps in the histopathological examination was found an endometrial carcinoma.

In cases of submucosal fibroma the detectability does not depend on used method (the results are similar). Similar as in case of polyps in SIS 2D presentation one case of submucosal fibroma was not detected. However it is to emphasize, that using SIS technic, 2D or 3D, the detectability of endometrial changes is much higher than in classical ultrasonography.

If SIS 2D and SIS 3D presentations are compared with hysteroscopy/histopathology the diagnosis of normal uterine cavity depends on the used method. Using the classical 2D ultrasonography a normal uterine cavity was diagnosed in 10 cases, in SIS 2D presentation – 29 cases and in SIS 3D – 22 cases. After verification of these results by hysteroscopy only in 7 cases a normal endometrium was found. In all other cases different kinds of endometrial proliferation was found and confirmed by histopathologic examination. It is to emphasize that in 9 cases it was difficult to assess the uterine cavity by classical ultrasonography whereas the image was very clear in SIS 2D and SIS 3D (Table 1).

**Tab. 1.** Visualization of the uterine cavity.

Kind of examination	Evaluation of uterine cavity			
	Efficient		Difficult	
	n	%	n	%
TV-USG (n=97)	88	90.2	9	9.8
SIS 2D (n=95)	93	97.9	2	2.1
SIS 3D (n=95)	94	98.9	1	1.1

**Tab. 2.** Presentation of achieved results.

	TV-USG n=97	SIS 2D n=95	SIS 3D n=95	HCS n=95	Histo- pathology n=95
Proliferation of endometrium	56	48	53	66	66
Sensitivity/ specificity	85%/ 75%	72%/ 94%	82%/ 97%	100%/ 100%	
Endometrial polyp/polyps	15	11	13	14	14
Sensitivity/ /specificity	100%/ 98%	78%/ 100%	92%/ 100%	100%/ 100%	
Submucosal fibromas	7	5	6	8	8
Sensitivity/ /specificity	87%/ 98%	62%/ 100%	75%/ 100%	100%/ 100%	
Normal uterine cavity	10	29	22	7	7
Specificity	97%	50%	68%		
Difficult to evaluate	9	2	1		

## DISCUSSION

In women with perimenopausal uterine bleeding transvaginal ultrasonography should be performed as a standard diagnostic method before undertaking uterine cavity curettage or hysteroscopy. With transvaginal transducer about 20% of polyps may be missed whereas contrasting medium (SIS) allows to diagnose accurately almost all of them (Dueholm *et al.* 2001). Quite lately the endometrial polyps were dominantly assenting as a benign lesions however the recent investigations show that malignancy in polyps may be found even in over 13% of cases (Martin-Ondarza *et al.* 2005). On the basis of data in the actual literature and own experience it is to emphasize a high efficacy of SIS 2D and 3D in diagnosis of endometrial polyps. Introducing into the uterine cavity a contrast medium such as physiological saline solution allows a proper qualification the patients to further diagnostic procedures, for instance curettage or hysteroscopy.

The authors of this method consider that it may replace the diagnostic hysteroscopy. Dueholm *et al.* on the basis of prospective analysis of 470 patients compared the sensitivity and specificity of sonohysterography and classic transvaginal ultrasonography (Dueholm *et al.* 2001). They found a sensitivity 0.99 and specificity 0.92 of SIS compared to TV-USG 0.72 and 0.62 respectively. Till now only few papers show, that the 3D imaging with administering of physiological saline solution (SIS 3D) increases the range of information about the assessed endometrial pathology. Our observations confirm this thesis, with SIS 3D technic it was possible to get an uterine cavity image in 98.8% whereas in classic ultrasonography only in 90.2% of cases.

The Hindu authors (Nanda *et al.* 2002) assessed the accuracy of TV-USG and SIS in diagnosis of polyps and submucosal fibromas in 40 women with pathological uterine bleeding. They have shown a high utility of SIS (sensitivity 100%, specificity 97.8%) versus TV-USG (sensitivity 66.6%, specificity 100%).

Epstein *et al.* in 105 women with postmenopausal bleeding and endometrial thickness >5 mm performed a conventional USG, SIS and hysteroscopy (Epstein *et al.* 2001). The consistence of SIS and hysteroscopy was 96%. They consider SIS to be comparable with hysteroscopy in diagnosis of local proliferation of endometrium however SIS can't be used as hysteroscopy in differentiation of benign and malignant lesions.

Tamanaha *et al.* reports that SIS in diagnosis of endometrial polyps show a sensitivity of 89.7% and specificity of 81.0%, in diagnosis of adhesions sensitivity 81.0%, specificity 97.7%, in diagnosis of submucosal fibromas sensitivity 83.3%, specificity 97.7%, in diagnosis of endometrium thickness sensitivity 33.3%, specificity 89.4% (Tamanaha *et al.* 2004). The results show that SIS achieves a high consistence with hysteroscopy in diagnosis of endometrial adhesions, submucosal fibromas and endometrial polyps however a low consistence in diagnosis of endometrium thickness (we confirmed it in our analyzed group). Our data show the lowest sensitivity and specificity of this method in cases of endometrial proliferation; however the correlation of diagnosis in cases of polyps and/or submucosal fibroma of type 0 and I according to Wamsteker classification was nearly 100% (Campo *et al.* 2005).

The Greek authors on the basis of SIS 3D examination verified by hysteroscopy in 242 women have shown in SIS 3D a sensitivity 93.5% and specificity 99.4%, in the hysteroscopy respectively 98.7% and 99.4%. They emphasize that SIS 3D allows a precise assess of endometrial pathology. Makris *et al.* performed in 124 women examination with SIS 2D, SIS 3D and 3D Power Doppler technique with subsequent hysteroscopic verification (Makris & Kalmantis *et al.* 2007; Makris & Skartados *et al.* 2007). In the SIS 2D technique the sensitivity was 91.9% and specificity 98.8%. Both techniques SIS 3D and 3D Power Doppler precisely images

the endometrial abnormalities. Evaluating the SIS 3D they stated sensitivity 93.5% and specificity 99.4%.

Also in the Polish literature the three-dimensional ultrasonography is positively evaluated in the diagnosis of abnormalities met in the uterine cavity (Stachowicz *et al.* 2002).

In most of existing papers there is not particularly stressed an advantage of the three-dimensional ultrasonography over the SIS 3D ultrasonography however our data show that this new technique is very helpful in diagnosis of uterine cavity.

These both methods of sonohysterography simplify the diagnosis and reduce the number of false positive results. Expanding of uterine walls helps to locate the polyps and allows a precise planning of operative procedure. The operator may decide whether to do a simple polypectomy or to use a resectoscope.

In the last years the use of transvaginal ultrasonography combined with three-dimensional visualization gives measurable advantages in clinical diagnosis. Including to this procedure two- or three-dimensional sonography increases the diagnostic possibilities. Many authors emphasize advantages such as high sensitivity of examination, relatively low invasiveness, no need of anesthesia (Makris & Kalmantis *et al.* 2007; Makris & Skartados *et al.* 2007; Tamanaha *et al.* 2004). Our data show a great usefulness of this method.

After finishing of the examination a three-dimensional picture allows an exact analysis of the image and an accurate diagnosis. The modern software enables post-processing of the picture; the three-dimensional image shows the location and size of the lesion in the uterine cavity which is important to the hysteroscopist. The precision of diagnosis is in close proximity to hysteroscopy.

## CONCLUSIONS

1. In SIS 2D or SIS 3D examination the assessing of endometrium is much easier than in classic TV-USG.
2. Introducing the SIS technique enables a more sensitive and specific assessing of the uterine cavity in cases of polyps and/or submucosal fibromas.
3. The SIS 3D visualization gives new diagnostic possibilities and allows a precise planning of hysteroscopy. Using the SIS 3D optimize the diagnosis and enables the qualification to subsequent procedure.
4. Comparing sensitivity and specificity of SIS 2D and SIS 3D significant differences were not found.
5. The advantage of SIS 3D is the possibility to get additional information by post-processing of the picture.
6. In the classic ultrasonographic diagnosis of uterine cavity lesions an over interpretation was found; there were seen lesions which were not confirmed in hysteroscopy and histopathologic examination. As well the count of normal findings was reduced after hysteroscopic verification.

## REFERENCES

- 1 Bakos O, Heimer G (1998). Transvaginal ultrasonographic evaluation of the endometrium related to the histological findings in pre- and perimenopausal women. *Gynecol Obstet Invest.* **45(3)**: 199–204.
- 2 Bedner R, Rzepka-Górska I (2002). Transvaginal ultrasonography in the diagnosis of endometrial and uterine cavity changes in perimenopausal women. *Gin Pol.* **73(11)**: 985–90.
- 3 Bettocchi S, Nappi L, Ceci O, Selvaggi L (2003). What does 'diagnostic hysteroscopy' mean today? The role of the new techniques. *Curr Opin Obstet Gynecol.* **15(4)**: 303–8.
- 4 Campo S, Campo V, Gambadauro P (2005). Short-term and long term results of resectoscopic myomectomy with and without pretreatment with Gn RH analogs in premenopausal women. *Obstetrical & Gynecological Survey* **60(12)**: 795–796.
- 5 Davidson KG, Dubinsky TJ (2003). Ultrasonographic evaluation of the endometrium in postmenopausal vaginal bleeding. *Radiol Clin North Am.* **41(4)**: 769–80.
- 6 Dueholm M, Forman A, Jensen ML, Laursen H, Kracht P (2001). Transvaginal sonography combined with saline contrast sonohysterography in evaluating the uterine cavity in premenopausal patients with abnormal uterine bleeding. *Ultrasound Obstet Gynecol.* **18(1)**: 54–61
- 7 Epstein E, Ramirez A, Skoog L, Valentin L (2001). Transvaginal sonography, saline contrast sonohysterography and hysteroscopy for the investigation of women with postmenopausal bleeding and endometrium > 5 mm. *Ultrasound Obstet Gynecol.* **18(2)**: 157–62.
- 8 Fakuda M, Shimizu T, Fakuda K, Yomura W, Shimizu S (1993). Transvaginal hysterosonography for differentia diagnosis between submucosal and intramural myoma. *Gynecol Obstet Invest.* **35**: 236–9.
- 9 Goldstein SR, Zelster I, Horan CK, Snyder JR, Schartz LB (1997). Ultrasonography based triage for perimenopausal patients with abnormal uterine bleeding. *Am J Obstet Gynecol.* **177**: 102–8.
- 10 Goldstein SR, Monteagudo A, Popiolek D, Mayberry P, Timor-Tritsch I.(2002) Evaluation of endometrial polyps. *Am J Obstet Gynecol.* **186(4)**: 669–74.
- 11 Kowalczyk D (1999). Ocena przydatności sonohisterografii oraz parametrów przepływu krwi w tętnicach macicznych w diagnostyce nieprawidłowych krwawień macicznych u kobiet w okresie okołomenopauzalnym. Rozprawa doktorska. Śląska Akademia Medyczna Katowice.
- 12 Makris N, Kalmantis K, Skartados N, Papadimitriou A, Mantzaris G, Antsaklis A (2007). Three-dimensional hysterosonography versus hysteroscopy for the detection of intracavitary uterine abnormalities. *Int J Gynaecol Obstet.* **97(1)**: 6–9.
- 13 Makris N, Skartados N, Kalmantis K, Mantzaris G, Papadimitriou A, Antsaklis A (2007). Evaluation of abnormal uterine bleeding by transvaginal 3-D hysterosonography and diagnostic hysteroscopy. *Eur J Gynaecol Oncol.* **28(1)**: 39–42.
- 14 Martín-Ondarza C, Gil-Moreno A, Torres-Cuesta L, García A, Ezzaguirre F, Díaz-Feijoo B *et al.* (2005). Endometrial cancer in polyps: a clinical study of 27 cases. *Eur J Gynaecol Oncol.* **26(1)**: 55–8.
- 15 Nanda S, Chadha N, Sen J, Sangwan K (2002) Transvaginal sonography and saline infusion sonohysterography in the evaluation of abnormal uterine bleeding. *Aust N Z J Obstet Gynaecol.* **42(5)**: 530–4.
- 16 Oriel KA, Schragar S (1999). Abnormal uterine bleeding. *Am Fam Physician.* **60(5)**: 1371–80; discussion 1381–2.
- 17 Parsons AK, Lense JJ (1993). Sonohysterography for endometrial abnormalities preliminary results *J. Clin. Ultrasound* **21**: 87–95.
- 18 Randolph JR, Kang Ying Yu, Maier BD, Schmidt CL, Riddick DH (1986). Comparison of real-time ultrasonography / hysteroscopy in the evaluation of the uterine abnormalities and tubal patency. *Fertility and Sterility* **46**: 828–32.
- 19 Stachowicz N, Czekierdowski A, Daniłoś J, Kotarski J (2002). Three dimensional sonography in the endometrial volume measurement in women with perimenopausal irregular uterine bleeding *Gin Pol.* **73(11)**: 970–5.
- 20 Tamanaha S, Aldrighi JM, Santos RE, Prado RA (2004). Sensitivity and specificity of hysterosonography in endometrial abnormalities in asymptomatic postmenopausal. *Rev Assoc Med Bras* **50(4)**: 427–32.