

Hemichorea associated with nonketotic hyperglycemia in a female

Cheng-guang SONG^{1,3}, Xin YANG², Gui-hong XING², Chuan-sheng ZHAO¹

¹ Department of Neurology, The First Affiliated Hospital of China Medical University, Shenyang, China

² Department of Endocrinology, Benxi Central Hospital of China Medical University, Benxi, China

³ Department of Neurology, Benxi Central Hospital of China Medical University, Benxi, China

Correspondence to: Chuan-sheng Zhao, MD., PhD.
Department of Neurology,
The First Affiliated Hospital of China Medical University,
No. 155 North Nanjing Street, Shenyang 110001, Liaoning, China.
TEL: +86 24-83283026; FAX: +86 24-83282135; E-MAIL: cszhao@mail.cmu.edu.cn

Submitted: 2012-01-14 Accepted: 2012-07-25 Published online: 2012-10-02

Key words: **hemichorea; nonketotic hyperglycemia; diabetes mellitus; magnetic resonance imaging; striatum**

Neuroendocrinol Lett 2012; **33**(5):489–492 PMID: 23090265 NEL330512C03 © 2012 Neuroendocrinology Letters • www.nel.edu

Abstract

A case of a 61-year-old woman with hemichorea associated with nonketotic hyperglycemia is reported. The typical presentation of this disease is nonketotic hyperglycemia, hemichorea, hyper-intense signal on T1-weighted magnetic resonance imaging (MRI) and high-density on computed tomography (CT) in the contralateral striatum. With good glycemic control, the clinical symptoms disappeared.

INTRODUCTION

Hemichorea is a rare extrapyramidal symptom that is usually caused by lesions within the contralateral basal ganglia, especially in the subthalamic nucleus, caudate nucleus and putamen, or in the fibers among them. Hemichorea leads to involuntary, irregular dance-like movements of the limbs and/or face. The most common cause of hemichorea is cerebrovascular disorders and certain systemic diseases such as diabetes can also cause the disease. Nonketotic hyperglycemia mostly occurs in elderly patients with undiagnosed diabetes or those who have had poorly controlled diabetes for many years. Nonketotic hyperglycaemia can lead to a variety of neurological disorders and hemichorea is one of the rare clinical manifestations seen. The typical presentation of this disease forms a triad: nonketotic hyperglycemia, hemichorea, and hyper-intense signal on T1-weighted magnetic resonance imaging (or high-density on CT) within the contralateral striatum. Clinical

symptoms usually disappear gradually after blood glucose levels become well-controlled and the short T1 MRI signal intensity abnormality in the contralateral striatum is also reversible (Oh *et al.* 2002). However, the pathophysiology of hemichorea associated with nonketotic hyperglycemia remains unclear. Here we report a case of hemichorea associated with nonketotic hyperglycemia.

CASE REPORT

A 61-year-old woman came to our Department of Endocrinology with polydipsia, polyphagia, polyuria and weight loss of around 12 kg over 6 months. She had her first episode of hyperglycemia 1 day previously. She also had a 5 month history of involuntary movements in her right arm and face. She went to several hospitals for treatment and had been diagnosed with hemiballismus, was taking oral haloperidol, but was not successfully treated. The patient also had a history of hypertension, no infections, no significant medication history, and no evidence of metabolic abnormalities, neuro-

degenerative diseases or immunologic disorders. On physical examination, she was conscious and alert with normal higher cognitive functions and cranial nerve examination. She had right-sided angulus oris vellicate, involuntary right arm movements including occasional joint flexion, straightening and rotation. Her right arm had normal muscle power but mild hypotonia. Her abnormal movements disappeared during sleep. A fasting blood glucose measurement was obtained as 27.2 mmol/L (489.6 mg/dl); blood and urine analysis did not reveal ketones. A brain CT showed a slight hyperdense lesion in the left putamen (Figure 1). T1-weighted brain MRI showed a hyperintense lesion in the left putamen (Figure 2) with iso-signal intensity on T2-weighted and DWI. Type 2 diabetes mellitus and hemichorea associated with nonketotic hyperglycemia was diagnosed. Her hyperglycemia was later treated with insulin, metformin hydrochloride and acarbose, and after 2 days of treatment her blood sugar was well controlled and the movement disorder severity decreased markedly. The patient's hemichorea had completely disappeared by 3 weeks after our treatment onset.

DISCUSSION

Hemichorea accounts for around 28% of movement disorders (Lin *et al.* 2001). Bedwell (Bedwell 1960) first reported patients with diabetes associated with hemichorea in 1960, and since then there have been similar cases occasionally reported worldwide. The syndrome mainly affects elderly women, often in Asia (Hsu *et al.* 2004), with uncontrolled diabetes (Lin & Chang 1994; Shan *et al.* 1998; Lee & Choi *et al.* 2002) or recent onset of hyperglycemia (Ifergane *et al.* 2001; Romero *et al.*

2002; Rector *et al.* 1982). The average age of onset is 71 years old. Lesions are typically in the contralateral basal ganglia, especially the subthalamic nucleus, caudate nucleus and putamen. At present, the pathophysiology of hemichorea associated with nonketotic hyperglycemia remains unclear. Some researchers have proposed the theory of microangiopathy (Lai *et al.* 1996). Mestre and colleagues (Mestre *et al.* 2007) discovered hemosiderin deposition in brain lesions by pathological examination, suggesting local capillary hemorrhage, which further supports the theory. However, Ohara and colleagues (Ohara *et al.* 2001) found selective loss of neurons, gliosis and reactive astrocytosis in the striatum on autopsy. These findings do not support the theory of hemorrhagic change, and later there have been radiographic results that also do not fully support the notion of cerebrovascular disease as a cause.

Nath and colleagues (Nath *et al.* 2006) found local capillary hemorrhage and punctate calcification on autopsy. Some presumed that the high density regions seen on head CT may be caused by calcium deposits, but in almost all cases, the high density gradually reduced and therefore this does not support the theory of calcium deposition. High blood sugar increases blood viscosity and the permeability of the blood-brain barrier, resulting in local ischemic lesions. Due to oxidative stress, Mn^{2+} passes between axons via voltage-gated Ca^{2+} channels due to the similar physiological characteristics of these ions. Lastly, the formation of Mn-superoxide dismutase (Mn-SOD) deposited in the mitochondria of astrocytes has been noted to stay for a relatively long time (Oh *et al.* 2002; Fujioka *et al.* 1999) and this coincided with the relatively long duration of high signal in T1-weighted MRI.

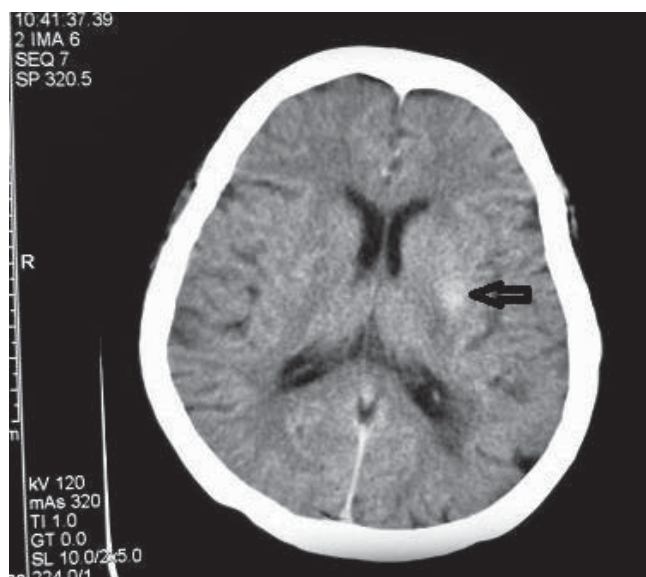


Fig. 1. Brain CT showed a slight hyperdense lesion on the left putamen.

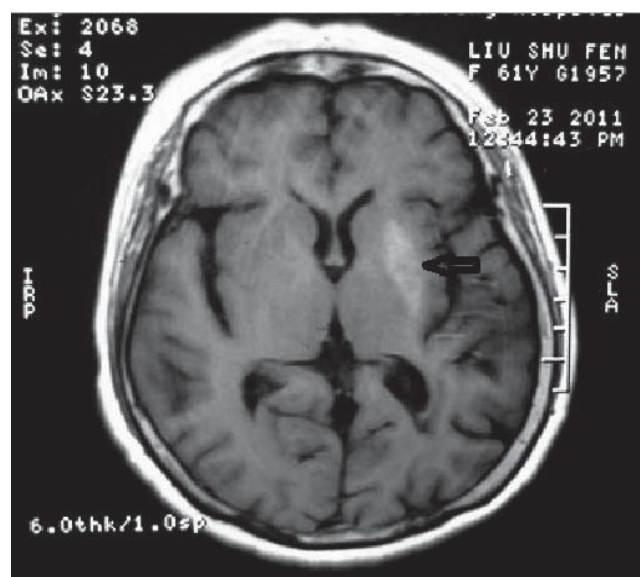


Fig. 2. T1-weighted brain MRI showed a left hyperintense lesion on putamen.

The tricarboxylic acid cycle of patients with non-ketotic hyperglycemia is suppressed and so brain cells use γ -aminobutyric acid (GABA) as the main energy source via anaerobic metabolism. GABA is metabolized to succinic acid through a metabolic pathway with succinic acid semialdehyde, but succinic acid can only provide 10–40% of the energy that the basal ganglia needs. When the GABA becomes exhausted, metabolic acidosis severely influences the normal function of the basal ganglia, leading to hemichorea (Oh *et al.* 2002). In addition, spectral analysis has found that the ratio of N-acetyl aspartate (NAA) to creatine on the lesion side is lower than that of the contralateral side. The lesion ratio of choline to creatine is higher than on the opposite side and lactate levels also increase (Battisti *et al.* 2009). This suggests that dysbolism persists in the basal ganglia and is related to anaerobic metabolism.

Wang and colleagues (Wang *et al.* 2009) analyzed three cases of high blood sugar causing hemichorea and they found that all the patients have early urinary tract or respiratory infections. Cerebrospinal fluid examination with IgG showed that the IgG index and the IgG synthesis rate increased. Chang and colleagues (Chang *et al.* 2007) also reported one case of slightly increased cell count and significantly increased total protein concentration within the CSF, which resembles meningoencephalitis. These factors all suggest that perhaps central nervous system inflammation participates in the occurrence and development of hemichorea. In addition, autoimmune diseases such as rheumatoid arthritis, antiphospholipid antibody syndrome and systemic lupus erythematosus are causes of chorea. This relates to the thought that the basal ganglia are particularly susceptible to the autoimmune antibody attack. Studies have found that glutamic acid decarboxylase (GAD) is a marker of GABAergic neurons in the striatum. Almost all type 1 diabetes patients, and 10% of those with type 2 diabetes, carry an anti-GAD65 antibody (Mihai *et al.* 2008; Walikonis & Lennon 1998). As high blood sugar increases the permeability of the blood-brain barrier, the high concentration of anti-GAD65 antibody in the peripheral blood penetrates the basal ganglia, causing basal ganglia dysfunction and dance-like symptoms.

Other possible mechanisms: Studies have found that estrogen can reduce the function of dopamine in the nigrostriatal system and increase the density of dopamine receptors, thus producing the phenomenon of supersensitivity (Battisti *et al.* 2009). Estrogen decreases after menopause in women and this may be the reason why hemichorea more commonly occurs in older women. From the literature data, high blood sugar-induced hemichorea occurs mainly in the Asian population and is relatively rare in European and American countries, suggesting that there may be racial differences in susceptibility that may be due to variable gene expression (Postuma & Lang 2003).

Hemichorea associated with nonketotic hyperglycemia is a treatable disease. The clinical symptoms will

improve or disappear with blood glucose control. The lowest blood glucose shown to prevent episodes is 6.2–9.0 mmol/L (111.6–162 mg/dl) and hemichorea can relapse with poor blood sugar control (Ohmori *et al.* 2005). For those whose symptoms were mild and had occurred for the first time, only the control of blood glucose was required for a cure; for those whose symptoms were severe, haloperidol may also be required. Clonazepam, diazepam and other sedatives can also help to control involuntary movement in severely affected patients (Ohmori *et al.* 2005).

Hyperglycemia-induced clinical hemichorea is rare but because of its sudden onset, specific neuroimaging patterns and ease of misdiagnosis, a greater understanding of the clinical and radiological features of this disease will help with early diagnosis and treatment.

REFERENCES

- Battisti C, Forte F, Rubenni E, Dotti MT, Bartali A, Gennari P, Federico A, Cerase A (2009). Two cases of hemichorea-hemiballism with nonketotic hyperglycemia: a new point of view. *Neurol Sci.* **30**: 179–183.
- Bedwell SF (1960). Some observations on hemiballisms. *Neurology.* **10**: 619–622.
- Chang CV, Felicio AC, Godeiro Cde O Jr, Matsubara LS, Duarte DR, Ferraz HB, Okoshi MP (2007). Chorea-ballism as a manifestation of decompensated type 2 diabetes mellitus. *Am J Med Sci.* **333**: 175–177.
- Fujioka M, Taoka T, Matsuo Y, Hiramatsu KI, Sakaki T (1999). Novel brain ischemic change on MRI. Delayed ischemic hyperintensity on T1-weighted images and selective neuronal death in the caudoputamen of rats after brief focal ischemia. *Stroke.* **30**: 1043–1046.
- Hsu JL, Wang HC, Hsu WC (2004). Hyperglycemia-induced unilateral basal ganglion lesions with and without hemichorea. A PET study. *J Neurol.* **251**: 1486–1490.
- Ifergane G, Masalha R, Herischanu YO (2001). Transient hemichorea/hemiballismus associated with new onset hyperglycemia. *Can J Neurol.* **28**: 365–368.
- Lai PH, Tien RD, Chang MH, Teng MM, Yang CF, Pan HB, et al (1996). Chorea-ballismus with nonketotic hyperglycemia in primary diabetes mellitus. *AJNR Am J Neuroradiol.* **17**: 1057–1064.
- Lee EJ, Choi JY, Lee SH, Song SY, Lee YS (2002). Hemichorea-hemiballism in primary diabetic patients: MR correlation. *J Comput Tomogr.* **26**: 905–911.
- Lin JJ, Chang MK (1994). Hemiballism-hemichorea and non-ketotic hyperglycaemia. *J Neurol Neurosurg Psychiatry.* **57**: 748–750.
- Lin JJ, Lin GY, Shih C, Shen WC (2001). Presentation of striatal hyperintensity on T1-weighted MRI in patients with hemiballism-hemichorea caused by non-ketotic hyperglycemia: report of seven new cases and a review of literature. *J Neurol.* **248**: 750–755.
- Mestre TA, Ferreira JJ, Pimentel J (2007). Putaminal petechial haemorrhage as the cause of non-ketotic hyperglycaemic chorea: a neuropathological case correlated with MRI findings. *J Neurol Neurosurg Psychiatry.* **78**: 549–550.
- Mihai CM, Catrinou D, Stoicescu RM (2008). Atypical onset of diabetes in a teenage girl: a case report. *Cases J.* **1**: 425.
- Nath J, Jambhekar K, Rao C, Armitano E (2006). Radiological and pathological changes in hemiballism-hemichorea with striatal hyperintensity. *J Magn Reson Imaging.* **23**: 564–568.
- Ohara S, Nakagawa S, Tabata K, Hashimoto T (2001). Hemiballism with hyperglycemia and striatal T1-MRI hyperintensity: an autopsy report. *Mov Disord.* **16**: 521–525.

- 15 Ohmori H, Hirashima K, Ishihara D, Maeda Y, Hirano T, Uyama E, Uchino M (2005). Two cases of hemiballism-hemichorea with T1-weighted MR image hyperintensities. *Intern Med.* **44**: 1280–1285.
- 16 Oh S, Lee K, Im J, Lee MS (2002). Chorea associated with nonketotic hyperglycemia and hyperintensity basal ganglia lesion on T1-weighted brain MRI study: a meta analysis of 53 cases including four present cases. *J Neurol Sci.* **200**: 57–62.
- 17 Postuma RB, Lang AE (2003). Hemiballism: revisiting a classic disorder. *Lancet Neurol.* **2**: 661–668.
- 18 Rector WG Jr, Herlong HF, Moses H 3rd (1982). Nonketotic hyper-glycemia appearing as choreoathetosis or ballism. *Arch InternMed.* **142**: 154–155.
- 19 Romero BM, Monteiro JG, Monteiro E (2002). Hemichorea induced by diabetic ketoacidosis and striatal hyperdensity on computerized axial tomography. *Rev Neurol.* **34**: 256–258.
- 20 Shan DE, Ho DM, Chang C, Pan HC, Teng MM (1998). Hemichorea-hemiballism: an explanation for MR signal changes. *Am J Neuro-radiol.* **19**: 863–870.
- 21 Walikonis JE, Lennon VA (1998). Radioimmunoassay for glutamic acid decarboxylase (GAD65) autoantibodies as a diagnostic aid for stiff-man syndrome and a correlate of susceptibility to type 1 diabetes mellitus. *Mayo Clin Proc.* **73**: 1161–1166.
- 22 Wang JH, Wu T, Deng BQ, Zhang YW, Zhang P, Wang ZK (2009). Hemichorea-hemiballismus associated with nonketotic hyperglycemia: a possible role of inflammation. *J Neurol Sci.* **284**: 198–202.