

# Effect of methylprednisolone on the axonal impairment accompanying cellular brain oedema induced by water intoxication in rats

Petr KOZLER, Jaroslav POKORNÝ

Charles University in Prague, First Faculty of Medicine, Institute of Physiology, Czech Republic

Correspondence to: Prof. Jaroslav Pokorný, MD., DSc.  
Institute of Physiology, First Faculty of Medicine, Charles University in Prague  
Albertov 5, 128 00, Prague 2, Czech Republic.  
TEL: +420 224968416; FAX: +420 224918816; E-MAIL: pokorny@lf1.cuni.cz

Submitted: 2012-08-30 Accepted: 2012-09-12 Published online: 2012-12-28

Key words: axonal impairment; water intoxication; cellular oedema; methylprednisolone; neuroprotection; brain oedema; myelin staining

Neuroendocrinol Lett 2012; 33(8):782-786 PMID: 23391979 NEL331112A09 © 2012 Neuroendocrinology Letters • www.nel.edu

## Abstract

**OBJECTIVES:** Our previous experiments proved that methylprednisolone (MP) can significantly reduce axonal impairment accompanying extracellular oedema induced by the osmotic challenge (load) on the blood-brain barrier (BBB). The aim of the present work was to identify whether MP can affect myelin impairment accompanying intracellular oedema induced by water intoxication.

**METHODS:** For induction of cellular brain oedema, the standard model of water intoxication was chosen. Animals received distilled water in amount corresponding to 15% of the animal's body weight. The volume was divided into three parts and administered intraperitoneally in 8 hours interval.

Axonal changes were recognized as signs of myelin disintegration (oedematous distensions, axonal swelling, vesicles, varicosities) at histological sections stained with Black Gold and classified into four grades of myelin degradation. Hippocampal CA1 and CA3 areas and the dentate gyrus were selected for the study. Methylprednisolone was administered either intraperitoneally or intracarotically. Its effect was studied in two different time intervals: in the acute group (30 minutes after hyperhydration and MP application) and in chronic one (1 week after hyperhydration and MP application).

**RESULTS:** In both the acute and chronic groups, cellular oedema induced by water intoxication brought about apparent damage of myelin (compared to control animals  $p < 0.0001$ ). Intracarotic injection of MP was not able to influence myelin integrity changes either in the acute or in chronic group. However, intraperitoneal administration of MP increased the level of myelin deterioration in the acute group ( $p < 0.05$ ), but improved myelin changes in the chronic group ( $p < 0.005$ ).

**CONCLUSION:** The effect of MP on axonal impairment during cellular brain oedema induced by water intoxication differs from that during the extracellular osmotic oedema. In the extracellular oedema, cellular metabolism is not significantly affected and myelin changes can be influenced by the neuroprotective effect of MP. The primary cause of cellular oedema is a disorder of cellular metabolism and myelin impairment is one of the structural consequences of such disorder. That is why the myelin changes are not affected by MP administration in a consistent and specific manner.

**Abbreviations:**

CNS	- Central Nervous System
BBB	- Blood-brain Barrier
ACC	- Arteria Carotis Communis
ACI	- Arteria Carotis Interna
ACE	- Arteria Carotis Externa
DG	- Dentate Gyrus

**INTRODUCTION**

In our previous work we have shown that effect of methylprednisolone (MP) on axonal damage in an experimental model of cerebral oedema induced by extracellular osmotic insult to blood-brain barrier by mannitol was constant and specific. For a constant effect of MP we considered the fact that the MP in both time intervals (30 minutes and 1 week) and in both modes of administration (intracarotid and intraperitoneal) affected the degree of myelin disintegration. The specific effect of MP means that in both time intervals and in both modes of administration the degree of myelin impairment was reduced (Kozler *et al.* 2011). In the present study the effect of MP on axonal damage was followed in an experimental model of cellular brain oedema induced by water intoxication.

During water intoxication (hyperhydration) an osmotic gradient, is formed which moves water into the intracellular compartment – a cellular oedema is induced (Go 1997; Kimlberg 1995). Animal is hyperhydrated by intraperitoneal injection of distilled water in the total amount of 15% of the body weight. The total dose is divided into three portions, which are applied in eight-hour intervals over 24 hours. This method of induction of cellular oedema does not cause any deterioration of neurological status or an increased mortality, as is the case of acute intoxication, when the total dose is administered all at once. Method is a currently used as a standard experimental model of cellular brain oedema (Olson *et al.* 1994; Vajda *et al.* 2000; Manley *et al.* 2000; Yamaguchi *et al.* 1997).

Neuroprotective effect of MP was tested in experimental models of cerebral oedema with mixed results (Ildan *et al.* 1995; Park 1998; Shapiro *et al.* 1992; Lin *et al.* 1994; Slivka & Murphy 2001). MP has a special position in the management of CNS injuries. While in the treatment of spinal cord injury it is irreplaceable (Bracken *et al.* 1997), the brain injury does not apply to the absence of documented neuroprotective effect (Marshall 2000; Czekajlo & Milbrandt 2005; Edwards *et al.* 2005; Alderson & Roberts 1997).

Methylprednisolone is a synthetic steroid with four times higher glucocorticoid and one fifth of mineralocorticoid action of cortisol (hydrocortisone). The primary neuroprotective effect of MP, mechanisms by which MP affect both healthy and damaged CNS, and pharmacokinetics of MP including its penetration through the BBB has been described in detail in the literature (Hall 1992; Park 1998).

**MATERIAL AND METHODS**

For the experiment, adult animals of both sexes of the Wistar strain of laboratory rats (weight 350–450 g) were used. Animals were treated in accordance with the current Guidelines for the treatment of laboratory animals (EU Guidelines 86/609/EEC).

*Induction of cellular oedema – water intoxication*

Animals were hyperhydrated with the method of water intoxication (Go 1997; Manley *et al.* 2000; Marmarou *et al.* 2006; Yamaguchi *et al.* 1997). Each was given distilled water in a quantity equal to 15% of the body weight in three separate doses applied intraperitoneally at 8-hour intervals during 24 hours prior to launching the experiment.

*Application of methylprednisolone*

To study neuroprotective effect of methylprednisolone two experimental groups were formed: group A (acute) and group C (chronic). In each group three different experiments were performed, each using five animals. Results were compared with the control group (CG) of intact animals. In group A the following experiments were done: A1 – induction of oedema by water intoxication. A2 – induction of oedema by water intoxication accompanied with MP i.p. administration (the total dose of MP 100mg/kg was divided into three sub-doses; each sub-dose was administered together with the dose of distilled water during oedema induction). Perfusion and fixation (see below) were performed 30 minutes after the last water and MP administration. A3 – induction of oedema by water intoxication accompanied with intracarotid MP administration (in a single dose of 100 mg/kg, 10 minutes after BBB opening by mannitol (see below), one hour after the last dose of distilled water). Perfusion and fixation were performed 30 minutes after the MP administration. Experiments in group C followed the arrangement of subgroups in group A, but the perfusion and fixation were performed 1 week after the last water and MP administration. The results were subjected to statistical analysis (see below).

*Microsurgical exposure of the internal carotid (ACI)*

Animals were put into the state of general anaesthesia using intraperitoneal application of thiopental in the dose of 4 mg/100 g and allowed to ventilate spontaneously throughout the procedure. Starting from a skin incision along the midline between the upper end of the sternum and the mandible, the whole common carotid artery (ACC, arteria carotis communis) was exposed with a standard microsurgical technique and, before its bifurcation, also the proximal portions of the internal carotid (ACI, arteria carotis interna) and external carotid (ACE, arteria carotis externa), which was ligated close beyond the bifurcation. An intraluminal catheter was introduced into the ACC trunk from the arteriotomy for selective application of mannitol. With

the application over and the catheter removed, the ACC was ligated distal to and proximal to the arteriotomy. The operation concluded with a single-layer suture (Kozler *et al.* 2011).

#### Osmotic opening of the BBB + MP administration

Mannitol 20% (200 g in 1000 ml of water for injection, 1098 mosmol/l) in a dose of 5 ml/kg was selectively applied in the ACI at a rate of 0.12 ml/sec (Saris *et al.* 1988; Rapoport 2000).

In experiments A3 and C3, 10 minutes after Manitol injection, MP was administered intracarotically in the dose of 100mg/kg. After the surgical intervention, animals were placed in boxes offering standard access to food and drink.

#### Perfusion and fixation

Animals were sacrificed in a deep anaesthesia via standard transcardial perfusion with a 4% solution of paraformaldehyde in 0.1 M phosphate buffer (pH 7.4) for 15 minutes. After removal from the skull, the brain was fixed in the same solution for 24 hours. Serial coronary sections (30 µm thick) were cut at vibratome from each brain, placed on gelatine-coated slides and dried.

#### Neurohistology

The sections were rehydrated and axonal changes detected with the Black Gold II method of staining (Histo-Chem Inc., Jefferson, AZ, USA.) (Schmued *et al.* 1999). The hippocampal formation was the main part of the brain under study because of its known high sensitivity to various pathogenic stimuli. Analysis was centred on the CA1 and CA3 areas of the hippocampus and on the dorsal blade of the dentate gyrus (DG).

The neurohistological picture of the structural integrity of the axons was assessed with the aid of the following

grades of myelin degradation: 1 = no change, 2 = sporadic oedematous vesicles and sporadic oedematous axons, 3 = multiple vesicles, varicosity, oedematous axons and helical course of axons, 4 = myelin fragmentation.

Neurohistological examination was done in both experimental groups (consisting from 3 different experiments) and one control group, with five animals in each group. For the statistical analysis data from 10 sections of each brain were used.

#### Statistical analysis

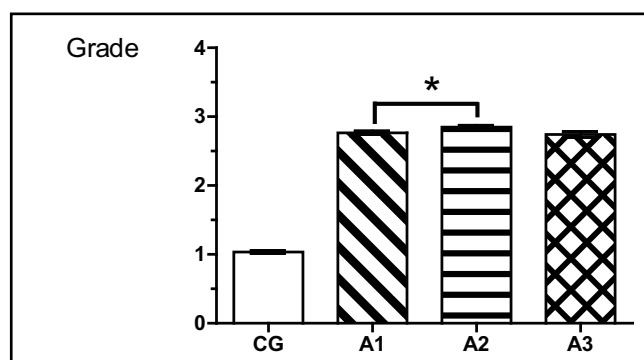
The results were statistically evaluated using the t test and one-way analysis of variance (ANOVA) followed by Dunnett post hoc analysis. The statistical software GraphPad Prism version 4.00 for Windows (GraphPad Software, San Diego, CA, USA) was used for all statistical analyses.

## RESULTS

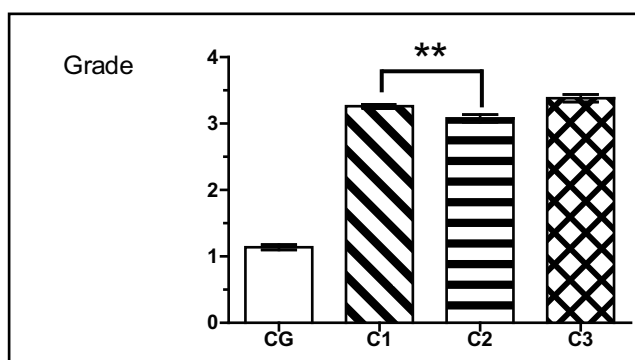
It was shown in the previous paper, that brain oedema is accompanied with signs of myelin degradation. They include oedematous distensions, axonal swelling, vesicles, varicosities, helical course of axons, and myelin fragmentation (Kozler *et al.* 2011).

Results obtained in both experimental groups are shown at Figures 1 (acute group) and 2 (chronic group). In all experimental animals the cellular oedema induced by water intoxication brought about myelin impairment ( $p < 0.0001$ ). Such impairment was more serious in the chronic group (average grade 3.3) than in the acute group (average grade 2.7).

In the acute group, intraperitoneal MP administration worsened the degree of myelin disintegration ( $p < 0.05$ ); however intracarotid MP injection did not affect the process of myelin disintegration (Figure 1).



**Fig. 1.** Degree of myelin changes in acute groups: comparison of control animals (CG) and animals after water intoxication (A1, A2, A3). Significance of differences between groups with water intoxication only (A1) and that with i.p. MP administration is given (A2, A3) ( $p < 0.05$ ); CG: control group; A1 animals after water intoxication (30 minutes); A2 animals after water intoxication accompanied with intraperitoneal MP administration treated with methylprednisolone intraperitoneally; A3 animals after water intoxication accompanied with intracarotid MP administration treated with methylprednisolone intraperitoneally.



**Fig. 2.** Degree of myelin changes in chronic groups (one week after the mannitol administration). Significance of differences between groups with water intoxication only (C1) and that with i.p. MP administration is given (C2) ( $p < 0.05$ ); CG: control group C1 animals after water intoxication (1 week after the water and MP administration); C2 animals after water intoxication treated with methylprednisolone intraperitoneally; C3 animals after water intoxication treated with injection of methylprednisolone into the internal carotid artery

In the chronic group, intraperitoneal MP administration improved the signs of myelin disintegration ( $p < 0.005$ ), but intracarotid MP injection had no effect on the process of myelin disintegration (Figure 2).

## DISCUSSION

Prevention of adverse effects of brain tissue oedema is the aim of many research groups. Promising appear to be substances with antioxidant effect (Gasparova *et al.* 2009). The widely used neuroprotective agent methylprednisolone (MP) reveals also significant antioxidative capacity (Park 1998).

In our previous study, we demonstrated the constant and specific effects of MP at the structural integrity of myelin impaired by extracellular brain oedema induced by osmotic challenges to blood-brain barrier (Kozler *et al.* 2011). The aim of the present study was to evaluate the effect of MP on myelin impairment resulting from cellular oedema induced by water intoxication. Results of the present study showed that cellular oedema can bring myelin disintegration and that these changes are time dependent – the most serious degree of disintegration was found one week after the oedema induction.

Similar experience had also other authors (Creed *et al.* 2011; Onaya 2002; Stys 1998). Our present results also showed that MP injected into the internal carotid artery had no effect on the myelin disintegration induced by cellular oedema both in acute and chronic groups. Intraperitoneal administration of MP however, further impaired the integrity of myelin in the acute group, but improved it in the chronic group ( $p < 0.005$ ) (Figures 1 and 2). The effect of MP can be thus regarded as non-constant, since its effect was inconsistent in both time-defined groups, and after both administration procedures. Effect of MP can be also called non-specific, because it influences myelin disintegration in different ways – intracarotid administration brought no effect hence intraperitoneal administration resulted either in further myelin deterioration or in the integrity improvement.

In the present experiments, effect of MP on myelin impairment induced by cellular oedema was totally different from its constant and specific effects induced by extracellular oedema, which was published earlier (Kozler *et al.* 2011). Variability in the effect of MP can be related to different types and pathogenetic mechanisms of brain oedemas. Osmotic BBB insult leads to extracellular (vasogenic) oedema caused by the increased permeability of BBB, with the cellular metabolism primarily unharmed. Water intoxication induces cellular (cytotoxic) oedema where the primary cause results from damage to cellular metabolism with a relatively preserved selective permeability of BBB (Kimberg 1995). In the primary cause of cellular oedema – in the impairment of the cellular metabolism – we see the cause of unreliability of MP effect on myelin disintegration. Onaya (Onaya 2002) on the basis of neuro-

pathological studies had proved that axonal disintegrity accompanying diffuse brain injuries is always preceded by cellular oedema and he concluded that the occurrence of damaged axons is not possible without cellular oedema. These findings in the context of results from our experimental studies allow concluding that the myelin damage resulting from cellular oedema probably cannot be influenced by MP, or the effect is not constant and specific as it was observed after the extracellular oedema. International clinical studies “CRASH trial” in which randomized patients with brain injury received intravenous infusion of MP had to be prematurely terminated because the outcome of patients who received MP was worse than in those who did not receive MP (Edwards *et al.* 2005; Czekajlo & Milbrandt 2005). Though only speculatively, we must conclude that our experimental results correspond with the clinical study, where the improvement of the clinical status of patients after MP administration was expected.

## CONCLUSION

Results of our experiments show that effects of methylprednisone on the myelin impairment accompanying cellular brain oedema induced by water intoxication are neither consistent nor specific. This finding does not correspond with our previous findings that MP can significantly reduce the degree of myelin damage resulting from extracellular oedema induced by osmotic insult. The explanation for this contradiction lies in the different types of oedema, which lead to myelin damage. The extracellular oedema does not significantly affect the cell metabolism. Resulting changes in the myelin integrity are therefore more easily influenced by the documented neuroprotective effect of MP.

The primary cause of cellular oedema is a disorder in cellular metabolism which results, *inter alia*, in various structural changes, including myelin disintegrity. Because between the cellular oedema and myelin damage a causal relationship was proven, it is very likely that methylprednisone does not affect myelin disorders related to cellular oedema either constantly or specifically.

## ACKNOWLEDGEMENT

This study was supported by grant P-34/LF1/7

## REFERENCE

- 1 Alderson P, Roberts I (1997). Corticosteroids in acute traumatic brain injury: systematic review of randomised controlled trials. *BMJ* **314**: 1855–1859.
- 2 Bracken MB, Shepard MJ, Holford TR, *et al.* (1997). Administration of methylprednisolone for 24 or 48 hours or tirilizad mesylate for 48 hours in the treatment of acute spinal cord injury. *JAMA* **277**: 1597–1604.

- 3 Creed JA, DiLeonardi AM, Fox DP, Tessler AR, Raghupathi R (2011). Concussive brain trauma in the mouse results in acute cognitive deficits and sustained impairment of axonal function. *J Neurotrauma*. **28**:547–63.
- 4 Czekajlo MS, Milbrandt EB (2005). Corticosteroids increased short and long-term mortality in adults with traumatic head injury. *Crit Care*. **8**:9:E21.
- 5 Edwards P, Arango M, Balica L *et al.* (2005). Final results of MRC CRASH, a randomised placebo-controlled trial of intravenous corticosteroid in adults with head injury-outcomes at 6 months. *Lancet*. **365**:1957–1959.
- 6 Gasparova Z, Janega P, Babal P, Snirc V, Stolc S, Mach M, Ujhazy E (2009). Effect of the new pyridoinole antioxidant SMe1EC2 on functional deficits and oedema formation in rat hippocampus exposed to ischaemia in vitro. *Neuroendocrinol Lett*. **30**: 574–581.
- 7 Go KG (1997). The normal and pathological physiology of brain water. *Adv Tech Stand Neurosurg*. **23**:47–142.
- 8 Hall ED (1992). The neuroprotective pharmacology of methylprednisolone. *J. Neurosurg*. **76**: 13–22.
- 9 Ildan F, Polat S, Oner A (1995). The effect of the treatment of high-dose methylprednisolone on Na<sup>+</sup>-K<sup>+</sup>/Mg<sup>2+</sup>-ATPase activity and lipid peroxidation and ultrastructural findings following cerebral contusion in rat. *Surg. Neurol*. **44**: 573–580.
- 10 Kimelberg HK (1995). Current concepts of brain edema. *J Neurosurg*. **83**: 1051–1095.
- 11 Kozler P, Riljak V, Pokorný J (2011) Methylprednisolone reduces axonal impairment in the experimental model of brain oedema. *Neuroendocrinol Lett*. **32**: 101–105.
- 12 Lin SZ, Chiou TL, Chiang YH, Song WS (1994). Combined treatment with nicardipine, phenobarbital, and methylprednisolone ameliorates vasogenic brain edema. *Acta Neurochir*. **60**: 528–530.
- 13 Manley GT, Fujimura M, Ma T (2000): Aquaporin-4 deletion in mice reduces brain edema after acute water intoxication and ischemic stroke. *Nat Med*. **6**: 159–163.
- 14 Marmarou A, Signoretti S, Aygok G, Fatouros P, Portella G (2006): Traumatic brain edema in diffuse and focal injury: cellular or vasogenic? *Acta Neurochir Suppl*. **96**: 24–9.
- 15 Marshall LF (2000). Head injury: recent past, present, and future. *Neurosurgery* **47**: 546–561.
- 16 Olson JE, Evers JA, Banks M (1994). Brain osmolyte content and blood-brain barrier water permeability surface area product in osmotic edema. *Acta Neurochir Suppl*. **60**: 571–573.
- 17 Onaya M (2002). Neuropathological investigation of cerebral white matter lesions caused by closed head injury. *Neuropathology*. **22**: 243–51.
- 18 Park C.O. (1998). The effects of methylprednisolone on prevention of brain edema after experimental moderate diffuse brain injury in rats: comparison between dosage, injection time, and treatment methods. *Yonsei Med. J.* **39**: 395–403.
- 19 Rapoport SI (2000). Osmotic opening of the blood-brain barrier: principles, mechanism, and therapeutic applications. *Cell. Moll. Neurobiol*. **20**: 217–230.
- 20 Saris SC, Wright DC, Oldfield EH, Blasberg RC (1988). Intravascular streaming and variable delivery to brain following carotid artery infusions in the Sprague-Dawley rat. *J Cereb Blood Flow Metab*. **8**: 116–120.
- 21 Shapira Y, Artru AA, Yadid G, Shohami E (1992). Methylprednisolone does not decrease eicosanoid concentrations or edema in brain tissue or improve neurologic outcome after head trauma in rats. *Anesth. Analg*. **75**: 238–244.
- 22 Schmued L, Slikker W (1999). Black-gold; a simple, high-resolution histochemical label for normal and pathological myelin in brain tissue sections, *Brain Research*. **837**: 289–297.
- 23 Slivka PA, Murphy EJ (2001). High-dose methylprednisolone treatment in experimental focal cerebral ischemia. *Exp. Neurol*. **167**: 166–172.
- 24 Stys PK (1998): Anoxic and ischemic injury of myelinated axons in CNS white matter: from mechanistic concepts to therapeutics. *J Cereb Blood Flow Metab*. **18**: 2–25.
- 25 Vajda Z, Promeneur D, Dóczi T *et al.* (2000). Increased aquaporin-4 immunoreactivity in rat brain in response to systemic hyponatremia. *Biochem Biophys Res Commun*. **270**: 495–503.
- 26 Yamaguchi M, Yamada T, Kinoshita I, Wu S, Nagashima T, Tamaki N (1997). Impaired learning of active avoidance in water-intoxicated rats. *Acta Neurochir Suppl*. **70**: 152–4.