

# Amiodarone-induced thyrotoxicosis in a case of Eisenmenger's syndrome

Agata CZARNYWOJTEK<sup>1#</sup>, Kosma WOLIŃSKI<sup>1#</sup>, Ryszard WAŚKO<sup>1</sup>, Ewa FLOREK<sup>2</sup>, Małgorzata ZGORZALEWICZ-STACHOWIAK<sup>3</sup>, Marta FICHNA<sup>1</sup>, Weronika GREBERSKA<sup>4</sup>, Przemysław GUZIK<sup>5</sup>, Martha LODYGA<sup>6</sup>, Barbara KWIECINSKA<sup>7</sup>, Marek RUCHAŁA<sup>1</sup>

<sup>1</sup> Department of Endocrinology, Metabolism and Internal Medicine, Poznan University of Medical Sciences, Poznan, Poland

<sup>2</sup> Laboratory of Environmental Research, Department of Toxicology, Poznan University of Medical Sciences, Poznan, Poland

<sup>3</sup> Laboratory of Medical Electrodiagnostics, Department of Health Prophylaxis, Poznan University of Medical Sciences, Poznan, Poland

<sup>4</sup> Department of Invasive Cardiology, District Hospital, Poznan, Poland

<sup>5</sup> Department of Cardiology – Intensive Therapy and Internal Medicine, Poznan University of Medical Sciences, Poznan, Poland

<sup>6</sup> Medical Sociology Department, Loyola University, Chicago, USA

<sup>7</sup> Medical Student at Poznan University of Medical Sciences, Poznan, Poland

*#These authors contributed equally to this work*

Correspondence to: Agata Czarnywojtek, MD., PhD.  
University of Medical Sciences,  
Department of Endocrinology, Metabolism and Internal Diseases  
49 Przybyszewskiego Street, 60-355 Poznan, Poland.  
TEL: +48 61 8691332; FAX: +48 61 8691682; E-MAIL: agata.rat@wp.pl

Submitted: 2013-01-19 Accepted: 2013-03-11 Published online: 2014-01-15

Key words: **Eisenmenger's syndrome; amiodarone-induced thyrotoxicosis; radioactive iodine therapy; amiodarone; thyroid; hyperthyroidism; atrial fibrillation**

Neuroendocrinol Lett 2013; **34**(8):767-772 PMID: 24522013 NEL340813C01 ©2013 Neuroendocrinology Letters • [www.nel.edu](http://www.nel.edu)

## Abstract

Eisenmenger's syndrome is a condition due to any congenital heart defect with an intracardiac left-to-right communication that leads to pulmonary hypertension with reversed right-to-left blood flow and secondary cyanosis. The main complications of Eisenmenger's syndrome are heart failure and arrhythmias. Amiodarone, the drug of choice for arrhythmia treatment in such patients, can cause a number of complications, including amiodarone induced thyrotoxicosis (AIT). Hereby, we present a 41-year-old patient with Eisenmenger's syndrome who developed AIT and was successfully treated with radioactive iodine therapy. The patient had an accompanying heart failure and had been treated with amiodarone due to chronic atrial fibrillation. Twenty months later he developed an AIT for which was treated with 814 MBq (22 mCi) radioactive iodine. Since 7 weeks later only a slight decline in thyroid hormones was observed, the patient was received a transient treatment with methimazole, which had to be withdrawn soon due to severe leucopenia. Because of the need to maintain amiodarone, a second ablative radioactive iodine dose was administered leading to complete clinical remission. In conclusion, this case demonstrates that even though amiodarone reduces iodine uptake to a very low level, the therapy with radioactive iodine can be still effective if it is given in a repeated dose to patients who require continuation of amiodarone.

**Abbreviations:**

AIT	- amiodarone-induced thyrotoxicosis
AM	- amiodarone
ATD	- anti-thyroid drugs
CBC	- complete blood count
CRP	- C-reactive protein
ES	- Eisenmenger's syndrome
ft3	- free triiodothyronine
ft4	- free tetraiodothyronine
MIBI	- 2-methoxy-isobutyl-isonitrile
oGCS	- oral glucocorticoids
RAI	- radioiodine therapy

**INTRODUCTION**

Amiodarone is an antiarrhythmic drug frequently used in the therapy of supraventricular and ventricular arrhythmias (Reiffel *et al.* 1994). It is a medication of choice in the treatment of a variety of arrhythmias, which seems to be more efficient in comparison to other antiarrhythmic drugs (Reiffel *et al.* 1994). However, amiodarone may cause a variety of adverse reactions, including thyroid dysfunction. In some instances this drug impairs the Wolff-Chaikoff effect by slowing down the thyroid function and thus leads to secondary hypothyroidism (Amiodarone-Induced Hypothyroidism) (Braverman *et al.* 1971). On the contrary, the more commonly observed hyperthyroidism during amiodarone therapy (AIT, Amiodarone-Induced Thyrotoxicosis) is the opposite result of an overactive thyroid due to the Jod-Basedow effect (Zosin *et al.* 2012).

The AIT is a life-threatening condition, which requires additional medical attention and care. It especially concerns elderly patients with left ventricle dysfunction and is accompanied by an increased risk of death (Kaminski *et al.* 2012). Thionamides, glucocorticoids, iopanoic acid, lithium and potassium perchlorate inhibit the iodine uptake by the thyroid gland and, therefore, seem to be the most effective drugs in the treatment of AIT (Bogazzi *et al.* 2003, 2007; Dickstein *et al.* 1997; Wiersinga *et al.* 1997; Trip *et al.* 1994; Davies *et al.* 1992; Reichert *et al.* 1989). The so-called “non-responders” are usually referred for thyroidectomy (Gough *et al.* 2002, 2006; Osman *et al.* 2002; Farwell *et al.* 1995). The use of radioiodine therapy (RAI), which is a standard treatment for hyperthyroidism, arouses much controversy, because the radioiodine uptake is considerably reduced by amiodarone.

In this paper we present a patient with Eisenmenger's Syndrome, who developed AIT and was successfully treated with two courses of the radioiodine.

**CASE REPORT**

A 41-year-old man with a long-term history of Eisenmenger's Syndrome (ES) was admitted to hospital because of a sudden-onset hyperthyroidism. Twenty-

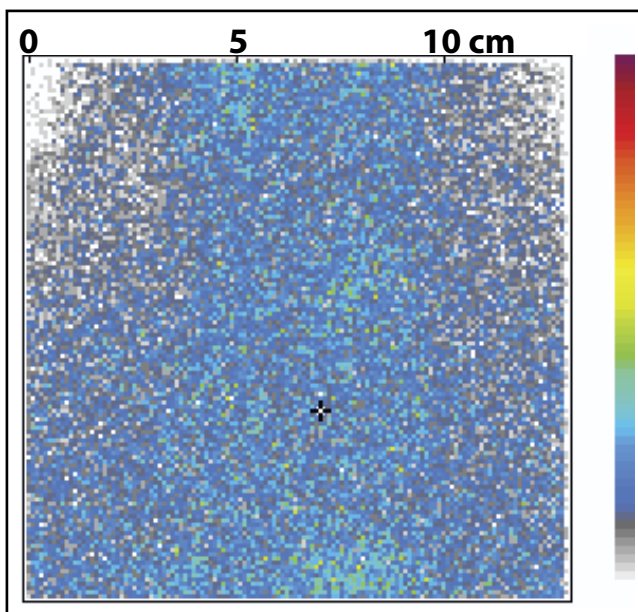
eight years ago, the patient was diagnosed with the cyanotic heart disease, which developed in the course of a co-existing congenital ventricular septal defect and patent ductus arteriosus. The patient presented with an exacerbated heart failure and the atrial fibrillation, for which oral amiodarone (200 mg/d) therapy had been initiated some 20 months earlier.

The patient had never suffered from any thyroid problems in the past. For the last 5 weeks before admission he complained for palpitations, excessive irritability and sweating. Additionally, the patient reported persistent diarrhoea with a progressive weight loss (5 kg during 4 months) despite a very good appetite. Physical examination revealed hypertension (155/70 mmHg) with irregular tachycardia (mean 130 beats/min) and transient, symmetrical, basilar fine crackles over both lungs. Neither nodular thyroid enlargement, bruit over the thyroid gland, nor symptoms of ophthalmopathy were present. Rapid and nervous speech, brisk acceleration of tendon reflexes, muscle atrophy and general weakness were found. The family history was not contributory to the thyroid gland disorders. A psychological evaluation revealed decreased quality of life with high levels of anxiety which had an obvious limiting effect on patient's physical strength and increased sensitivity in social relations, submissiveness, passiveness, mood swings and periodic recurrent depression.

On admission, laboratory findings revealed CBC (Complete Blood Count): haemoglobin – 13.2 g/dL; haematocrit – 38.6%; red blood cells –  $4.3 \times 10^{12}/L$ ; platelets –  $78.9 \times 10^9/L$ , white blood cells –  $3.4 \times 10^9/L$ ; TSH: 0.005 (N: 0.27–4.2  $\mu U/mL$ ), thyroid hormones: free tetraiodothyronine (ft4): 32.4 (N: 11.5–21.5 pmol/L), free triiodothyronine (ft3): 8.9 (N: 3.9–6.8 pmol/L). C-reactive protein was markedly increased (6.0 mg/L; normal values CRP  $\leq 5.0$ ). Results of laboratory tests at baseline and during the follow-up are presented in Table 1.

Electrocardiographic examination revealed: AF with a mean ventricular rate of 130/min; no R wave progression in leads V1-V6; negative T wave in lead I, aVL, V6; and a left bundle branch block. Echocardiography revealed an enlarged right atrial area and pressure. There was an increased right ventricular inflow tract diameter and impaired diastolic and systolic right ventricular function. The systolic function of the left ventricle was highly impaired as well (Table 2).

Thyroid ultrasonography indicated a markedly decreased echogenicity without hypervascularity. The gland volume was 17 ml and there were no nodules. The radioactive iodine uptake was measured at 5 and 24 hours and was reduced to less than 1.2% and 1.9%, respectively. Thyroid scintiscan was performed 30 minutes after an i.v. administration of 150 MBq of  $^{99m}Tc$  (Mediso, Hungary) and it demonstrated a lack of isotope accumulation (Figure 1). Considering the acute clinical symptoms, the results of hormonal evaluations, thyroid ultrasonography and scintigraphic findings, the patient was given ablative (814 MBq = 22 mCi) dose of RAI.



**Fig. 1.** Thyroid  $^{99m}\text{Tc}$  scintigraphy [NuLine gamma camera (Mediso, Hungary)]- lack of isotope accumulation in the thyroid gland.

One week later, thyroid hormones were still elevated: fT4: 53.2 pmol/L and fT3 – 10.4 pmol/L and 7 weeks later, only a slight decline in peripheral hormones was observed (fT4: 49.2 pmol/L, fT3 – 10.1 pmol/L). Therefore, transient treatment with methimazole [Metizol (Polfa-Rzeszów)] was initiated (60 mg/daily). Due to a decrease in leukocyte count (to  $2.6 \times 10^9/\text{L}$ ) observed in the control CBC, methimazole was discontinued after one week. Additionally, oral glucocorticoids (oGCS) were initiated (prednisone 60 mg/d). Twenty-eight weeks after the initial RAI treatment and after the institution of oGCS therapy, serum biochemical tests revealed: fT4, 39.3 pmol/L, fT3, 9.8 pg/mL, and TSH less than  $0.005 \mu\text{U}/\text{mL}$ .

On follow-up electrocardiographic examination presented: AF, heart rate 100 bpm. One more ablative dose of RAI was therefore attempted due to the patient's leucopenia in response to methimazole and the lack of possibility for amiodarone treatment withdrawal.

Shortly afterwards the patient's general status gradually became stable. Twelve weeks later, thyroid hormones were only slightly elevated (fT4: 31.3 pmol/L, fT3 – 8.1 pmol/L). While, fourteen weeks later, the patient presented a complete remission, typical for patients receiving amiodarone (AM) (fT4: 22.3 pmol/L, fT3: 6.7 pmol/L). For the next six months, TSH was still suppressed ( $<0.01 \mu\text{U}/\text{mL}$ ), while free thyroid hormones returned to their reference range. The results of TPO-Abs, Tg-Abs and TSHR-Abs did not change significantly during follow-ups. On electrocardiography, sinus rhythm (92/min.) was observed. Currently, the patient is planned for a heart transplant and still receives oral amiodarone of 200 mg daily.

**Tab. 1.** Laboratory examination results in the analyzed case.

Duration of AIT (weeks)	at baseline	1	8	28	40	54
Clinic		HY			EU*	
Therapy	-	RIT	MMI	oGCS	RIT	-
TSH [N: 0.27–4.2 $\mu\text{U}/\text{mL}$ ]	0.005	0.005	0.005	0.005	0.005	0.005
fT4 [N: 11.5–21.5 pmol/L]	32.4	53.2	49.2	39.3	31.3	22.3
fT3 [N: 3.9–6.8 pmol/L]	8.9	10.4	10.1	9.8	8.1	6.7
TPO-Abs [N: $<34 \text{ IU}/\text{mL}$ ]	31	36	32	31	30	32
Tg-Abs [N: 10–115 IU/mL]	87	123	119	111	102	107
TSHR-Abs [N: $<2 \text{ IU}/\text{L}$ ]	1.2	1.0	0.8	0.9	0.9	0.8
Hs-CRP [N: CRP $\leq 5.0 \text{ mg}/\text{dL}$ ]	6.0	6.3	6.1	6.0	6.4	6.2

Abbreviations: HY, hyperthyroid; EU, euthyroid; RIT, radioiodine therapy; MMI- methimazole; oGCS, oral glucocorticoids

**Tab. 2.** Echocardiographic examination in the present case.

Variables, parameters	Results
RV inlet [mm]	44.1
TAPSE, mm	17.8
Right atrial area, $\text{cm}^2$	18.1
Pulmonary acceleration time, ms	67.2
LV end-diastolic diameter, mm	36.7
LV ejection fraction, %	12
Left atrial area, $\text{cm}^2$	11.5
MV E/e'	6.2

Abbreviations: RV, right ventricular; TAPSE, tricuspid annular plane systolic excursion; LV, left ventricular; MV, mitral valve.

## DISCUSSION

Eisenmenger's syndrome was first described by Victor Eisenmenger in 1897 (Eisenmenger *et al.* 1897). This condition is characterized by the course of pulmonary vascular defects arising due to a chronic and severe intracardiac shunt at the level of the heart and large arteries, usually because of a congenital heart defect. Eisenmenger's syndrome leads to the development of irreversible pulmonary hypertension as a result of the adaptive remodelling of the vascular bed. The complications of Eisenmenger's syndrome comprise heart failure, pulmonary haemorrhage, and cardiac arrhythmias.

This severe cardiac condition often results in tachyarrhythmias, as it was observed in the patient ana-

lyzed in this case study. Due to supraventricular tachycardia (VT), our patient received 200 mg of AM. Since the introduction of this drug, the incidence of AIT has risen from 2% to 12% (Conen *et al.* 2007, Bartalena *et al.* 1996). AIT seems to be a difficult treatment challenge. This is due to the drug's long half-life period, which can even achieve six months (Newman *et al.* 1998). The daily dose of AM contains 7–21 mg of iodide, which equals 50- to 100-fold excess over normal daily requirements in an adult. This possibly contributes to reduced effectiveness of thionamide, which probably results from elevated intrathyroidal iodine levels (Harjai *et al.* 1997). Most of the studies revealed that AIT might occur at any time during AM therapy, even 12 months after its withdrawal (Martino *et al.* 2001). In our case, AIT appeared after 17 months from the initiation of AM therapy. Other difficulties observed during the therapy resulted from the prolonged time of normalization of free T<sub>4</sub> levels.

In everyday practice, it is very difficult to distinguish between the two forms of AIT: type 1 (iodine-induced hyperthyroidism), type 2 (destructive thyroiditis) and mixed. However, Bartalena *et al.* (1996) showed that IL-6 is markedly elevated in Type II AIT and normal to slightly increased in Type I. Recently, thyroid [<sup>99m</sup>Tc] 2-methoxy-isobutyl-isonitrile (MIBI) scintigraphy has been suggested as a useful diagnostic tool to follow patients with AIT (Piga *et al.* 2008). A diffuse MIBI retention, indicative of a hyperfunctioning tissue, was present in all Type I AIT patients, whereas in Type II AIT cases there is no significant uptake, suggesting a destructive process.

AIT exacerbates the mortality risk, especially the in elderly with severe left ventricular dysfunction. However, the severity of the thyrotoxicosis does not affect the mortality in AIT (O'Sullivan *et al.* 2006). High mortality rates in patients with severe left ventricular dysfunction are most likely related to advanced cardiac disease rather than to administration of AM (Zosin *et al.* 2012). In our case, despite many contraindications, recurrent amiodarone therapy was necessary during the period awaiting heart transplantation, as the use of other antiarrhythmic agents appeared totally ineffective.

According to the literature review, AIT is always a difficult challenge (Bartalena *et al.* 1996, Broussolle *et al.* 1989). In AIT treatment, antithyroid drugs (ATDs) seem to be a reasonable and effective therapeutic approach. The majority of authors (Davies *et al.* 1992, Bartalena *et al.* 1996; Bogazzi *et al.* 2009; Broussolle *et al.* 2009) consider ATDs the treatment of choice in AIT patients. Furthermore, steroids alone or adjuvant with ATDs have been employed in AIT at different doses (15–80 mg prednisone or 3–6 mg dexamethasone daily) and at different time schedules (for 7–12 weeks) in Type II AIT (Bartalena *et al.* 1996, Bogazzi *et al.* 2007, Bogazzi *et al.* 2009, Bogazzi *et al.* 2012, Broussolle *et al.* 1989, Simon *et al.* 1984, Wimpfheimer *et al.* 1982). Steroids are beneficial because of the inhibition of 5'-deiodinase

activity and due to their stabilizing and anti-inflammatory effect. Results of the steroid treatment, either alone or in combination with ATDs or plasmapheresis are favourable in most studies of patients with Type II AIT (Broussolle *et al.* 1989; Simon *et al.* 1984; Wimpfheimer *et al.* 1982; Diamond *et al.* 2004, Aghini-Lombardi 1993; Leger *et al.* 1993; Bonnyns *et al.* 1989). Unfortunately, data pertaining to patients with Type I AIT are scant, and the available literature data suggest a limited effectiveness (Bartalena *et al.* 1996). Moreover, thyrotoxicosis may recur once the steroid treatment is discontinued (Simon *et al.* 1984).

Potassium perchlorate can be another treatment option for AIT (Trip *et al.* 1994; Reichert *et al.* 1989; Arias *et al.* 2011; Wolf *et al.* 1998; Martino *et al.* 1986). One serious limitation for the use of potassium perchlorate is its toxicity; leucopenia, agranulocytosis, aplastic anemia, and renal side-effects (Wolf *et al.* 1998; Anonymous 1961). Several authors presented patients with type II AIT who were treated prospectively with Iopanoic acid or its derivatives [sodium ipodate (Oragrafin) or sodium iopanoate (Telepaque)] combined with a thionamide (propylthiouracil or methimazole) (Bogazzi *et al.* 2002, 2003; Chopra *et al.* 2001). Iopanoic acid is an iodinated cholecystographic agent, which inhibits deiodinase activity and reduces the conversion of T<sub>4</sub> to T<sub>3</sub>. On the other hand, good results were obtained by Dickstein *et al.* (1997) using lithium bicarbonate in 9 patients with AIT. According to the others, thyroidectomy under local or general anesthesia is an effective bridge to complete curative treatment of AIT, especially in cases of pharmacotherapeutic resistance (Gough *et al.* 2002; Farwell *et al.* 1990; Tomisti *et al.* 2012; Berti *et al.* 2007; Houghton *et al.* 2004; Williams *et al.* 2002; Claxton *et al.* 2000).

Osman *et al.* (2002) suggested RIT to be ineffective in AIT compared to other forms of thyrotoxicosis therapy. The high iodine content of AM and low radioactive iodine uptake decrease its effectiveness. However, according to Gursoy *et al.* (Gursoy *et al.* 2008) and our previous observations (Czarnywojtek *et al.* 2009), this type of therapy often appears to be the treatment of choice in clinical practice. Hermida *et al.* (Hermida *et al.* 2004) used RAI to prevent the recurrence of AIT in a patient requiring the reintroduction of AM for tachyarrhythmias. In the retrospective cohorts of Type I AIT patients Bogazzi *et al.* (2010) and Albino *et al.* (2009) observed satisfactory results of recombinant human thyrotropin as an adjuvant before RIT.

In the case of our patient, in spite of severely decreased radioactive iodine uptake, we intended to use a combined therapy of RIT and oGCS. Our report demonstrates the key role of RIT in cases of ineffectiveness of alternative treatment methods. This choice of this treatment resulted from our extensive clinical observations based on everyday practice (Czarnywojtek *et al.* 2009). Leucopenia is a major contraindication for ATDs therapy, while thyroidectomy was not recommended

due to the serious clinical condition of our patient. Thus, RIT seemed to be the optimal choice of cure for this specific case, even though it is not the first line treatment method in AIT. Usually, RIT is performed as an additional second choice therapy. In spite of the fact that the first RAI course appeared to be ineffective, we decided to repeat the dose. Unfortunately, the replacement of amiodarone with an alternative antiarrhythmic drug was impossible due to their overall ineffectiveness hence the continuation of AM was necessary.

In conclusion, our case report supports the role of radioiodine treatment in amiodarone-induced thyrotoxicosis. Although RIT is not deemed the first line therapy in AIT, in some rare cases it may prove beneficial and hence should be considered as an alternative approach in patients with contraindication to antithyroid drugs and who cannot be operated because of concomitant disorders.

## REFERENCES

- Aghini-Lombardi F, Mariotti S, Fosella PV, Grasso L, Pinchera A, Braverman LE *et al.* (1993). Treatment of amiodarone iodine-induced thyrotoxicosis with plasmapheresis and methimazole. *J Endocrinol Invest.* **16**: 823–826.
- Albino CC, Paz-Filho G, Graf H (2009). Recombinant human TSH as an adjuvant to radioiodine for the treatment of type 1 amiodarone-induced thyrotoxicosis (AIT). *Clin Endocrinol (Oxf).* **70**: 810–811.
- Anonymus (1961). Potassium perchlorate and aplastic anemia [Editorial]. *Br Med. i*:1520–1521.
- Arias N, Moreno-Pérez Ó, Boix E, Serrano J, Revert P, González VL, *et al.* (2011). Response to adjuvant therapy with potassium perchlorate in amiodarone-induced thyrotoxicosis: observations on three cases. *Endocrinol Nutr.* **58**: 121–126.
- Bartalena L, Brogioni S, Grasso L, Bogazzi F, Burelli A, Martino E (1996). Treatment of amiodarone-induced thyrotoxicosis, a difficult challenge: results of a prospective study. *J Clin Endocrinol Metab.* **81**: 2930–2933.
- Berti P, Materazzi G, Bogazzi F, Ambrosini CE, Martino E, Miccoli P (2007). Combination of minimally invasive thyroid surgery and local anesthesia associated to iopanoic acid for patients with amiodarone-induced thyrotoxicosis and severe cardiac disorders: a pilot study. *Langenbecks' Arch Surg.* **392**: 709–713.
- Bogazzi F, Miccoli P, Berti P, Cosci C, Brogioni S, Aghini-Lombardi F, *et al.* (2002). Preparation with iopanoic acid rapidly controls thyrotoxicosis in patients with amiodarone-induced thyrotoxicosis before thyroidectomy. *Surgery.* **132**: 1114–1117.
- Bogazzi F, Bartalena L, Cosci C, Brogioni S, Dell'Unto E, Grasso L, *et al.* (2003). Treatment of type II amiodarone-induced thyrotoxicosis by either iopanoic acid or glucocorticoids: a prospective, randomized study. *J Clin Endocrinol Metab.* **88**: 1999–2002.
- Bogazzi F, Tomisti L, Bartalena L, Aghini-Lombardi F, Martino E (2012). Amiodarone and the thyroid: a 2012 update. *J Endocrinol Invest.* **35**: 340–348.
- Bogazzi F, Bartalena L, Tomisti L, Rossi G, Tanda ML, Dell'Unto E, *et al.* (2007). Glucocorticoid response in amiodarone-induced thyrotoxicosis resulting from destructive thyroiditis is predicted by thyroid volume and serum free thyroid hormone concentrations. *J Clin Endocrinol Metab.* **92**: 556–562.
- Bogazzi F, Tomisti L, Rossi G, Dell'Unto E, Pepe P, Bartalena L, *et al.* (2009). Glucocorticoids are preferable to thionamides as first line treatment for amiodarone-induced thyrotoxicosis due to destructive thyroiditis: a matched retrospective cohort study. *J Clin Endocrinol Metab.* **94**: 3757–3762.
- Bogazzi F, Tomisti L, Ceccarelli C, Martino E (2010). Recombinant human TSH as an adjuvant to radioiodine for the treatment of type 1 amiodarone-induced thyrotoxicosis: a cautionary note. *Clin Endocrinol (Oxf).* **72**: 133–134.
- Bonnyns M, Sterling I, Renard M, Bernard R, Demaret B, Bourdoux P (1989). Dexamethasone treatment of amiodarone-induced thyrotoxicosis (AIT) with or without persistent administration of the drug. *Acta Cardiol.* **44**: 235–243.
- Braverman LE, Ingbar SH, Vagenakis AG, Adams L, Maloof F (1971). Enhanced susceptibility to iodine myxedema in patients with Hashimoto's disease. *J Clin Endocrinol Metab.* **32**: 515–521.
- Broussolle C, Ducotet X, Martin C, Barbier Y, Bornet H, Noel G, *et al.* (1989). Rapid effectiveness of prednisone and thionamides combined therapy in severe amiodarone iodine-induced thyrotoxicosis. Comparison of two groups of patients with apparently normal thyroid glands. *J Endocrinol Invest.* **12**: 37–42.
- Chopra IJ, Baber K (2001). Use of oral cholecystographic agents in the treatment of amiodarone-induced hyperthyroidism. *J Clin Endocrinol Metab.* **86**: 4707–4710.
- Claxton S, Sinha SN, Donovan S, Greenaway TM, Hoffman L, Loughhead M, *et al.* (2000). Refractory amiodarone associated thyrotoxicosis: an indication for thyroidectomy. *Aust N Z J Surg.* **70**: 174–178.
- Conen D, Melly L, Kaufmann C, Bilz S, Ammann P, Schaefer B, *et al.* (2007). Amiodarone-induced thyrotoxicosis: clinical course and predictors of outcome. *J Am Coll Cardiol.* **49**: 2350–2355.
- Czarnywojtek A, Czepczynski R, Ruchala M, Wasko R, Zgorzalewicz-Stachowiak M, Szczepanek E, *et al.* (2009). Radioiodine therapy in patients with amiodarone-induced thyrotoxicosis (AIT). *Neuro Endocrinol Lett.* **30**: 209–214.
- Davies PH, Franklyn JA, Sheppard MC (1992). Treatment of amiodarone induced thyrotoxicosis with carbimazole alone and continuation of amiodarone. *Br Med J.* **305**: 224–225.
- Diamond TH, Rajagopal R, Ganda K, Manoharan A, Luk A (2004). Plasmapheresis as a potential treatment option for amiodarone induced thyrotoxicosis. *Int Med J.* **34**: 369–370.
- Dickstein G, Shechner C, Adawi F, Kaplan J, Baron E, Ish-Shalom S (1997). Lithium treatment in amiodarone-induced thyrotoxicosis. *Am J Med.* **102**: 454–458.
- Eisenmenger V (1897). Die angeborenen Defekte der Kammer-scheidewände des Herzens. The condition was first mentioned by Hippocrates, the Greek physician. *Zeitschr Klin Med.* **32**: 1–28.
- Farwell AP, Abend SL, Huang SK, Patwardhan NA, Braverman LE (1990). Thyroidectomy for amiodarone-induced thyrotoxicosis. *JAMA.* **263**: 1526–1528.
- Gough IR, Gough J (2002). Surgical management of amiodarone-associated thyrotoxicosis. *Med J Austr.* **176**: 128–129.
- Gough J, Gough IR (2006). Total thyroidectomy for amiodarone-associated thyrotoxicosis in patients with severe cardiac disease. *World J Surg.* **30**: 1957–1961.
- Gursoy A, Tutuncu NB, Gencoglu A, Anil C, Demire AN, Demire NG (2008). Radioactive iodine in the treatment of type 2 amiodarone-induced thyrotoxicosis. *J Natl Med Assoc.* **100**: 706–719.
- Harjai KJ & Licata AA (1997). Effects of amiodarone on thyroid function. *Ann Intern Med.* **126**: 63–67.
- Hermida JS, Jarry G, Tcheng E, Moullart V, Arlot S, Rey JL, Delonca J, *et al.* (2004). Radioiodine ablation of the thyroid to allow the reintroduction of amiodarone treatment in patients with a prior history of amiodarone-induced thyrotoxicosis. *Am J Med.* **116**: 345.
- Houghton SG, Farley DR, Brennan MD, an Heerden JA, Thompson GB, Grant CS (2004). Surgical management of amiodarone-associated thyrotoxicosis: Mayo Clinic experience. *World J Surg.* **28**: 1083–1087.
- Kaminski G, Makowski K, Michałkiewicz D, Kowal J, Ruchala M, Szczepanek E, *et al.* (2012). The influence of subclinical hyperthyroidism on blood pressure, heart rate variability, and prevalence of arrhythmias. *Thyroid.* **22**: 454–460.
- Leger AF, Fragu P, Rougier P, Laurent MF, Tubiana M, Savoie JC (1983). Thyroid iodine content measured by x-ray fluorescence in amiodarone-induced thyrotoxicosis: concise communication. *J Nucl Med.* **24**: 582–585.

- 33 Martino E, Aghini-Lombardi F, Mariotti S, Lenziardi M, Baschieri L, Braverman LE, et al. (1986). Treatment of amiodarone associated thyrotoxicosis by simultaneous administration of potassium perchlorate and methimazole. *J Endocrinol Invest.* **9**: 201–207.
- 34 Martino E, Bartalena L, Bogazzi F, Braverman LE (2001). The effects of amiodarone on the thyroid. *Endocrine Reviews.* **22**: 240–254.
- 35 Newman CM, Price A, Davies DW, Gray TA, Weetman AP (1998). Amiodarone and the thyroid: a practical guide to the management of thyroid dysfunction induced by amiodarone therapy. *Heart.* **79**: 121–127.
- 36 Osman F, Franklyn JA, Sheppard MC, Gammage MD (2002). Successful treatment of amiodarone-induced thyrotoxicosis. *Circulation.* **105**: 1275–1277.
- 37 O'Sullivan AJ, Lewis M, Diamond T (2006). Amiodarone-induced thyrotoxicosis: left ventricular dysfunction is associated with increased mortality. *Eur J Endocrinol.* **154**: 533–536.
- 38 Piga M, Cocco MC, Serra A, Boi F, Loy M, Mariotti S (2008). The usefulness of 99mTc-sestaMIBI thyroid scan in the differential diagnosis and management of amiodarone-induced thyrotoxicosis. *Eur J Endocrinol.* **159**: 423–429.
- 39 Reichert LJ & de Rooy HA (1989). Treatment of amiodarone induced hyperthyroidism with potassium perchlorate and methimazole during amiodarone treatment. *BMJ.* **298**: 1547–1548.
- 40 Reiffel JA, Estes III NA, Waldo AL, Prystowsky EN, DiBianco R (1994). A consensus report on antiarrhythmic drug use. *Clin Cardiol.* **17**: 103–116.
- 41 Simon C, Schlienger JL, Chefran J, Roul G, Vignon F, Chabrier G, et al. (1984). Efficacité de la dexaméthasone dans le traitement de l'hyperthyroïdie à l'amiodarone. *Presse Med.* **13**: 2767–2770.
- 42 Tomisti L, Materazzi G, Baratlena L, Rossi G, Marchello A, Moretti M, et al. (2012). Total thyroidectomy in patients with amiodarone-induced thyrotoxicosis and severe left ventricular systolic dysfunction. *J Clin Endocrinol Metab.* **97**: 3515–3521.
- 43 Trip MD, Düren DR, Wiersinga WM (1994). Two cases of amiodarone-induced thyrotoxicosis successfully treated with a short course of antithyroid drugs while amiodarone was continued. *Br Heart J.* **72**: 266–268.
- 44 Wiersinga WM (1997). Amiodarone and the thyroid. In: Weetman AR, Grossman A. *Pharmacotherapeutics of the thyroid gland.* Springer Verlag, Berlin; pp. 225–87.
- 45 Williams M, Lo Gerfo P (2002). Thyroidectomy using local anesthesia in critically ill patients with amiodarone-induced thyrotoxicosis: A review and description. *Thyroid.* **12**: 523–525.
- 46 Wimpfheimer C, Staubli M, Schadelin J, Studer H (1982). Prednisone in amiodarone-induced thyrotoxicosis. *Br Med J.* **284**: 1835–1836.
- 47 Wolf J (1998). Perchlorate and the thyroid gland. *Pharmacol Rev.* **50**: 89–105.
- 48 Zosin I, Balaş M (2012). Amiodarone-induced thyroid dysfunction in an iodine-replete area: epidemiological and clinical data. *Endokrynol Pol.* **63**: 2–9.